

eISBN: 978-1-68108-415-2  
ISBN: 978-1-68108-416-9

eISSN: 2468-7170  
ISSN: 2468-7162

**OPHTHALMOLOGY**  
**CURRENT AND FUTURE**  
**DEVELOPMENTS** (VOLUME 3)

**DIAGNOSTIC ATLAS OF**  
**RETINAL DISEASES**

**Editors:**

**Mitzzy E. Torres Soriano**  
**Gerardo García Aguirre**  
**Maximiliano Gordon**  
**Veronica Kon Graversen**

**Bentham  Books**

**Ophthalmology:**  
**Current and Future Developments**  
*(Volume 3)*

*(Diagnostic Atlas of Retinal Diseases)*

**Edited by**

**Mitzy E. Torres Soriano**

*Unidad Oftalmológica "Dr. Torres López" Centro Médico  
Cagua, Aragua, Venezuela*

**&**

**Gerardo García Aguirre**

*Asociación para Evitar la Ceguera en Mexico,  
Mexico City, Mexico  
Escuela de Medicina, Tecnológico de Monterrey,  
Mexico City, Mexico*

**Co-Edited by**

**Maximiliano Gordon**

*Centro de la Visión Gordon Manavella, Rosario, Santa Fe, Argentina*

**&**

**Veronica Kon Graversen**

*University of North Carolina at Chapel Hill, Chapel Hill, NC, USA*

## **Ophthalmology: Current and Future Developments**

*Volume # 3*

*Diagnostic Atlas of Retinal Diseases*

Editors: Mitzy E. Torres Soriano, Gerardo García Aguirre, Maximiliano Gordon & Veronica Kon Graversen

eISSN (Online): 2468-7170

ISSN (Print): 2468-7162

eISBN (Online): 978-1-68108-415-2

ISBN (Print): 978-1-68108-416-9

© 2017, Bentham eBooks imprint.

Published by Bentham Science Publishers – Sharjah, UAE. All Rights Reserved.

## **BENTHAM SCIENCE PUBLISHERS LTD.**

### **End User License Agreement (for non-institutional, personal use)**

This is an agreement between you and Bentham Science Publishers Ltd. Please read this License Agreement carefully before using the ebook/echapter/ejournal (“**Work**”). Your use of the Work constitutes your agreement to the terms and conditions set forth in this License Agreement. If you do not agree to these terms and conditions then you should not use the Work.

Bentham Science Publishers agrees to grant you a non-exclusive, non-transferable limited license to use the Work subject to and in accordance with the following terms and conditions. This License Agreement is for non-library, personal use only. For a library / institutional / multi user license in respect of the Work, please contact: [permission@benthamscience.org](mailto:permission@benthamscience.org).

### **Usage Rules:**

1. All rights reserved: The Work is the subject of copyright and Bentham Science Publishers either owns the Work (and the copyright in it) or is licensed to distribute the Work. You shall not copy, reproduce, modify, remove, delete, augment, add to, publish, transmit, sell, resell, create derivative works from, or in any way exploit the Work or make the Work available for others to do any of the same, in any form or by any means, in whole or in part, in each case without the prior written permission of Bentham Science Publishers, unless stated otherwise in this License Agreement.
2. You may download a copy of the Work on one occasion to one personal computer (including tablet, laptop, desktop, or other such devices). You may make one back-up copy of the Work to avoid losing it. The following DRM (Digital Rights Management) policy may also be applicable to the Work at Bentham Science Publishers’ election, acting in its sole discretion:
  - 25 ‘copy’ commands can be executed every 7 days in respect of the Work. The text selected for copying cannot extend to more than a single page. Each time a text ‘copy’ command is executed, irrespective of whether the text selection is made from within one page or from separate pages, it will be considered as a separate / individual ‘copy’ command.
  - 25 pages only from the Work can be printed every 7 days.
3. The unauthorised use or distribution of copyrighted or other proprietary content is illegal and could subject you to liability for substantial money damages. You will be liable for any damage resulting from your misuse of the Work or any violation of this License Agreement, including any infringement by you of copyrights or proprietary rights.

### ***Disclaimer:***

Bentham Science Publishers does not guarantee that the information in the Work is error-free, or warrant that it will meet your requirements or that access to the Work will be uninterrupted or error-free. The Work is provided "as is" without warranty of any kind, either express or implied or statutory, including, without limitation, implied warranties of merchantability and fitness for a particular purpose. The entire risk as to the results and performance of the Work is assumed by you. No responsibility is assumed by Bentham Science Publishers, its staff, editors and/or authors for any injury and/or damage to persons or property as a matter of products liability, negligence or otherwise, or from any use or operation of any methods, products instruction, advertisements or ideas contained in the Work.

### ***Limitation of Liability:***

In no event will Bentham Science Publishers, its staff, editors and/or authors, be liable for any damages, including, without limitation, special, incidental and/or consequential damages and/or damages for lost data and/or profits arising out of (whether directly or indirectly) the use or inability to use the Work. The entire



liability of Bentham Science Publishers shall be limited to the amount actually paid by you for the Work.

### **General:**

1. Any dispute or claim arising out of or in connection with this License Agreement or the Work (including non-contractual disputes or claims) will be governed by and construed in accordance with the laws of the U.A.E. as applied in the Emirate of Dubai. Each party agrees that the courts of the Emirate of Dubai shall have exclusive jurisdiction to settle any dispute or claim arising out of or in connection with this License Agreement or the Work (including non-contractual disputes or claims).
2. Your rights under this License Agreement will automatically terminate without notice and without the need for a court order if at any point you breach any terms of this License Agreement. In no event will any delay or failure by Bentham Science Publishers in enforcing your compliance with this License Agreement constitute a waiver of any of its rights.
3. You acknowledge that you have read this License Agreement, and agree to be bound by its terms and conditions. To the extent that any other terms and conditions presented on any website of Bentham Science Publishers conflict with, or are inconsistent with, the terms and conditions set out in this License Agreement, you acknowledge that the terms and conditions set out in this License Agreement shall prevail.

**Bentham Science Publishers Ltd.**

Executive Suite Y - 2

PO Box 7917, Saif Zone

Sharjah, U.A.E.

Email: [subscriptions@benthamscience.org](mailto:subscriptions@benthamscience.org)



# CONTENTS

<b>PREFACE</b> .....	i
<b>ACKNOWLEDGEMENTS</b> .....	ii
<b>DEDICATION</b> .....	ii
<b>CONFLICT OF INTEREST</b> .....	ii
<b>LIST OF CONTRIBUTORS</b> .....	iii
<b>CHAPTER 1 OCULAR TOXOPLASMOSIS</b> .....	3
<i>José Antonio Unzueta Medina</i>	
<b>ESSENTIALS OF DIAGNOSIS</b> .....	3
<b>DIFFERENTIAL DIAGNOSIS</b> .....	7
<b>MANAGEMENT</b> .....	7
<b>CONFLICT OF INTEREST</b> .....	7
<b>ACKNOWLEDGEMENTS</b> .....	7
<b>REFERENCES</b> .....	7
<b>CHAPTER 2 OCULAR TUBERCULOSIS</b> .....	9
<i>Reinaldo García, Eduardo Torres Porras, J. Fernando Arevalo, Rafael Muci Mendoza, Verónica Oria</i> <i>and Luis Suarez Tata</i>	
<b>ESSENTIALS OF DIAGNOSIS</b> .....	9
<b>DIFFERENTIAL DIAGNOSIS</b> .....	16
<b>MANAGEMENT</b> .....	16
<b>CONFLICT OF INTEREST</b> .....	16
<b>ACKNOWLEDGEMENTS</b> .....	16
<b>REFERENCES</b> .....	17
<b>CHAPTER 3 CYTOMEGALOVIRUS RETINITIS</b> .....	18
<i>Andrée Henaine Berra</i>	
<b>ESSENTIALS OF DIAGNOSIS</b> .....	18
<b>DIFFERENTIAL DIAGNOSIS</b> .....	21
<b>MANAGEMENT</b> .....	22
<b>CONFLICT OF INTEREST</b> .....	23
<b>ACKNOWLEDGEMENTS</b> .....	23
<b>REFERENCES</b> .....	23
<b>CHAPTER 4 NECROTIZING HERPETIC RETINOPATHIES</b> .....	25
<i>Lourdes Arellanes</i>	
<b>ACUTE RETINAL NECROSIS: ESSENTIALS OF DIAGNOSIS</b> .....	27
<b>MANAGEMENT</b> .....	28
<b>PROGRESSIVE OUTER RETINAL NECROSIS: ESSENTIALS OF DIAGNOSIS</b> .....	29
<b>MANAGEMENT</b> .....	29
<b>DIFFERENTIAL DIAGNOSIS</b> .....	30
<b>CONFLICT OF INTEREST</b> .....	30
<b>ACKNOWLEDGEMENTS</b> .....	30
<b>REFERENCES</b> .....	31
<b>CHAPTER 5 OCULAR SYPHILIS</b> .....	33
<i>Claudia Recillas-Gispert</i>	
<b>ESSENTIALS OF DIAGNOSIS</b> .....	33
<b>DIFFERENTIAL DIAGNOSIS</b> .....	41
<b>MANAGEMENT</b> .....	41
<b>CONFLICT OF INTEREST</b> .....	41
<b>ACKNOWLEDGEMENTS</b> .....	41
<b>REFERENCES</b> .....	41

<b>CHAPTER 6 HIV-RELATED RETINAL MICROANGIOPATHY</b> .....	43
<i>Claudia Recillas-Gispert</i>	
ESSENTIALS OF DIAGNOSIS .....	43
DIFFERENTIAL DIAGNOSIS .....	46
MANAGEMENT .....	46
CONFLICT OF INTEREST .....	46
ACKNOWLEDGEMENTS .....	46
REFERENCES .....	46
<b>CHAPTER 7 NEURORETINITIS</b> .....	48
<i>Gerardo García-Aguirre and José Antonio Unzueta Medina</i>	
ESSENTIALS OF DIAGNOSIS .....	48
DIFFERENTIAL DIAGNOSIS .....	51
MANAGEMENT .....	51
CONFLICT OF INTEREST .....	52
ACKNOWLEDGEMENTS .....	52
REFERENCES .....	52
<b>CHAPTER 8 ENDOPHTHALMITIS</b> .....	53
<i>Ezequiel Rosendi, Cecilia Marini and Ricardo Brunzini</i>	
ESSENTIALS OF DIAGNOSIS .....	53
MANAGEMENT .....	74
CONFLICT OF INTEREST .....	77
ACKNOWLEDGEMENTS .....	77
REFERENCES .....	77
<b>CHAPTER 9 ACUTE POSTERIOR MULTIFOCAL PLACOID PIGMENT EPITHELIOPATHY</b> .....	79
<i>Luciana García</i>	
ESSENTIALS OF DIAGNOSIS .....	79
DIFFERENTIAL DIAGNOSIS .....	82
MANAGEMENT .....	83
CONFLICT OF INTEREST .....	83
ACKNOWLEDGEMENTS .....	83
REFERENCES .....	84
<b>CHAPTER 10 MULTIPLE EVANESCENT WHITE DOT SYNDROME</b> .....	85
<i>Ariel Schlaen</i>	
ESSENTIALS OF DIAGNOSIS .....	85
DIFFERENTIAL DIAGNOSIS .....	91
MANAGEMENT .....	91
CONFLICT OF INTEREST .....	91
ACKNOWLEDGEMENTS .....	91
REFERENCES .....	91
<b>CHAPTER 11 MULTIFOCAL CHOROIDITIS</b> .....	94
<i>Amina L. Chaudhry and Debra A. Goldstein</i>	
ESSENTIALS OF DIAGNOSIS .....	94
DIFFERENTIAL DIAGNOSIS .....	98
MANAGEMENT .....	99
CONFLICT OF INTEREST .....	99
ACKNOWLEDGEMENTS .....	99
REFERENCES .....	99
<b>CHAPTER 12 PUNCTATE INNER CHOROIDOPATHY</b> .....	101
<i>Amina L. Chaudhry and Debra A. Goldstein</i>	
ESSENTIALS OF DIAGNOSIS .....	101
DIFFERENTIAL DIAGNOSIS .....	103

MANAGEMENT .....	104
CONFLICT OF INTEREST .....	104
ACKNOWLEDGEMENTS .....	104
REFERENCES .....	104
<b>CHAPTER 13 BIRDSHOT RETINOCHOROIDOPATHY .....</b>	<b>105</b>
<i>Ariel Schlaen</i>	
ESSENTIALS OF DIAGNOSIS .....	105
DIFFERENTIAL DIAGNOSIS .....	111
MANAGEMENT .....	112
CONFLICT OF INTEREST .....	112
ACKNOWLEDGEMENTS .....	113
REFERENCES .....	113
<b>CHAPTER 14 SERPIGINOUS CHOROIDITIS .....</b>	<b>116</b>
<i>Rafael Cortez</i>	
ESSENTIALS OF DIAGNOSIS .....	116
DIFFERENTIAL DIAGNOSIS .....	121
MANAGEMENT .....	121
CONFLICT OF INTEREST .....	121
ACKNOWLEDGEMENTS .....	122
REFERENCES .....	122
<b>CHAPTER 15 DIFFUSE SUBRETINAL FIBROSIS SYNDROME .....</b>	<b>123</b>
<i>Andrée Henaine-Berra</i>	
ESSENTIALS OF DIAGNOSIS .....	123
DIFFERENTIAL DIAGNOSIS .....	126
MANAGEMENT .....	127
CONFLICT OF INTEREST .....	127
ACKNOWLEDGEMENTS .....	127
REFERENCES .....	127
<b>CHAPTER 16 DIFFUSE UNILATERAL SUBACUTE NEURORETINITIS .....</b>	<b>128</b>
<i>Antonio Marcelo B. Casella and Rodrigo F. Berbel</i>	
ESSENTIALS OF DIAGNOSIS .....	128
DIFFERENTIAL DIAGNOSIS .....	131
MANAGEMENT .....	131
CONFLICT OF INTEREST .....	131
ACKNOWLEDGEMENTS .....	131
REFERENCES .....	131
<b>CHAPTER 17 VOGT KOYANAGI HARADA DISEASE .....</b>	<b>133</b>
<i>Lourdes Arellanes</i>	
ESSENTIALS OF DIAGNOSIS .....	133
DIFFERENTIAL DIAGNOSIS .....	137
MANAGEMENT .....	137
CONFLICT OF INTEREST .....	137
ACKNOWLEDGEMENTS .....	138
REFERENCES .....	138
<b>CHAPTER 18 PARS PLANITIS .....</b>	<b>139</b>
<i>Gerardo García-Aguirre and José Antonio Unzueta-Medina</i>	
ESSENTIALS OF DIAGNOSIS .....	139
DIFFERENTIAL DIAGNOSIS .....	142
MANAGEMENT .....	142
CONFLICT OF INTEREST .....	142
ACKNOWLEDGEMENTS .....	142
REFERENCES .....	142

<b>CHAPTER 19 SARCOIDOSIS</b> .....	144
<i>Veronica Kon Graversen</i>	
ESSENTIALS OF DIAGNOSIS .....	144
DIFFERENTIAL DIAGNOSIS (POSTERIOR UVEITIS) .....	146
MANAGEMENT .....	147
CONFLICT OF INTEREST .....	147
ACKNOWLEDGEMENTS .....	147
REFERENCES .....	147
<b>CHAPTER 20 RETINOBLASTOMA</b> .....	149
<i>María Ana Martínez-Castellanos</i>	
ESSENTIALS OF DIAGNOSIS .....	149
DIFFERENTIAL DIAGNOSIS .....	153
MANAGEMENT .....	153
CONFLICT OF INTEREST .....	155
ACKNOWLEDGEMENTS .....	155
REFERENCES .....	155
<b>CHAPTER 21 CAVERNOUS HEMANGIOMA OF THE RETINA</b> .....	157
<i>Gerardo García-Aguirre</i>	
ESSENTIALS OF DIAGNOSIS .....	157
DIFFERENTIAL DIAGNOSIS .....	157
MANAGEMENT .....	159
CONFLICT OF INTEREST .....	159
ACKNOWLEDGEMENTS .....	159
REFERENCES .....	159
<b>CHAPTER 22 VON HIPPEL-LINDAU DISEASE</b> .....	160
<i>Gabriela Lópezcarasa</i>	
ESSENTIALS OF DIAGNOSIS .....	160
DIFFERENTIAL DIAGNOSIS .....	168
MANAGEMENT .....	168
CONFLICT OF INTEREST .....	169
ACKNOWLEDGEMENTS .....	169
REFERENCES .....	169
<b>CHAPTER 23 ASTROCYTOMA TUBEROUS SCLEROSIS</b> .....	172
<i>Noel Millán Moreno</i>	
ESSENTIALS OF DIAGNOSIS .....	172
DIFFERENTIAL DIAGNOSIS .....	174
MANAGEMENT .....	174
CONFLICT OF INTEREST .....	174
ACKNOWLEDGEMENTS .....	174
REFERENCES .....	174
<b>CHAPTER 24 RETINAL VASOPROLIFERATIVE TUMOR</b> .....	176
<i>Gerardo García-Aguirre</i>	
ESSENTIALS OF DIAGNOSIS .....	177
DIFFERENTIAL DIAGNOSIS .....	184
MANAGEMENT .....	184
CONFLICT OF INTEREST .....	187
ACKNOWLEDGEMENTS .....	187
REFERENCES .....	187
<b>CHAPTER 25 MELANOCYTOMA</b> .....	189
<i>Gerardo García-Aguirre and Andrée Henaine-Berra</i>	
ESSENTIALS OF DIAGNOSIS .....	189

DIFFERENTIAL DIAGNOSIS .....	193
MANAGEMENT .....	194
CONFLICT OF INTEREST .....	194
ACKNOWLEDGEMENTS .....	194
REFERENCES .....	194
<b>CHAPTER 26 CONGENITAL HYPERTROPHY OF THE RETINAL PIGMENT EPITHELIUM .....</b>	<b>195</b>
<i>Raul Velez-Montoya and Gerardo Garcia-Aguirre</i>	
ESSENTIALS OF DIAGNOSIS .....	195
DIFFERENTIAL DIAGNOSIS .....	199
MANAGEMENT .....	199
CONFLICT OF INTEREST .....	200
ACKNOWLEDGEMENTS .....	200
REFERENCES .....	200
<b>CHAPTER 27 COMBINED HAMARTOMA OF RETINA AND RETINAL PIGMENT EPITHELIUM .....</b>	<b>202</b>
<i>Maximiliano Gordon</i>	
ESSENTIALS OF DIAGNOSIS .....	202
DIFFERENTIAL DIAGNOSIS .....	204
MANAGEMENT .....	205
CONFLICT OF INTEREST .....	205
ACKNOWLEDGEMENTS .....	205
REFERENCES .....	205
<b>CHAPTER 28 CHOROIDAL NEVI .....</b>	<b>206</b>
<i>Miguel Materin and Maximiliano Gordon</i>	
ESSENTIALS OF DIAGNOSIS .....	206
DIFFERENTIAL DIAGNOSIS .....	210
MANAGEMENT .....	211
CONFLICT OF INTEREST .....	212
ACKNOWLEDGEMENTS .....	212
REFERENCES .....	212
<b>CHAPTER 29 CHOROIDAL MELANOMA .....</b>	<b>213</b>
<i>Daniel Moreno Páramo and Stefanie Reyna Vielma</i>	
ESSENTIALS OF DIAGNOSIS .....	213
DIFFERENTIAL DIAGNOSIS .....	218
MANAGEMENT .....	218
CONFLICT OF INTEREST .....	219
ACKNOWLEDGEMENTS .....	219
REFERENCES .....	219
<b>CHAPTER 30 CHOROIDAL METASTASIS .....</b>	<b>220</b>
<i>Jennifer F. Williamson</i>	
ESSENTIALS OF DIAGNOSIS .....	220
DIFFERENTIAL DIAGNOSIS .....	221
MANAGEMENT .....	222
CONFLICT OF INTEREST .....	222
ACKNOWLEDGEMENTS .....	222
REFERENCES .....	222
<b>CHAPTER 31 LEUKEMIC RETINOPATHY .....</b>	<b>224</b>
<i>Daniel Moreno Páramo, Stefanie Reyna Vielma and Griselda Vázquez Reyes</i>	
ESSENTIALS OF DIAGNOSIS .....	224
DIFFERENTIAL DIAGNOSIS .....	227
MANAGEMENT .....	227
CONFLICT OF INTEREST .....	228



ACKNOWLEDGEMENTS .....	228
REFERENCES .....	228
<b>CHAPTER 32 PRIMARY INTRAOCULAR LYMPHOMA .....</b>	<b>230</b>
<i>Amina L. Chaudhry and Debra A. Goldstein</i>	
ESSENTIALS OF DIAGNOSIS .....	230
DIFFERENTIAL DIAGNOSIS .....	233
MANAGEMENT .....	233
CONFLICT OF INTEREST .....	233
ACKNOWLEDGEMENTS .....	234
REFERENCES .....	234
<b>CHAPTER 33 IDIOPATHIC UVEAL EFFUSION .....</b>	<b>235</b>
<i>Alberto Zambrano</i>	
ESSENTIALS OF DIAGNOSIS .....	235
DIFFERENTIAL DIAGNOSIS .....	238
MANAGEMENT .....	238
CONFLICT OF INTEREST .....	239
ACKNOWLEDGEMENTS .....	239
REFERENCES .....	239
<b>CHAPTER 34 HYPOTONY MACULOPATHY .....</b>	<b>241</b>
<i>Alberto Zambrano</i>	
ESSENTIALS OF DIAGNOSIS .....	241
DIFFERENTIAL DIAGNOSIS .....	243
MANAGEMENT .....	244
CONFLICT OF INTEREST .....	247
ACKNOWLEDGEMENTS .....	247
REFERENCES .....	247
<b>CHAPTER 35 PREGNANCY-ASSOCIATED RETINAL DISEASES .....</b>	<b>249</b>
<i>Naty C. Torres Soriano and Mitzy E. Torres Soriano</i>	
HYPERTENSION: PRE-ECLAMPSIA AND ECLAMPSIA .....	249
DIABETIC RETINOPATHY .....	250
CENTRAL SEROUS CHORIORETINOPATHY .....	250
PRERETINAL OR RETROHYALOID HEMORRHAGES .....	252
UVEAL MELANOMA .....	252
CHANGES IN BLOOD COAGULATION .....	253
OTHER CAUSES FOR BLINDNESS OR SEVERE LOSS OF VISION .....	253
CONFLICT OF INTEREST .....	253
ACKNOWLEDGEMENTS .....	253
REFERENCES .....	253
SUBJECT INDEX .....	255

## **PREFACE**

We are honored to contribute to the information and education of ophthalmology students around the world. We have attempted to distill the current knowledge of medical practice and basic science retina research into a diagnostic atlas of retinal diseases. This is a quick-reference atlas eBook of the retina, edited by specialists in the field, essential to any practicing ophthalmologist or resident who has more than a passing interest in diseases and treatment of the retina.

This e-book includes contributors from Mexico, Venezuela, Argentina, Brazil, United States, Denmark, Spain, Italy, Costa Rica and Peru. It is divided into three volumes: Volume I, retinal vascular diseases, choroidal neovascularization related diseases, vitreomacular interface, and other macular disorders; Volume II, traumatic retinopathies, diseases of vitreous, peripheral degenerations, retinal detachment, pediatric retinal diseases, and retinal dystrophies; and Volume III, posterior uveitis, tumors of the retina, and choroid.

This diagnostic atlas eBook of retinal diseases contains full-color, high quality images of the most frequent retinal pathologies with a brief and comprehensive review of retinal diseases. Each chapter includes essentials of diagnosis, differential diagnosis and treatment. The format is concise, well organized, and didactic, without being exhaustive.

We hope and expect that our atlas of retina will facilitate in providing patients with the best possible care.

### **ACKNOWLEDGEMENTS**

We would like to express our gratitude to Judy Soriano, who provided support with english composition and edition.

To our friends and colleagues without whose contribution would not have been possible to realize this project.

We also want to thank the staff of Bentham Science for their help and support and give us the opportunity to publish this eBook.

### **DEDICATION**

This e-book is specially dedicated to Guillermo Manuel Gordon, MD. He inspired us to always work hard and try our best. He was a friend and a recognized ophthalmologist of Rosario-Argentina, who died on May 2<sup>nd</sup>, 2015.

## **ACKNOWLEDGEMENTS**

We would like to express our gratitude to Judy Soriano, who provided support with english composition and edition.

To our friends and colleagues without whose contribution would not have been possible to real-ize this project.

We also want to thank the staff of Bentham Science for their help and support and give us the opportunity to publish this eBook.

## **DEDICATION**

This e-book is specially dedicated to Guillermo Manuel Gordon, MD. He inspired us to always work hard and try our best. He was a friend and a recognized ophthalmologist of Rosario-Argentina, who died on May 2<sup>nd</sup>, 2015.

## **CONFLICT OF INTEREST**

The authors confirm that they have no conflict of interest to declare for this publication.

## List of Contributors

<b>Alberto Zambrano</b>	Fundación Zambrano, Buenos Aires, Argentina
<b>Amina L. Chaudhry</b>	Northwestern University, Chicago, IL 60208, USA
<b>Andrée Henaine-Berra</b>	Hospital General “Dr. Manuel Gea González”, Mexico City, Mexico
<b>Antonio Marcelo Barbante Casella</b>	Universidad Estatal de Londrina, Rodovia Celso Garcia Cid, Km 380, s/n - Campus Universitario, Londrina - PR, 86057-970, Brazil
<b>Ariel Schlaen</b>	Hospital Universitario Austral, Buenos Aires, Argentina
<b>Cecilia Marini</b>	Cornea and Ocular Surface Department, Hospital de Alta Complejidad El Cruce, Buenos Aires, Argentina
<b>Claudia Recillas-Gispert</b>	Ophthalmology Department, Instituto Nacional de Ciencias Médicas y Nutrición Salvador Zubirán, Mexico City, Mexico
<b>Daniel Moreno Páramo</b>	Ophthalmology Department, Hospital General de Mexico, Mexico City, Mexico
<b>Debra A. Goldstein</b>	Northwestern University, Chicago, IL 60208, USA
<b>Eduardo Torres Porras</b>	Ophthalmology Department, Hospital Cristus Muguerza UPAEP, Puebla, Mexico
<b>Ezequiel Rosendi</b>	Retina and Vitreous Department, Hospital de Alta Complejidad El Cruce, Buenos Aires, Argentina
<b>Gabriela Lópezcarasa</b>	Ophthalmology Department, Hospital Angeles Lomas, Mexico City, Mexico
<b>Gerardo García-Aguirre</b>	Retina Department, Asociación para Evitar la Ceguera en México, and School of Medicine, Instituto Tecnológico y de Estudios Superiores de Monterrey, Mexico City, Mexico Escuela de Medicina, Tecnológico de Monterrey, Mexico City, Mexico
<b>Griselda Vázquez Reyes</b>	Ophthalmology Department, Hospital General de Mexico, Mexico City, Mexico
<b>J. Fernando Arevalo</b>	The Retina Division, Wilmer Eye Institute, Johns Hopkins University School of Medicine, Baltimore, MD, USA The King Khaled Eye Specialist Hospital, Riyadh, Kingdom of, Saudi Arabia
<b>Jennifer F. Williamson</b>	Department of Ophthalmology, University of North Carolina, Chapel Hill, NC, USA
<b>José Antonio Unzueta Medina</b>	Ophthalmology Department, Hospital Angeles Chihuahua, Chihuahua, Mexico
<b>Lourdes Arellanes</b>	Uveitis Department, Asociación para evitar la Ceguera, Hospital Dr. Luis Sánchez Bulnes IAP, Mexico City, Mexico
<b>Luciana García</b>	Centro de la Visión Gordon-Manavella, Rosario, Santa Fe, Argentina Oftalmofunes, Funes, Santa Fe, Argentina
<b>Luis Suarez Tata</b>	Retina & Vitreous Service, Clínica Oftalmológica El Viñedo, Valencia, Venezuela

<b>María Ana Martínez-Castellanos</b>	Retina Service, Asociación para Evitar la Ceguera en México, Hospital Luis Sanchez Bulnes IAP, Mexico City, Mexico
<b>Maximiliano Gordon</b>	Retina Department, Centro de la Visión Gordon- Manavella, Rosario, Argentina Ophthalmology Department, Hospital Provincial del Centenario, Rosario, Argentina
<b>Miguel Materin</b>	Smilow Cancer Hospital at Yale, New Haven, USA Department of Ophthalmology and Visual Science at Yale University, School of Medicine, New Haven, USA
<b>Mitzy E. Torres Soriano</b>	Centro Médico Cagua, Unidad Oftalmológica “Dr. Torres López”, Cagua-Aragua, Venezuela Centro de la Visión Gordon-Manavella, Rosario, Argentina
<b>Naty C. Torres Soriano</b>	Centro Médico Cagua, Unidad Oftalmológica “Dr. Torres López”, Cagua-Aragua, Venezuela Ophthalmology Department, Hospital Central de Maracay, Maracay, Venezuela
<b>Noel Millán Moreno</b>	Instituto de Especialidades Oftalmológicas del Centro (IDEOF), Maracay, Venezuela Centro Oftalmológico Regional Aragua (CORA), Maracay, Venezuela
<b>Rafael Cortez</b>	Centro de Cirugía Oftalmológica (CECOF), Caracas, Venezuela
<b>Rafael Muci Mendoza</b>	The Neurophthalmology unit “Dr. Rafael Muci Mendoza”, Hospital J. M. Vargas, Caracas, Venezuela
<b>Raul Velez-Montoya</b>	Retina Department, Asociación para Evitar la Ceguera en México, AIP, México City, México
<b>Reinaldo García</b>	Retina & Vitreous Service, Clínica Oftalmológica El Viñedo, Valencia, Venezuela
<b>Ricardo Brunzini</b>	Consultorio Brunzini, Buenos Aires, Argentina
<b>Rodrigo Fabri Berbel</b>	Universidad Estatal de Londrina, Rodovia Celso Garcia Cid, Km 380, s/n - Campus Universitario, Londrina - PR, 86057-970, Brazil
<b>Stefanie Reyna Vielma</b>	Ophthalmology Department, Hospital General de Mexico, Mexico City, Mexico
<b>Veronica Kon Graversen</b>	Ophthalmology Department, University of North Carolina at Chapel Hill, NC, USA
<b>Verónica Oria</b>	Retina & Vitreous Service, Clínica Oftalmológica El Viñedo, Valencia, Venezuela

## Ocular Toxoplasmosis

**José Antonio Unzueta Medina\***

*Ophthalmology Department, Hospital Angeles Chihuahua, Chihuahua, Mexico*

Ocular toxoplasmosis is caused by the protozoan parasite *Toxoplasma gondii*. Infections may be acquired congenitally or through the ingestion of infected raw meat, contaminated vegetables or water. A significant proportion of the world population (approximately the third) is infected by *T. gondii* which is responsible for the majority of infectious uveitis cases, which in some countries might be up to 50%. It is the main cause of infectious posterior in immunocompetent individuals, and the second most common in patients with HIV/AIDS [1 - 3].

### ESSENTIALS OF DIAGNOSIS

Clinical presentation in immunocompetent individuals varies according to the age of the patient and the size, location and severity of the retinochoroidal lesions. Symptoms usually include floaters and decreased visual acuity, which may be secondary to vitreous inflammation or to macular involvement. In immunocompromised patients, the presentation may vary [4].

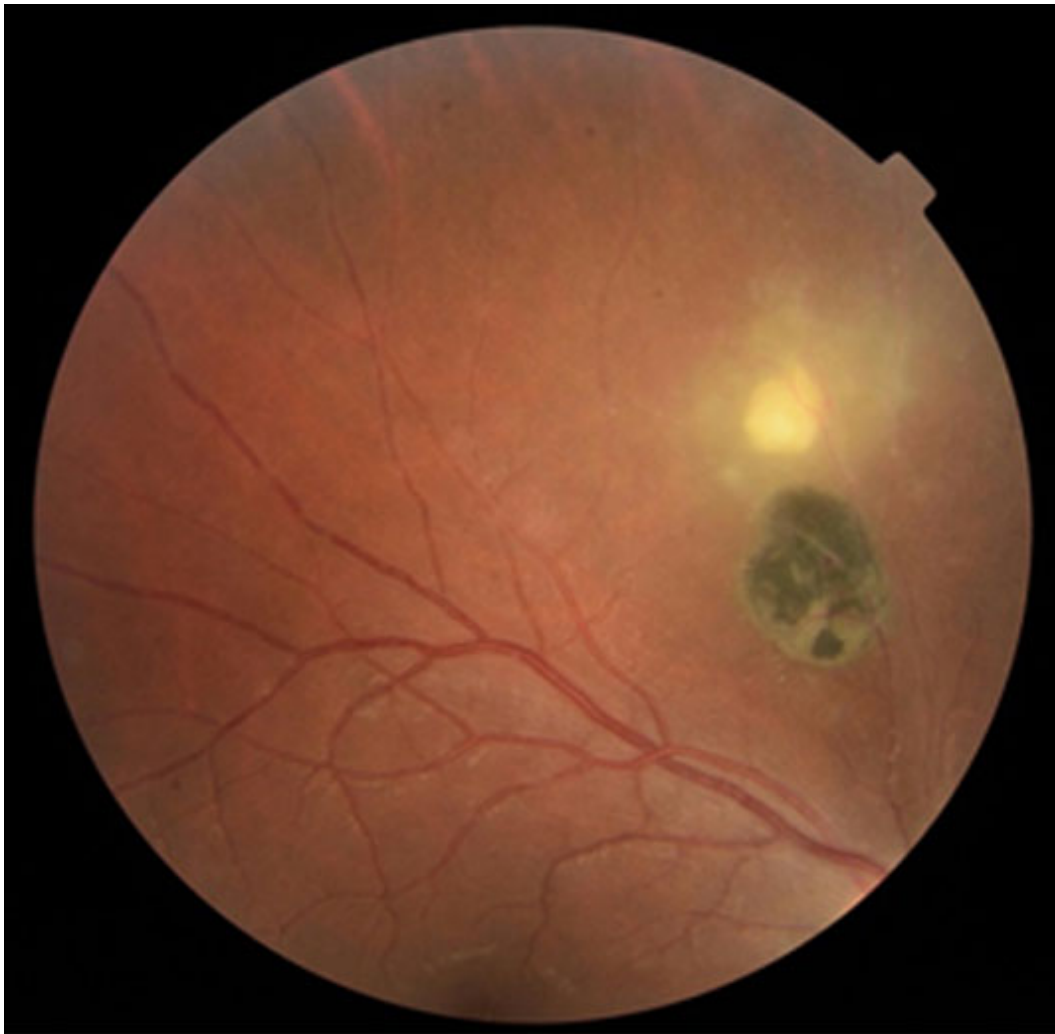The disease may result from congenitally acquired toxoplasmosis or newly acquired infection. Toxoplasmosis usually affects a single eye, causing one or more lesions. Sometimes, lesions in different stages may be observed in the same eye (Fig. 1) [4 - 6].

Typical active lesions appear as yellowish or whitish areas of retinal inflammation (Fig. 2), with adjacent choroiditis, vasculitis, papillitis (Fig. 3), hemorrhage and vitritis. The primary infection occurs in the retina, but other structures such as the choroid, vitreous or anterior chamber may be involved. After the active phase, there is atrophy of the retina and the choroid that leaves a well-circumscribed round punched-out scar (Fig. 4). There is pigment clumping and chorioretinal atrophy that allows the visualization of underlying sclera.

---

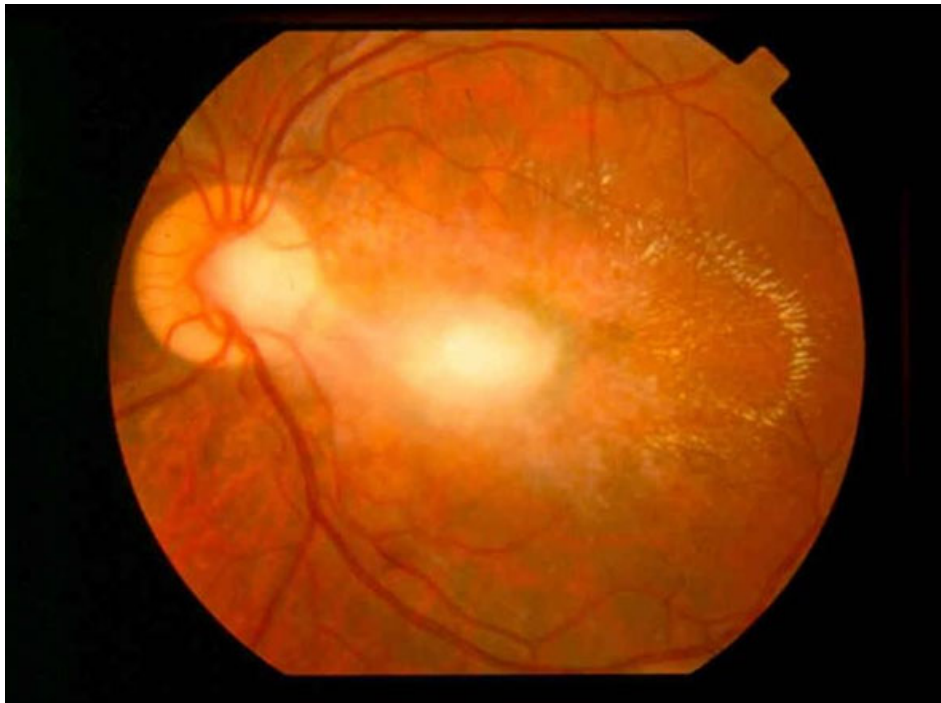
\* **Corresponding author José Antonio Unzueta Medina:** Hospital Angeles Chihuahua, Cons. 104, Hda. del Valle 7120 Las Haciendas Chihuahua, Chih, Mexico; Tel: (614) 439-2804 / 439-2808; E-mail: pepetony16@hotmail.com



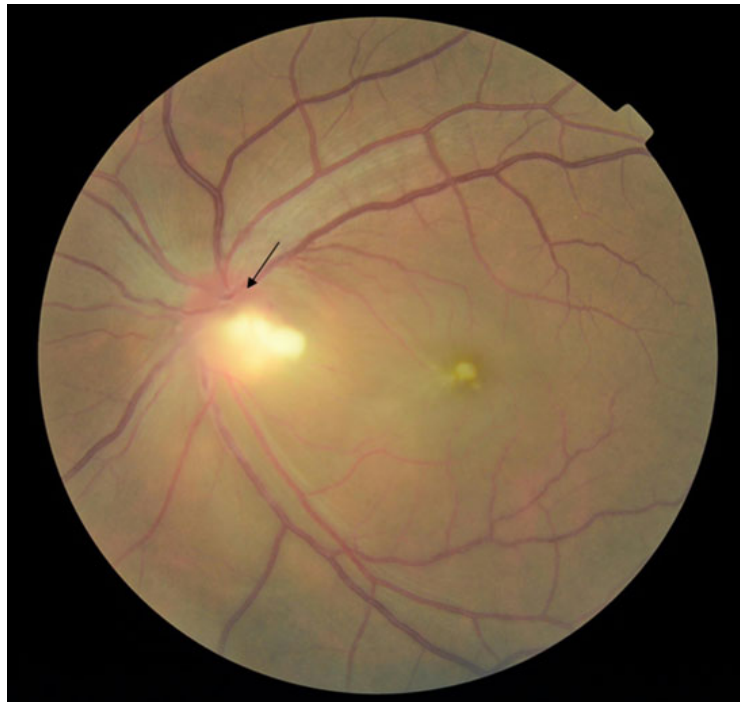

**Fig. (1).** The acute lesion is seen often contiguous to an old pigmented scar (Image courtesy of Naty C. Torres Soriano MD, Venezuela).

Toxoplasmosis may present atypically, causing punctate outer retinal toxoplasmosis, retinal vasculitis, retinal vascular occlusions, rhegmatogenous or serous retinal detachments, unilateral pigmentary retinopathy, neuroretinitis and additional forms of optic neuropathy, peripheral retinal necrosis and scleritis. Ocular complications, seen more frequently in children, include choroidal neovascularization, cataract, glaucoma, optic nerve atrophy and retinal detachment [4 - 6].



**Fig. (2).** Acute toxoplasmosis presents grayish inflammatory infiltrate within retinal and subretinal tissue.



**Fig. (3).** The arrow allows observation of optic disc inflammation (Courtesy of Mitzy E. Torres Soriano, MD).

## Ocular Tuberculosis

**Reinaldo García<sup>1,\*</sup>, Eduardo Torres Porras<sup>2</sup>, J. Fernando Arevalo<sup>3,4</sup>, Rafael Muci Mendoza<sup>5</sup>, Verónica Oria<sup>1</sup> and Luis Suarez Tata<sup>1</sup>**

<sup>1</sup> Retina & Vitreous Service, Clínica Oftalmológica El Viñedo, Valencia, Venezuela

<sup>2</sup> Ophthalmology Department, Hospital Cristus Muguerza UPAEP, Puebla, Mexico

<sup>3</sup> The Retina Division, Wilmer Eye Institute, Johns Hopkins University School of Medicine, Baltimore, MD, USA

<sup>4</sup> The King Khaled Eye Specialist Hospital, Riyadh, Kingdom of Saudi Arabia

<sup>5</sup> The Neurophthalmology unit "Dr. Rafael Muci Mendoza", Hospital J. M. Vargas, Caracas, Venezuela

Tuberculosis (TB) is a clinical disease caused by infection with *Mycobacterium tuberculosis* and is characterized pathologically by granuloma formation [1]. TB may affect the eye by direct invasion of the tubercle bacillus following hematogenous dissemination, or *via* a hypersensitivity reaction to the bacillus located elsewhere in the body [2].

Ocular TB is not common; since the 1980's, it is considered as an etiology of uveitis from 0-4%.

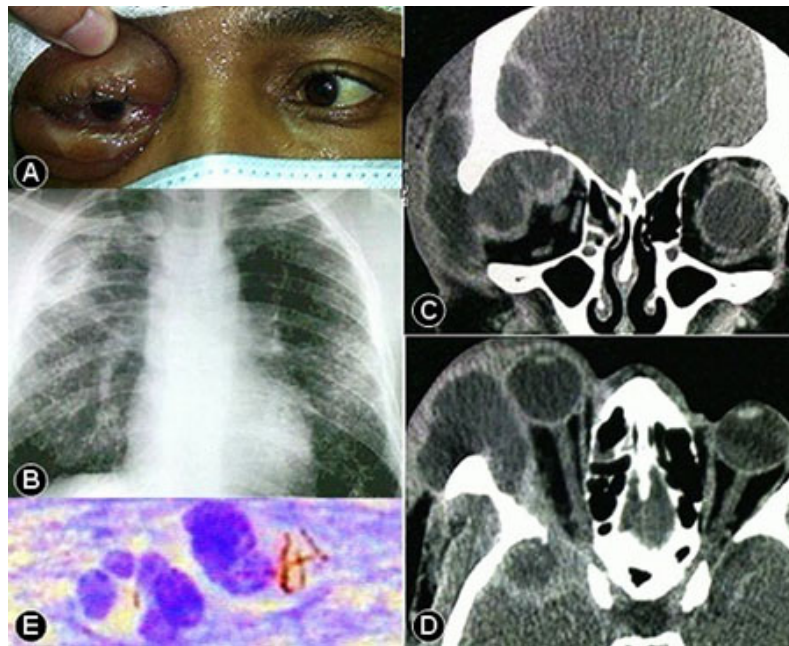
Ocular TB may not be associated with clinical evidence of pulmonary TB; up to 60% of patients with extrapulmonary TB may not have been diagnosed with pulmonary TB [3, 4].

### ESSENTIALS OF DIAGNOSIS

Extraocular TB can appear on the external eye as a lid abscess or manifest as chronic blepharitis or atypical chalazia. It can present as a mucopurulent conjunctivitis with regional lymphadenopathy. It can also present as a phlyctenule (an inflammatory nodule at the junction of the cornea and sclera), infectious keratitis, interstitial keratitis, or as an infectious scleritis. Rarely, the orbital disease can also occur [4] (Fig. 1). All of these presentations are rare and are easy to diagnose as material can be obtained for culture and biopsy [2 - 7].

---

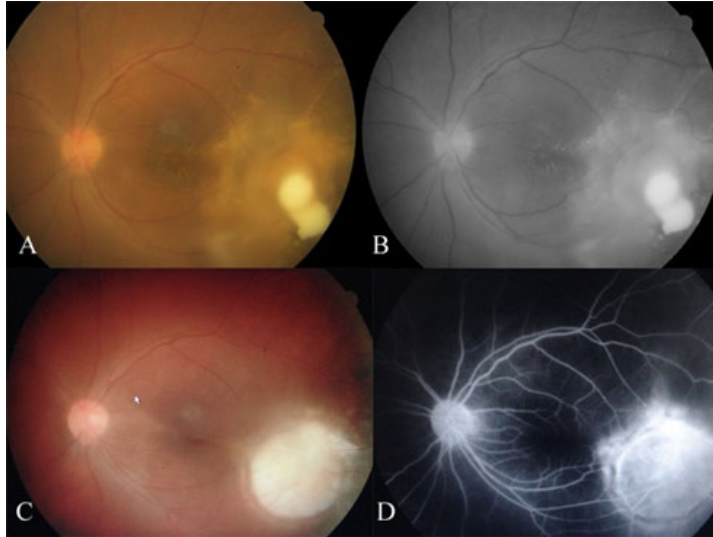
\* Corresponding author Reinaldo García: Clínica Oftalmológica El Viñedo, Valencia, Venezuela; Tel/Fax: 3185234051; 58-212-9774708; E-mail: reinaldogarcia2003@yahoo.com



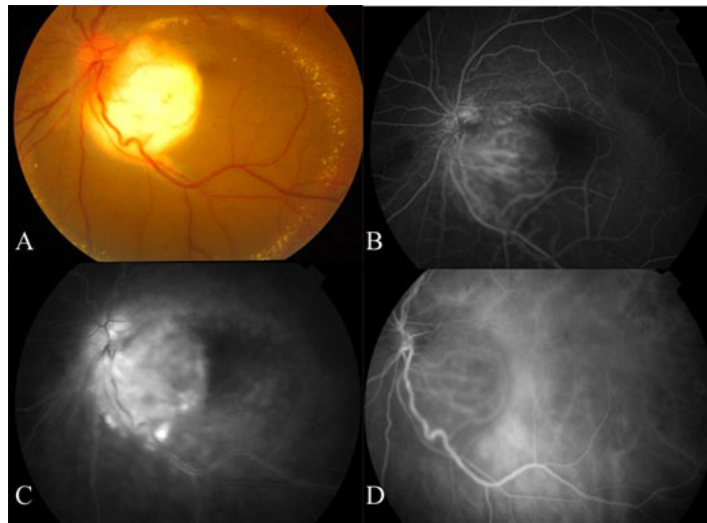
**Fig. (1).** (García *et al.*). **A)** Right orbital syndrome “frozen orbit” with proptosis and mucopurulent conjunctivitis by direct invasion of the tubercle bacillus following haematogenous dissemination. **B)** Miliary tuberculosis is uncommon but carries a poor prognosis. It represents haematogeneous dissemination of an uncontrolled tuberculous infection. Miliary deposits appear as 1-3 mm diameter nodules, which are uniform in size and uniformly distributed. **C-D)** Computed tomographic scan of the head, showing a lesion in the superolateral part of the right orbit with extension into the orbital fissure and soft tissues without bony erosion. **E)** Histopathology showing chronic granulomatous inflammation with giant cells and caseation necrosis. (H&E).

Intraocular TB often involves delicate structures that are difficult or impossible to biopsy or culture. It may present as unilateral or bilateral granulomatous iritis or iridocyclitis with mutton-fat keratic precipitates and/or granulomatous nodules of the iris (Koeppe or Busacca nodules). Broad-based posterior synechiae and hypopyon may be observed. Intermediate uveitis can also occur. More commonly, intraocular TB presents with involvement of the posterior part of the eye. Vitritis, retinitis and/or choroiditis, and retinal vasculitis would be the presenting clinical scenario. Choroidal lesions including granulomas are probably the most common findings in confirmed cases of ocular TB and can be an early sign of disseminated disease [3, 4]. Choroidal tubercles are solitary, or few in number, yellowish lesions typically elevated centrally with poorly defined borders, and commonly situated in posterior pole (Figs. 2 and 8). Inflammatory cells and subretinal fluid may be present (Fig. 3). Tubercles can be solitary or miliary. Multifocal lesions predominantly present in choroid are also common (Figs. 4 and 5) and sometimes can simulate “Serpiginous-like choroiditis” with two distinct patterns (Fig. 6): one with multifocal discrete choroidal lesions that are initially noncontiguous and later

progress to form diffuse lesions with an active edge resembling serpiginous choroiditis, and a solitary, diffuse plaque-like lesion with an amoeboid extension [7]. The retina involvement alone is rare.



**Fig. (2).** (Garcia *et al.*). Choroidal tuberculoma. **A-B)** Left eye color (**A**) and red free (**B**) fundus photograph showing a yellowish-white choroidal mass elevated centrally with poorly defined borders and commonly situated in posterior pole. Inflammatory cells (vitritis), subretinal fluid and a macular star are present. **C)** Same lesion one month after treatment showing no inflammatory cells, consolidation, and no subretinal fluid. **D)** Fluorescein angiogram reveals late homogeneous hyperfluorescence with well-defined borders.



**Fig. (3).** (Garcia *et al.*). Choroidal tuberculoma. **A)** Left eye fundus photograph showing a yellowish-white peripapillary choroidal mass with exudative retinal detachment. **B-C)** Fluorescein angiogram (FA) reveals early mottled hyperfluorescence and late moderate hyperfluorescence. **D)** Indocyanine green angiography (ICG-V) shows hypofluorescence in the late phase. (Courtesy of J. Fernando Arevalo and Sulaiman Al-Sulaiman).

## **Cytomegalovirus Retinitis**

**Andrée Henaine Berra\***

*Hospital General “Dr. Manuel Gea González”, Mexico City, Mexico*

Cytomegalovirus (CMV) is a double-stranded DNA virus, member of the herpesvirus family, which can be acquired through placental transfer, breast feeding, sexual contact, blood transfusions and organ or bone marrow transplants [1]. It is estimated that at least 50% of the world population is seropositive to the virus, occurring at a higher rate in lower socioeconomic groups, developing countries, and homosexual men [1, 2]. However, CMV infection mainly manifests in immunocompromised patients, including those with AIDS, inherited immunodeficiency states, malignancies, and patients under systemic immunosuppressive chemotherapy after transplantation, constituting a major cause of morbidity and mortality in this population. Clinical manifestations may include retinitis, hepatitis, colitis, pneumonitis and encephalitis. In patients with AIDS, CMV retinitis usually occurs when the CD4 T-cell count is below 50 cells/mm<sup>3</sup> [2, 3]. Although the incidence of the infection has dramatically decreased since the use of HAART (highly active antiretroviral therapy), it remains the most common opportunistic ocular infection in this group of patients. There are rare cases of CMV retinitis reported in immunocompetent patients [4].

### **ESSENTIALS OF DIAGNOSIS**

The symptoms are related to the localization of the retinal lesions; small lesions in the periphery can be asymptomatic. At presentation, the most common symptoms are decreased visual acuity, floaters, photopsias, ocular pain and scotomas [1]. The anterior segment manifestations are usually mild, with fine keratic precipitates and anterior chamber cells. Vitreous cells can be present. Papillitis is rare, but may also occur [1, 2].

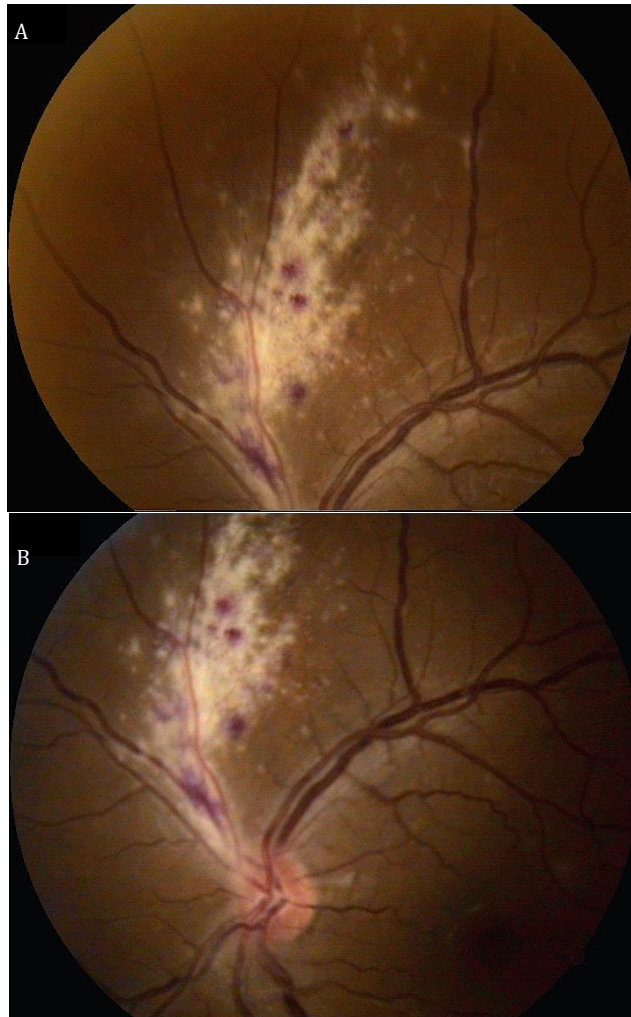CMV retinal lesions can be unilateral or bilateral. The retinitis is characterized by granular whitening areas with irregular borders due to retinal necrosis and edema,

---

\* **Corresponding author Andrée Henaine Berra:** Hospital General “Dr. Manuel Gea González”, Mexico City, Mexico; Tel/Fax: +52(55)96886525; E-mail: andreehenaine@gmail.com

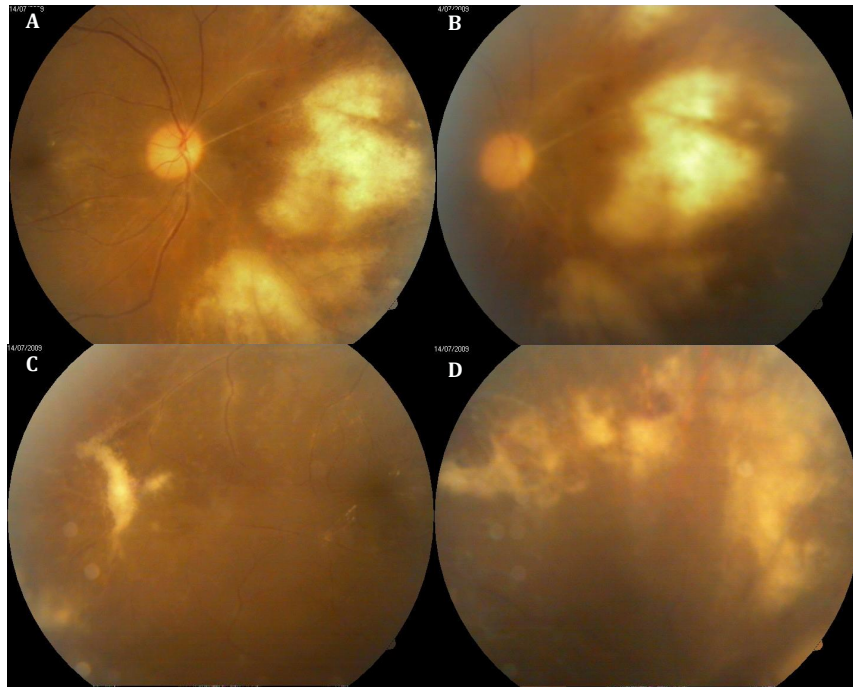


usually accompanied by hemorrhages. Small satellite lesions are characteristic [2]. Vascular sheathing with appearance of “frosted branch” can also be observed [1, 5] (Figs. 1-4).

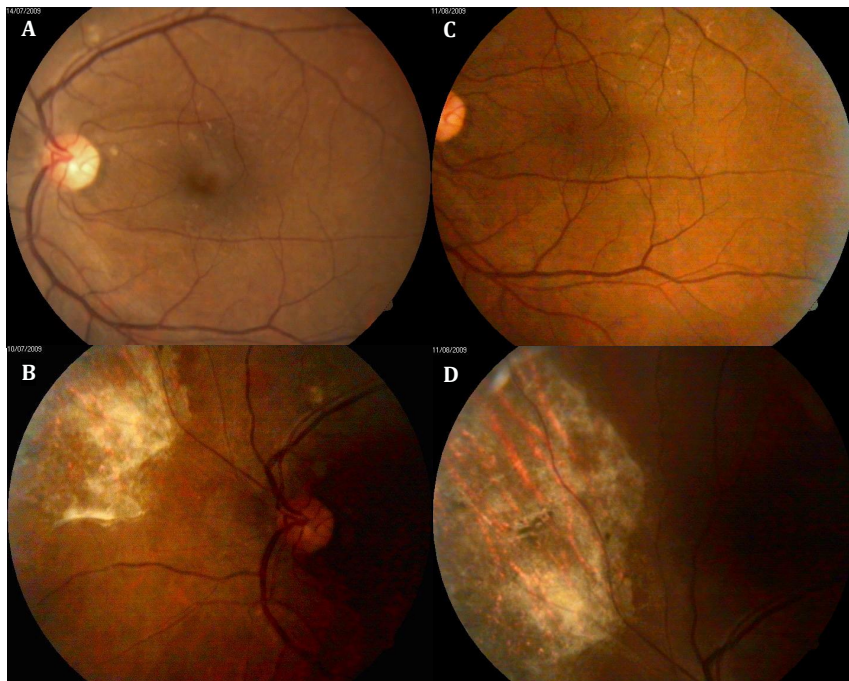


**Fig. (1).** Fundus photographs of the left eye of a 25-year-old male patient with AIDS and active CMV retinitis. Images (A) and (B) show involvement of the superonasal arcade with the presence of retinal whitening and hemorrhages.

The localization of the lesions is divided into three zones: zone 1 -- the area within one disc diameter (1500  $\mu\text{m}$ ) of the optic disc margin or two disc diameters (3000  $\mu\text{m}$ ) of the fovea; zone 2 -- extends from zone 1 to the equator; zone 3 -- the remaining retina to the ora serrata [1, 2, 6]. Progression was defined as an extension of the lesion border of 750  $\mu\text{m}$  or the appearance of a new lesion, at least  $\frac{1}{4}$  of the disc area in size, separated from the previous lesion by 750  $\mu\text{m}$  [1].



**Fig. (2).** Acute CMV retinitis OD, with retinal whitening, hemorrhages and perivascular sheathing in a 35-year-old male patient with AIDS. Fundus photographs show plaques of CMV retinitis involving nasal (A) and (B) temporal (C) and superior (D) areas.



**Fig. (3).** The same patient of Fig. (2), showing improvement one month after treatment with valganciclovir.

## Necrotizing Herpetic Retinopathies

**Lourdes Arellanes\***

*Uveitis Department, Asociación para evitar la Ceguera, Hospital Dr. Luis Sánchez Bulnes IAP, Mexico City, Mexico*

‘Necrotizing herpetic retinopathies’ (NHR) is a term recently proposed because of the wide variety of clinical manifestations of herpetic retinal infections. The severity, location and progression are determined by patient’s immune status and virus-related factors [1].

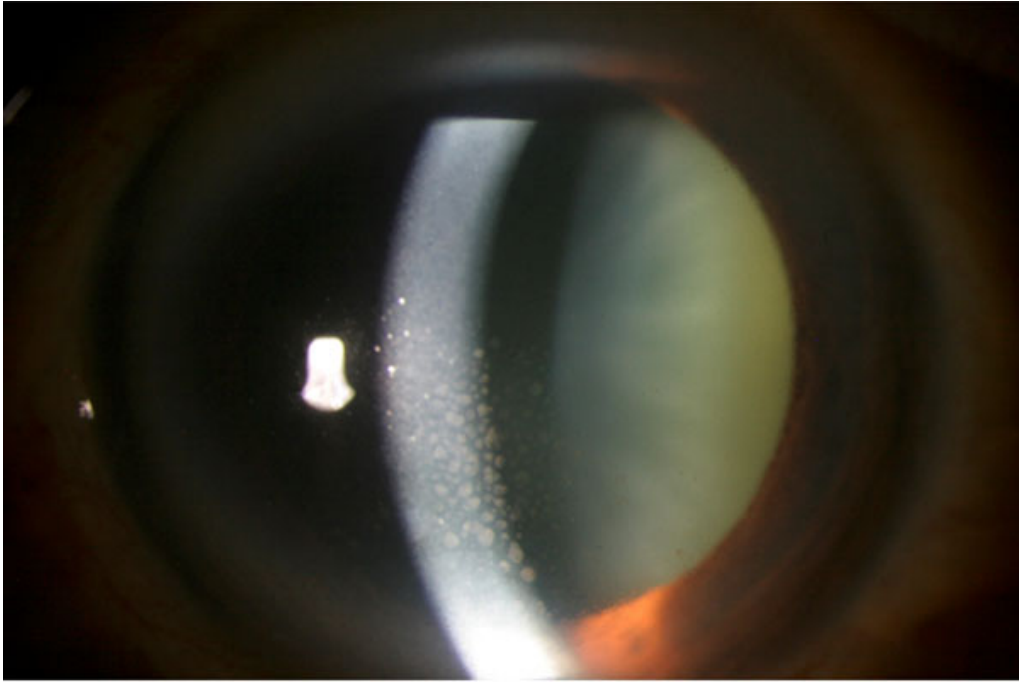
Two forms of retinal necrosis have been described: a fulminant, acute retinal necrosis (ARN) (Figs. 1 and 2), characterized by a rapidly progressive inflammation and necrosis of the peripheral retina that leads to retinal detachment (RD); and another one characterized by multifocal, discrete, white, outer retinal lesions that progress rapidly to confluence. The latter is mainly found in immunocompromised patients and was previously known as progressive outer retinal necrosis (PORN) (Fig. 3).

NHR is caused by reactivation of a previous infection or by a primary infection from the vaccine strain virus. Case reports have described viral retinitis following the administration of intravitreal steroids and in patients with coexisting medical immune-altering comorbidities. Varicella-zoster virus (VZV) and herpes simplex virus (HSV) have been identified as the causative infectious agents in most cases, and, in fewer cases, cytomegalovirus (CMV) or Epstein-Barr virus (EBV).

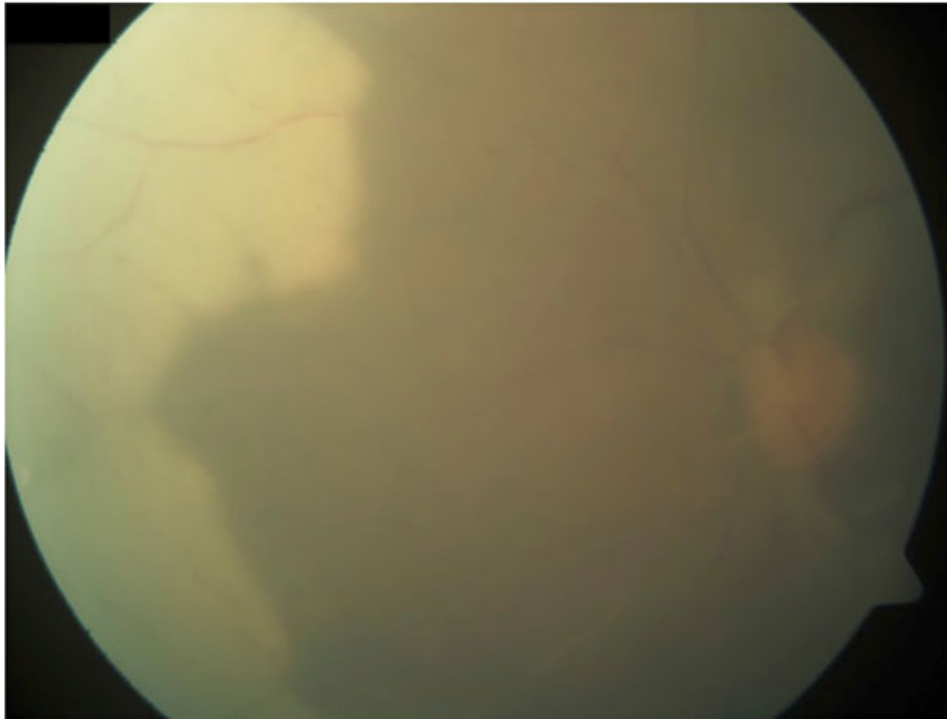
The Herpes virus involved in the infection correlates with the patient’s age. VZV and HSV-1 affect frequently middle aged patients (median age, 57 and 47 years, respectively), while HSV-2 has a bimodal distribution with peaks in the third and sixth decades. It has been reported that younger age, history of neonatal herpes, preexisting chorioretinal scar, and triggering events, such as trauma or systemic corticosteroids, are more commonly associated with HSV-2 reactivation [2]. There is an increased risk of VZV for patients who use azathioprine and/or steroids, and it is more frequent among new users [3].

---

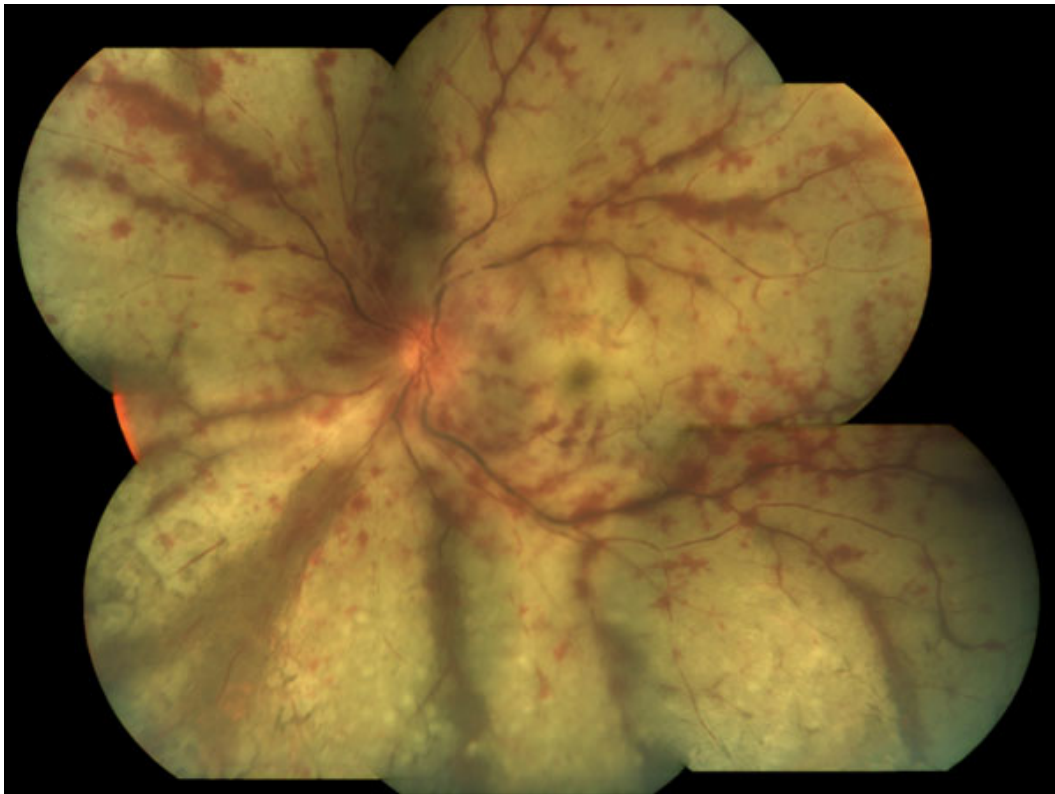
\* Corresponding author **Lourdes Arellanes**: Uveitis Service, Asociación para Evitar Ceguera, Hospital Luis Sánchez Bulnes IAP, Mexico City, Mexico; Tel/Fax: +52 (55) 10841400; Email: lourdes.arellanes@apec.com.mx



**Fig. (1).** Anterior segment of a patient with ARN. Multiple granulomatous keratic precipitates.



**Fig. (2).** ARN characterized by peripheral confluent white patches associated with vitritis, disc swelling and vascular sheathing.



**Fig. (3).** Fundus picture showing the classical “cracked mud appearance” in progressive outer retinal necrosis.

### **ACUTE RETINAL NECROSIS: ESSENTIALS OF DIAGNOSIS**

ARN is characterized by progressive unilateral intraretinal inflammation and necrosis. Clinical diagnosis is based on criteria published by the American Uveitis Society, which include anterior uveitis, vitritis, retinal necrosis beginning in the peripheral retina, and occlusive vasculitis involving the retina and the choroid. Other features that may be observed include optic neuropathy or atrophy, scleritis, and pain [4]. Newer criteria have been added: hyperemia of the optic disc and elevated intraocular pressure. They include clinical course and virologic testing for the diagnosis [5].

Other types of herpetic uveitis with posterior involvement include: 1) multifocal posterior necrotizing retinitis (MPNR), which runs a more aggressive course, macular involvement is *observed in 50%* of cases at presentation, with poorer visual prognosis and a higher rate of RD [6]; 2) slow-type ARN; 3) only vasculitis/papillitis; and 4) panuveitis with lack of necrotic lesions and no obvious vasculitis or papillitis [7].



## Ocular Syphilis

**Claudia Recillas-Gispert\***

*Ophthalmology Department, Instituto Nacional de Ciencias Médicas y Nutrición Salvador Zubirán, Mexico City, Mexico*

Syphilis is a chronic sexually transmitted disease caused by the spirochete *Treponema Pallidum*. Based on its progression, it can be classified as early (primary, secondary and early latent) syphilis, late syphilis and neurosyphilis. Any organ may be affected, including skin, blood vessels, heart, bone, nervous system and the eye [1 - 7].

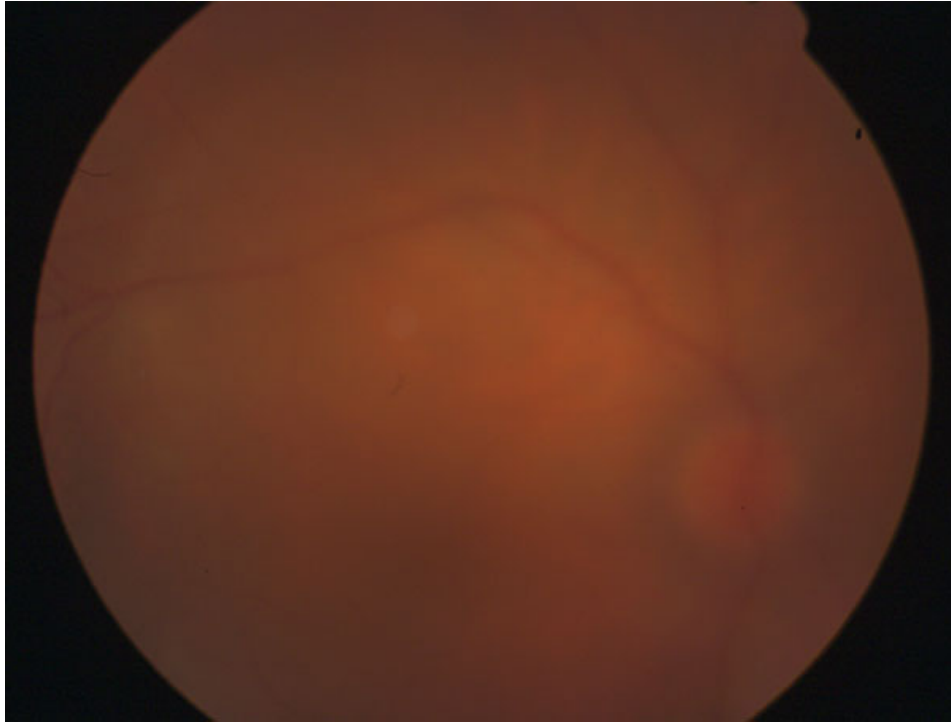
### ESSENTIALS OF DIAGNOSIS

Ocular involvement may occur in any stage of infection and may present in a variety of ways, with panuveitis being the most common manifestation (25% to 54%) [4]. Anterior uveitis has a prevalence of 8%-38% and posterior uveitis varies from 18% to 37% (Figs. 1-3). Optic nerve involvement has been reported in 20% to 38% of cases [3, 8 - 13]. More than half of the cases are bilateral, and visual acuity may range between counting fingers to 20/20. Apart from panuveitis, patients may present with retinal vasculitis (Fig. 4), macular edema (Figs. 5-7), punctate retinitis (Figs. 8 and 9) and, in advanced stages, pigmentary retinopathy will develop (Fig. 10). Gass *et al.* [2] named the distinctive posterior uveitis involvement as “Acute syphilitic posterior placoid chorioretinitis”. It is characterized by the presence of one or more placoid, yellowish outer retinal lesions typically in the macula (Fig. 11) [11]. Since the optic nerve and retina are considered to be extensions of the CNS, ocular syphilis is regarded as a variant of neurosyphilis; thus, every patient with syphilitic uveitis should undergo lumbar puncture and CSF analysis for the detection of neurological involvement [14].

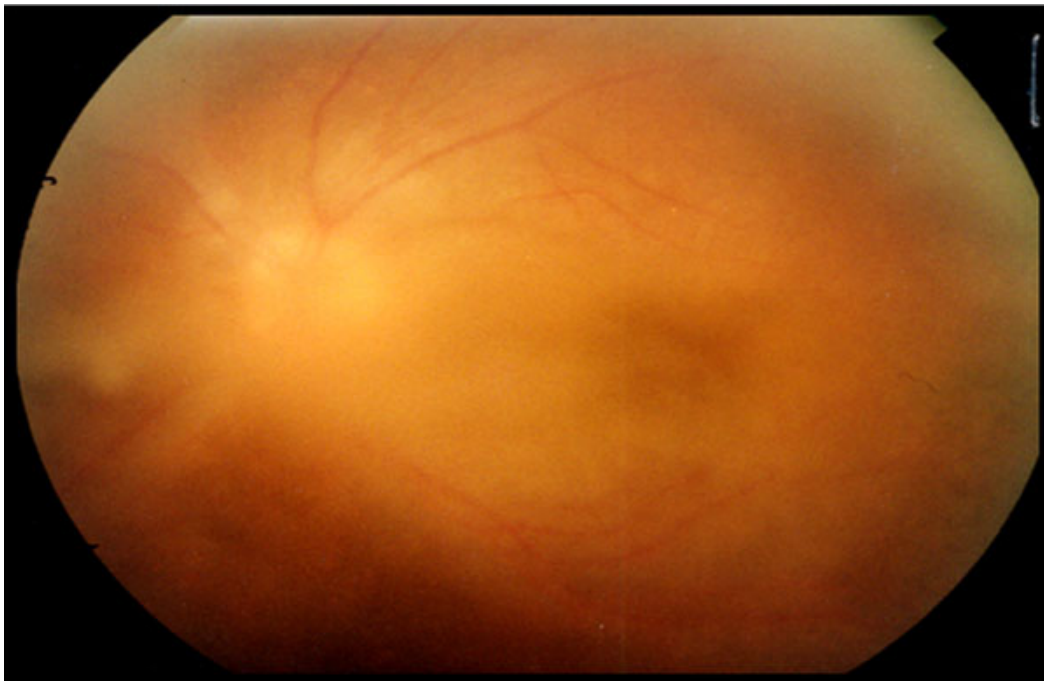
---

\* **Corresponding author Claudia Recillas-Gispert:** Insurgentes Sur 1673, int. 101, Col. San José Insurgentes, Ciudad de México, México; Tel. +52 (55) 5661 1282 /5661 9424; Email: crecillas@yahoo.com

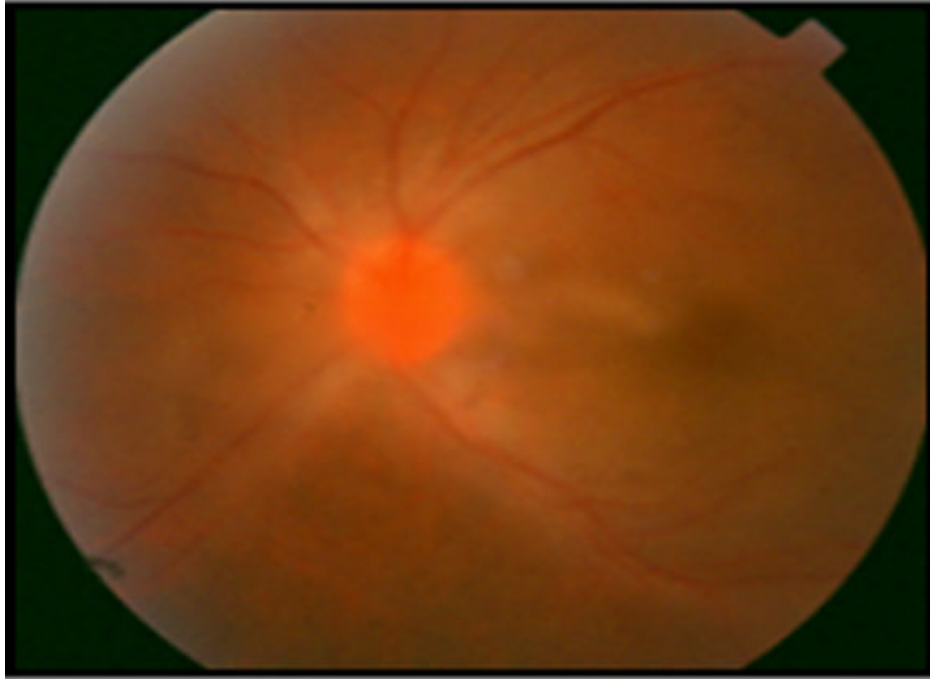



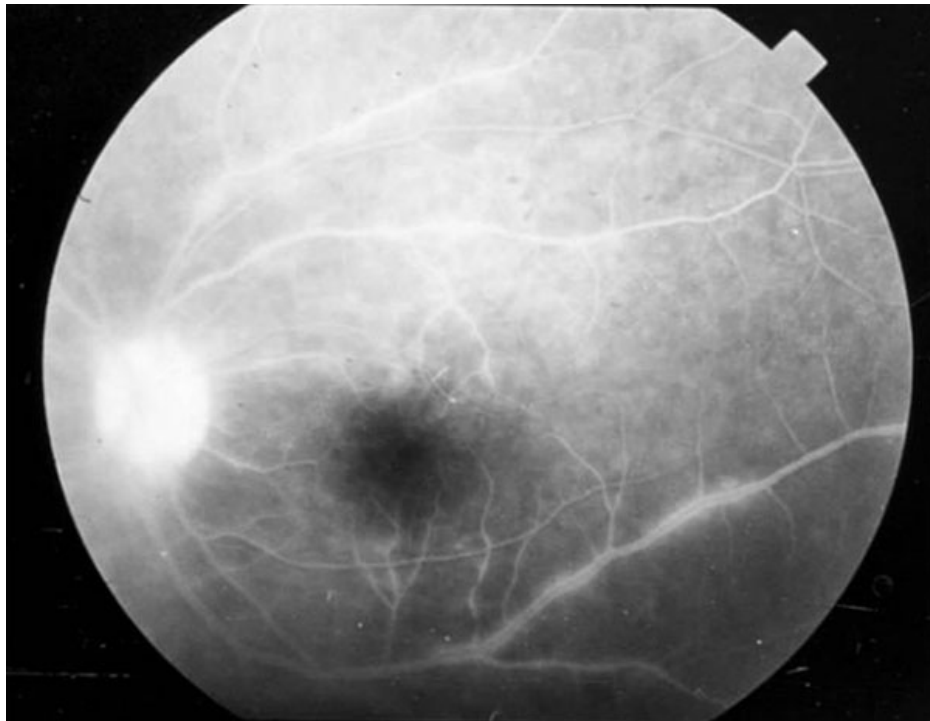
**Fig. (1).** Syphilitic panuveitis. Vitreous and optic nerve inflammation.



**Fig. (2).** Ocular syphilis: Severe vitreous inflammation with areas of retinitis.



**Fig. (3).** Ocular syphilis after Penicillin treatment: Improvement of vitreous and retinal inflammation.



**Fig. (4).** Syphilitic vasculitis. Retinal angiography shows venular staining.

## **HIV-Related Retinal Microangiopathy**

**Claudia Recillas-Gispert\***

*Ophthalmology Department, Instituto Nacional de Ciencias Médicas y Nutrición Salvador Zubirán, Mexico City, Mexico*

HIV affects the human retina in a distinct way by developing ischemic microangiopathy that may be observed as cotton-wool spots, microvascular abnormalities more evident at the retinal periphery, intraretinal hemorrhages and, rarely, arterial plaques [1]. It is asymptomatic in most of the patients.

### **ESSENTIALS OF DIAGNOSIS**

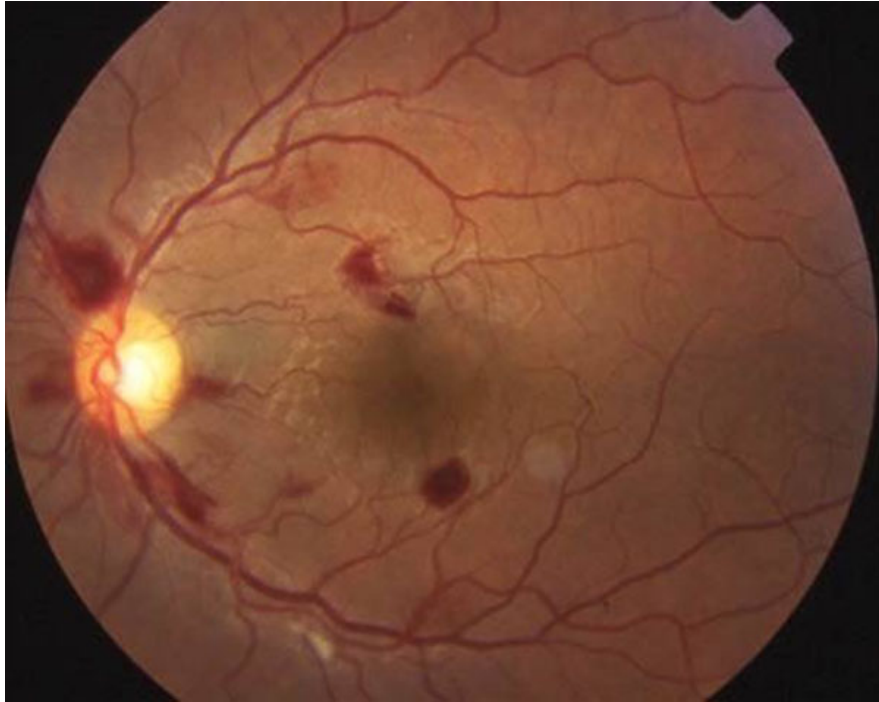The main clinical sign of this pathology is the presence of cotton-wool spots, which appear as fluffy white patches on the retina, usually along the major vascular arcades (Figs. 1-4). This is the earliest and most consistent finding in HIV microangiopathy, occurring approximately 50–60% of patients with advanced disease [2], and is directly affected by CD4+ count: 45% of patients with CD4+ less than 50 cells/ $\mu$ L will present microangiopathy [3] and it has been also related to HIV viral load [4].

These lesions are the result of nerve fiber damage and accumulation of axoplasmic material within the nerve fiber layer [3]. According to histopathological findings, vascular abnormalities include pericyte necrosis, endothelial cell swelling and thickened basement membranes [5]. Hypotheses for the cause of cellular damage include immunoglobulin deposition, endothelial cell infection by HIV and hyperviscosity secondary to increased red cell aggregation, fibrinogen and increased polymorphonuclear leukocyte rigidity [6 - 10].

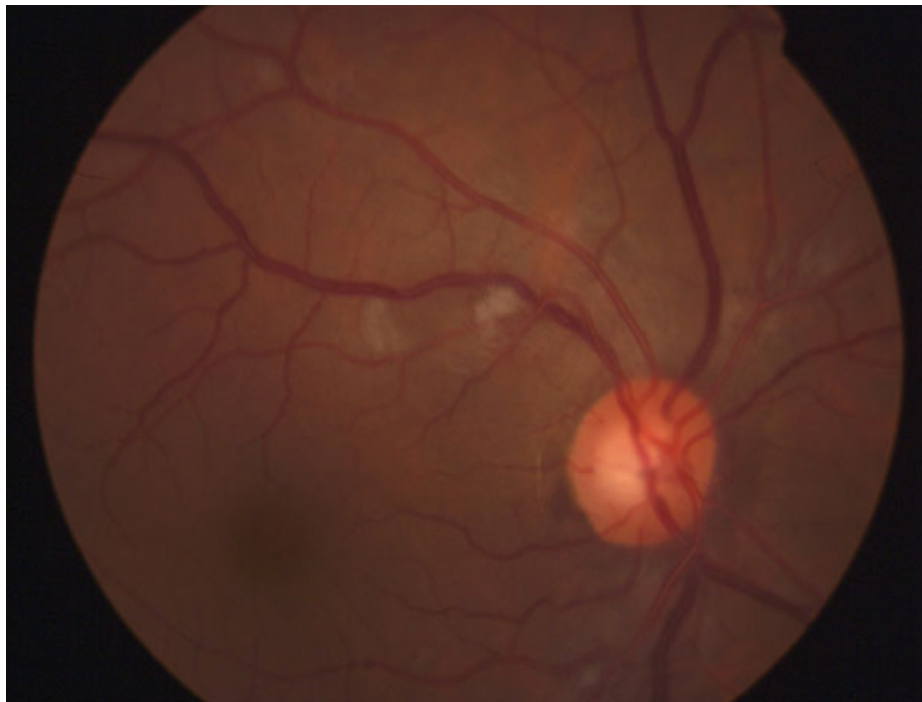
The clinical importance of microangiopathy is that it is a marker for patients with severely compromised immune system and high risk of vision-threatening opportunistic infections.

---

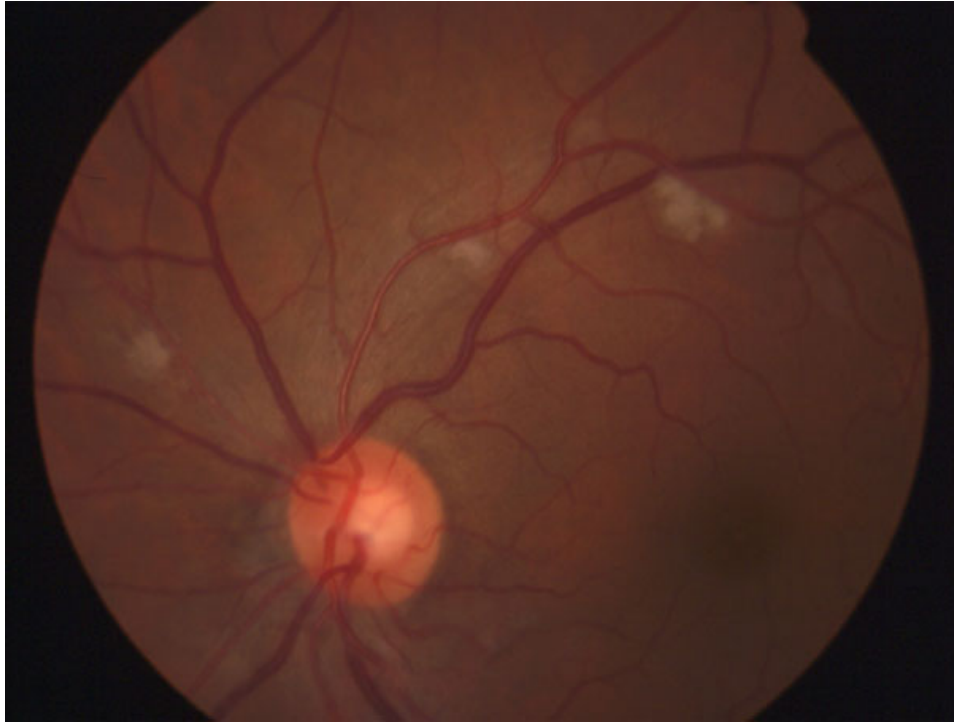
\* **Corresponding author Claudia Recillas-Gispert:** Insurgentes Sur 1673, int. 101, Col. San José Insurgentes, Ciudad de México, México; Tel. +52 (55) 5661 1282 /5661 9424; Email: crecillas@yahoo.com



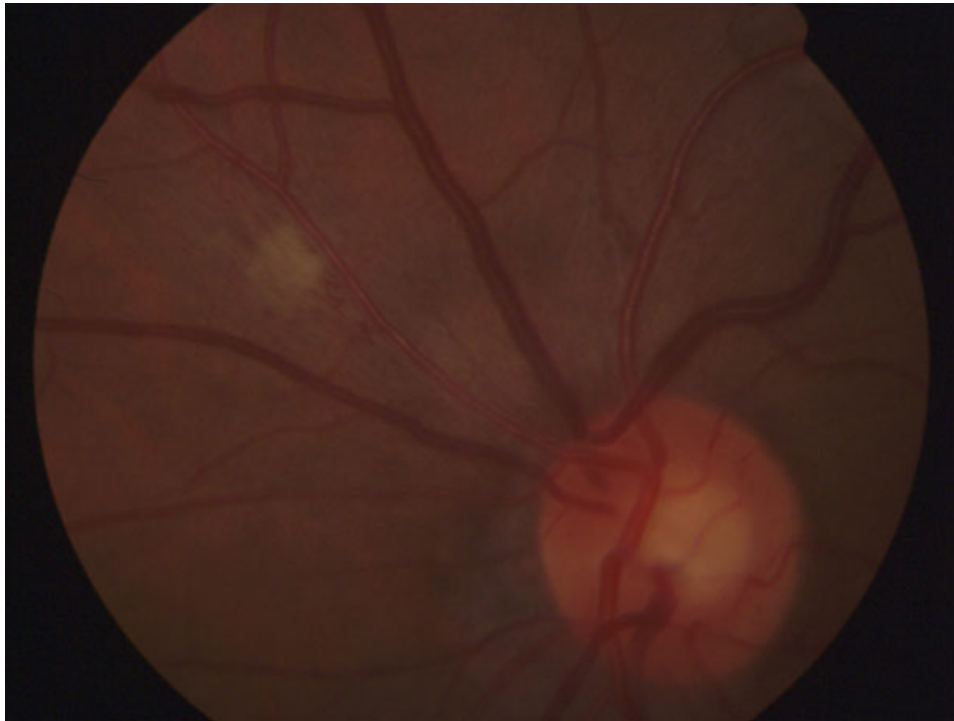
**Fig. (1).** HIV-related retinal microangiopathy: Intraretinal microhemorrhages and one cotton-wool spot.



**Fig. (2).** HIV-related retinal microangiopathy. Right eye.



**Fig. (3).** HIV-related retinal microangiopathy. Left eye.



**Fig. (4).** Close-up of the same eye as Fig. (3). HIV-related cotton-wool spot with small retinal hemorrhages.

## Neuroretinitis

**Gerardo García-Aguirre<sup>1,\*</sup> and José Antonio Unzueta Medina<sup>2</sup>**

<sup>1</sup> Retina Department, Asociación para Evitar la Ceguera en México, and School of Medicine, Instituto Tecnológico y de Estudios Superiores de Monterrey, Mexico

<sup>2</sup> Ophthalmology Department, Hospital Angeles Chihuahua, Chihuahua, Mexico

Neuroretinitis is a term that describes a clinical picture in the posterior pole comprising edema of the optic nerve head and the presence of hard exudates in the macula arranged in a stellate pattern usually called a “macular star” [1]. It may be caused by different etiologies, although the most common cause is *Bartonella* Sp. infection (Cat-scratch disease) [2, 3].

### ESSENTIALS OF DIAGNOSIS

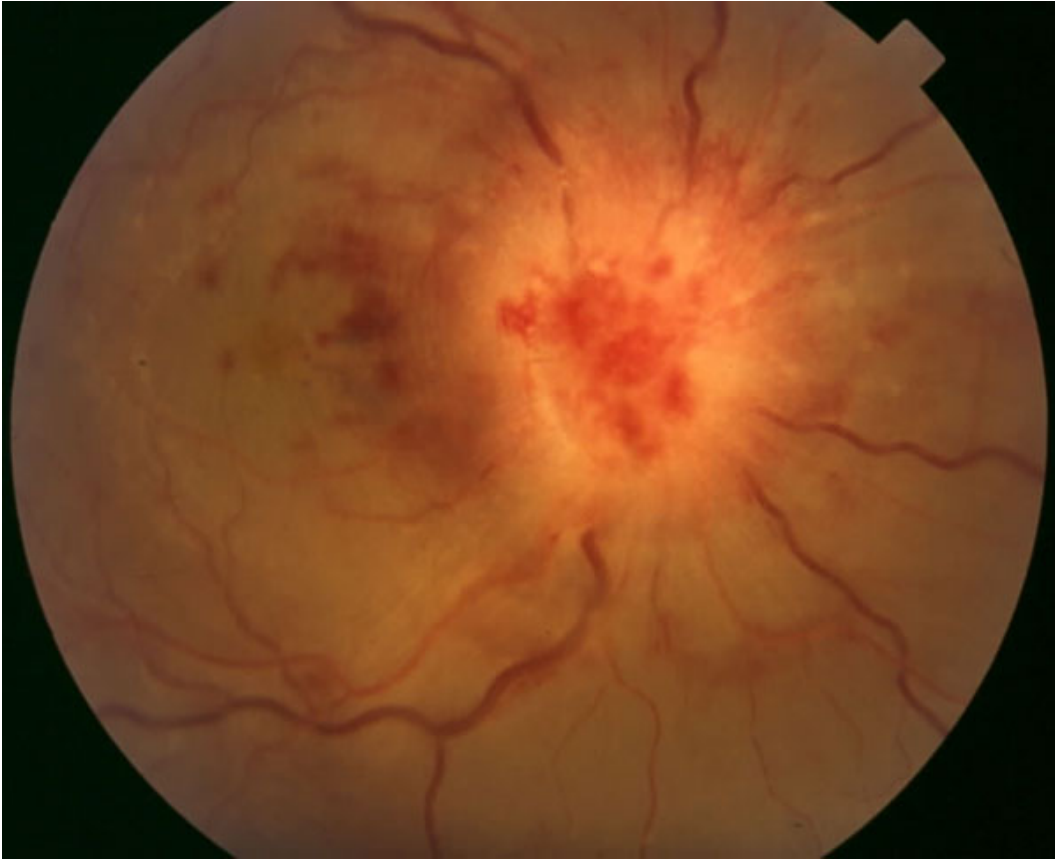Patients with neuroretinitis usually complain of unilateral painless decrease of visual acuity, although they may be asymptomatic.

Diagnosis is based on clinical manifestations readily apparent in ophthalmologic examination. The borders of the optic disc may appear blurred, elevated and/or hyperemic, and the macula may appear thickened, with the presence of hard exudates arranged in a macular star pattern (Figs. 1-5). Hard exudates may not be visible if the patient is examined very early in the disease, and become apparent after approximately two weeks of onset [1, 4]. After treatment is initiated, hard exudates may increase (because of fluid absorption and lipid deposition) before disappearing. Rarely, if the disease causes multiple recurrences, the optic disc may become pale [1, 4, 7].

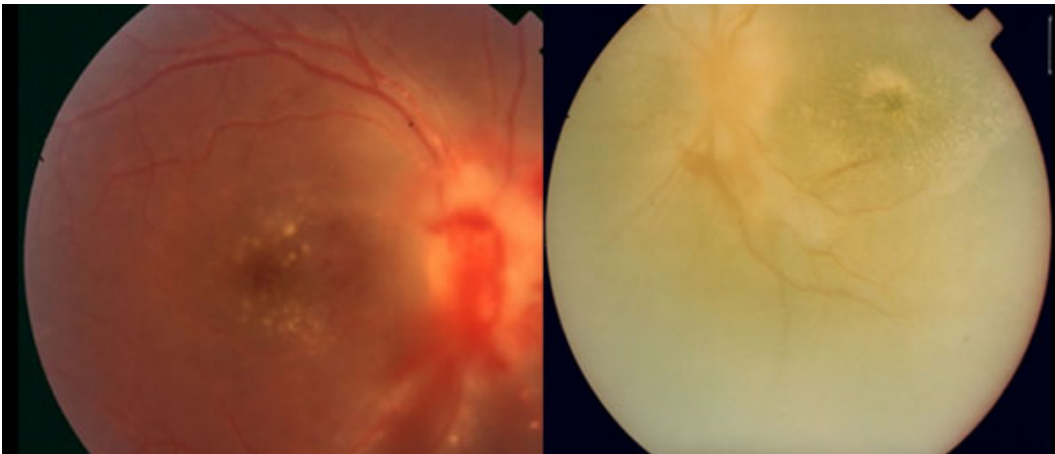
Fluorescein angiography shows papillary hyperfluorescence. Peripapillary vessels may also show hyperfluorescence secondary to vascular incompetence [1]. Optical coherence tomography may show intra or subretinal fluid, and the presence of hyper-reflective foci corresponding to hard exudates [5]. Auto-fluorescence may also highlight exudates in the macular region [6].

---

\* Corresponding author Gerardo García-Aguirre: Asociación para Evitar la Ceguera en México, Vicente García Torres 46, San Lucas Coyoacan, Ciudad de México, México, 04030; Tel: +52 (55) 10841400; Email: jerry\_gar\_md@yahoo.com

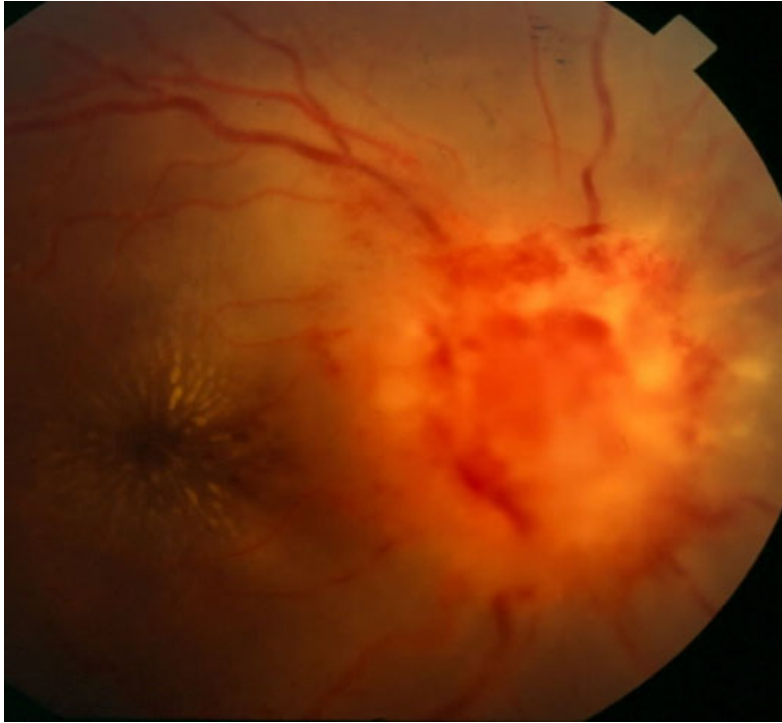


**Fig. (1).** Patient with papillitis and juxtapapillary choroidal involvement.

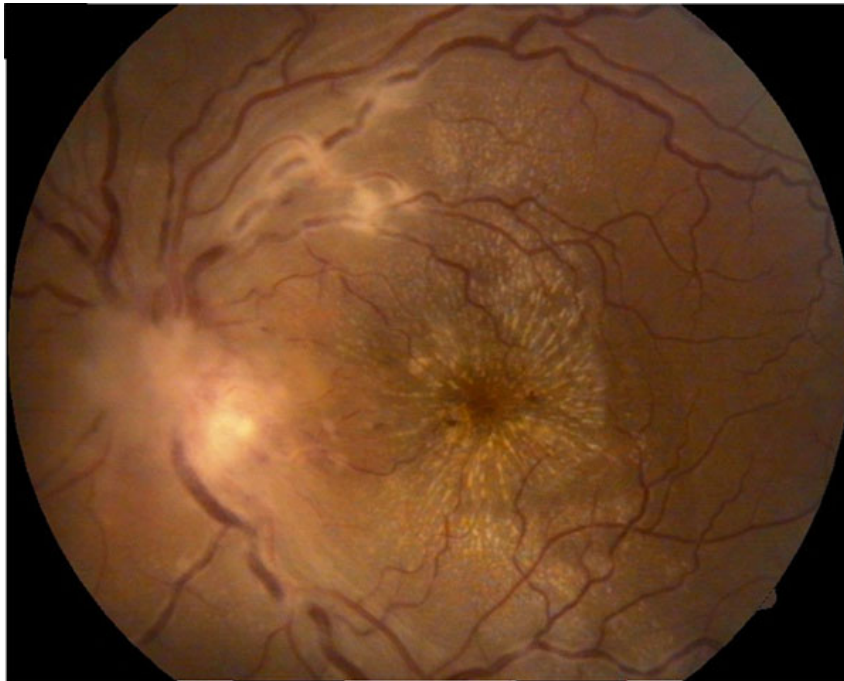

**Fig. (2).** Papillitis and peripapillary nerve fiber layer hemorrhages. There is a variable degree of lipid staining into the macula.





**Fig. (3).** Infiltrated nerve, prominent vessels and macular star in a patient with toxoplasmosis.



**Fig. (4).** Fundus photograph of patient with neuroretinitis demonstrates optic disc edema, vasculitis and macular star figure (Courtesy of Ophthalmology Department, Hospital Central de Maracay, Venezuela).



## Endophthalmitis

Ezequiel Rosendi<sup>1</sup>, Cecilia Marini<sup>2\*</sup> and Ricardo Brunzini<sup>3</sup>

<sup>1</sup> Retina and Vitreous Department, Hospital de Alta Complejidad El Cruce, Buenos Aires, Argentina

<sup>2</sup> Cornea and Ocular Surface Department, Hospital de Alta Complejidad El Cruce, Buenos Aires, Argentina

<sup>3</sup> Consultorio Brunzini, Buenos Aires, Argentina

### ESSENTIALS OF DIAGNOSIS

Endophthalmitis (E): Severe intraocular inflammation associated with lid swelling, pain (absent in 26% of cases), anterior chamber with cells or hypopyon, vitritis and blurring or loss of vision, without involving the sclera and the extraocular orbital structure. “Panophthalmitis” involves outer layers (Figs. 1c and 6). Cases with an infectious etiology are the most devastating ones and carry guarded prognosis.

### Classification (Table 1)

Table 1. Endophthalmitis Classification.

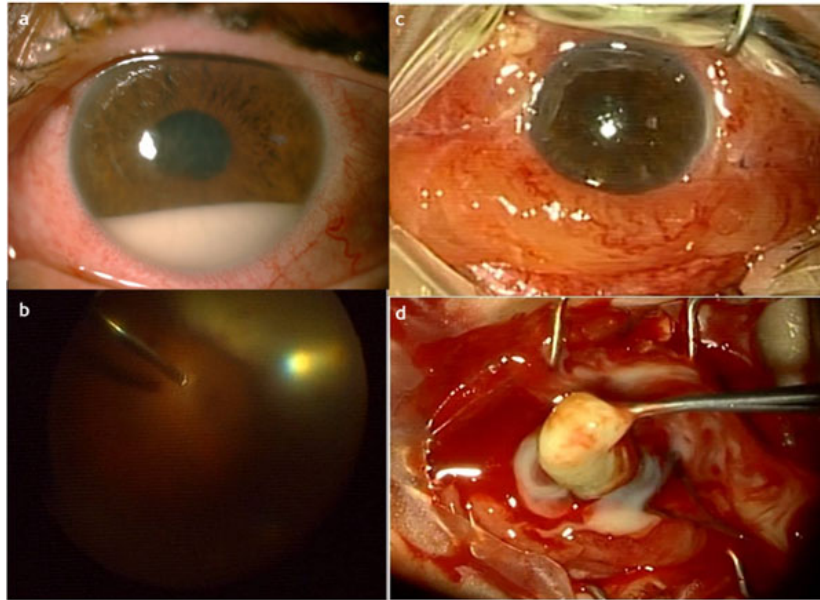
Exogenous Endophthalmitis (EE)	<ul style="list-style-type: none"> <li>• Postoperative Endophthalmitis               <ul style="list-style-type: none"> <li>* Acute.</li> <li>* Chronic.</li> </ul> </li> <li>• Post-traumatic Endophthalmitis (Fig. 16)</li> <li>• Associated with infectious keratitis.</li> </ul>
Endogenous Endophthalmitis (Ee) (Figs. 1, 21-23, 27, 28)	<ul style="list-style-type: none"> <li>• Focal (anterior and posterior).</li> <li>• Diffuse (anterior and posterior).</li> </ul>

### • Postoperative Endophthalmitis (PE):

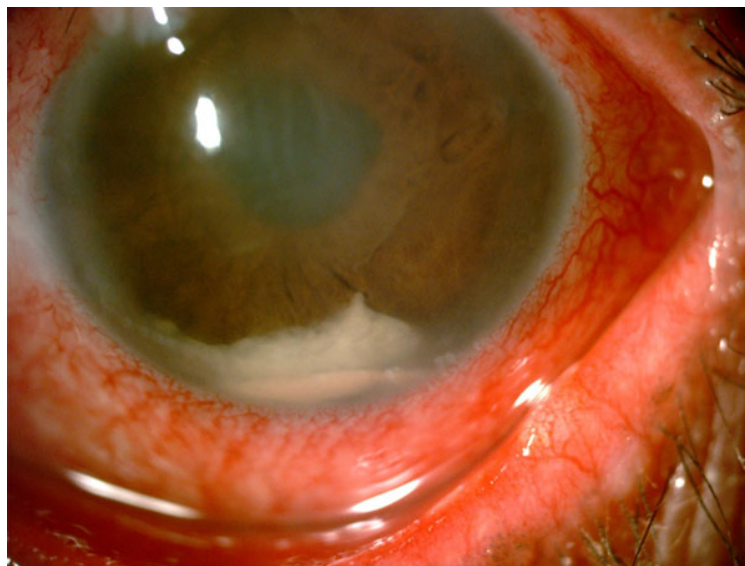
E. is a potentially blinding complication with irreversible tissue damage after ocular surgery [1] (Figs. 2-5, 7-14, 26, 29). Most of the cases arise from cataract surgeries [2]. Early diagnosis and prompt treatment are therefore essential.

\* Corresponding author Cecilia Marini: Cornea and Ocular Surface Department, Hospital de Alta Complejidad El Cruce, Buenos Aires, Argentina; Tel/Fax: +54 911 60453004; Email: mariniceci@hotmail.com

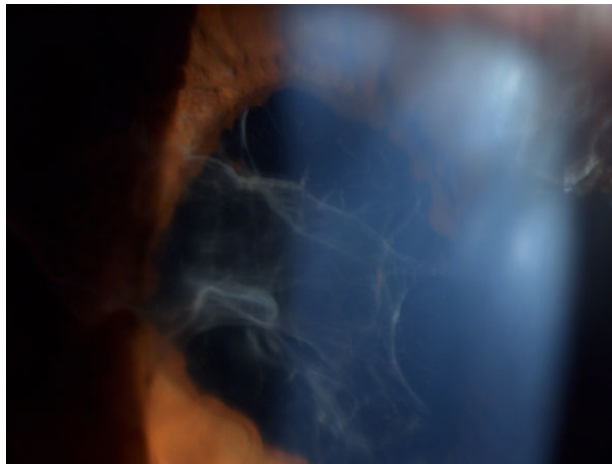
Commensal organisms found in the normal ocular flora are the most common cause. A mandatory step to reduce bacteria in the wound area is to apply povidone-iodine 5-10% to the cornea, conjunctival sac and periocular skin for a minimum of 3 minutes prior to surgery.



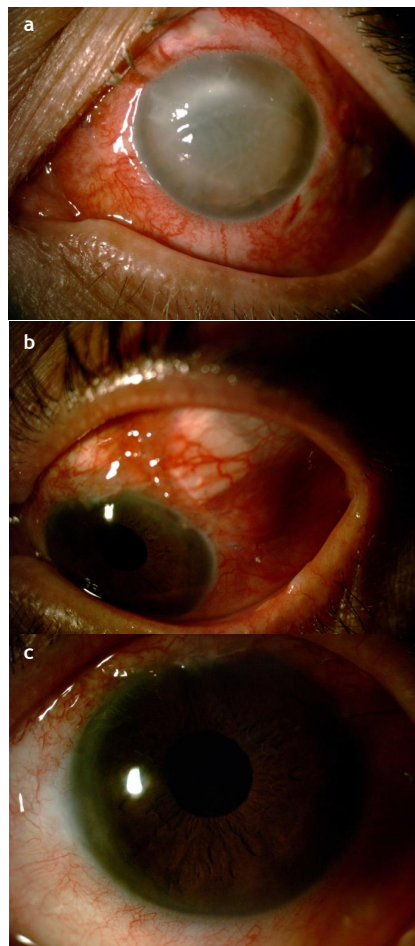
**Fig. (1).** *Klebsiella spp.* Endogenous Endophthalmitis. 50-year-old woman. Diabetes. *Klebsiella spp.* hepatic abscess. **a)** Hypopyon and corneal haze. **b)** Identification of subretinal abscess during vitrectomy. **c)** Progression into panophthalmitis. **d)** Evisceration.



**Fig. (2).** Postoperative Endophthalmitis: Hypopyon associated with fibrin clot. Hazy cornea, pupillary membrane. Gram-positive Coccus.



**Fig. (3).** Exogenous Endophthalmitis. Anterior chamber fibrin.



**Fig. (4).** a) Late bleb-associated endophthalmitis. Not culture proven. Treated with intravitreal medication and vitrectomy. b) Scleral patch over trabeculectomy site. c) Good progress.

## **Acute Posterior Multifocal Placoid Pigment Epitheliopathy**

**Luciana García**<sup>1,2,\*</sup>

<sup>1</sup> *Centro de la Visión Gordon-Manavella, Rosario, Santa Fe, Argentina*

<sup>2</sup> *Oftalmofunes, Funes, Santa Fe, Argentina*

First described in 1968 by Don Gass, MD [1], Acute Posterior Multifocal Placoid Pigment Epitheliopathy (APMPPE) is a bilateral but asymmetrical condition affecting young people between the second and fourth decades of life without sex predilection.

This is an idiopathic condition, but a viral prodrome has been associated in about one third of patients.

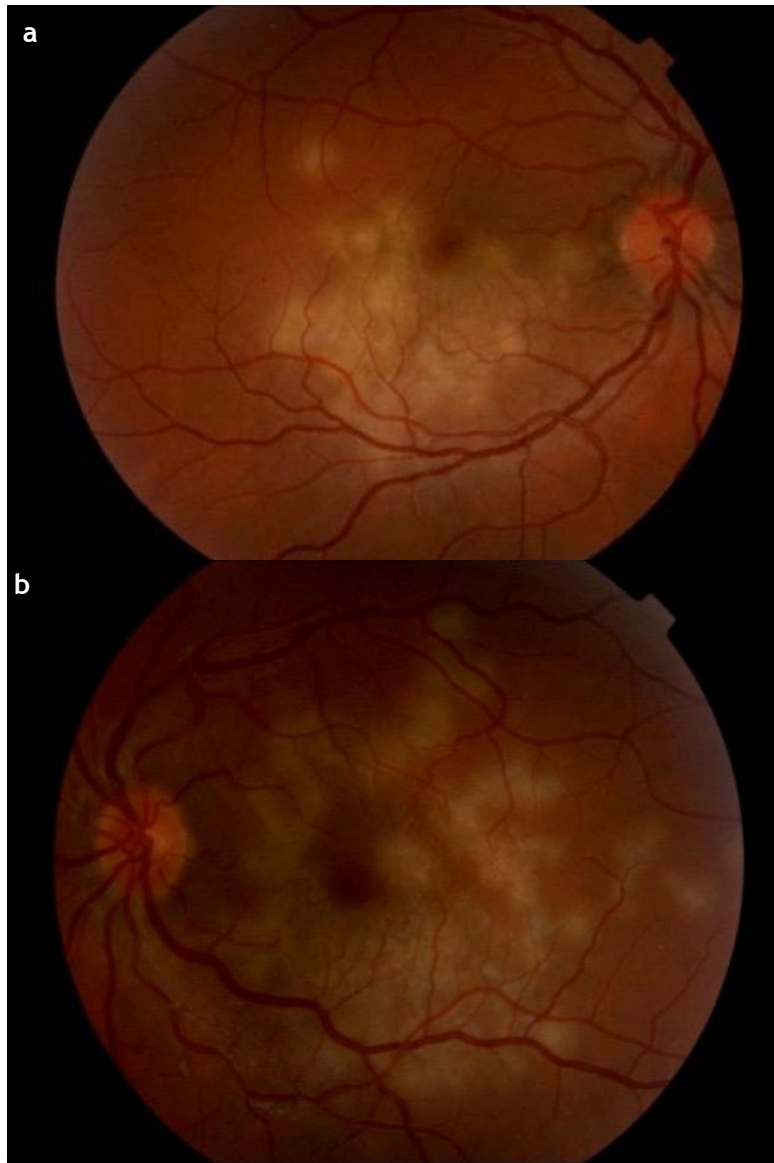
### **ESSENTIALS OF DIAGNOSIS**

To arrive at a diagnosis of APMPPE, both clinical and ophthalmoscopic features are important. Patients complain of blurred vision, photopsias and scotomas in one eye; the second eye may not be involved until several days or weeks after the first one. Several reports exist about the potential central nervous system (CNS) vasculitis changes associated with APMPPE [2, 3].

Ophthalmoscopic features include multiple, flat, deep yellow-white plaques located at the posterior pole (Fig. 1). Lesions appear to be at the level of retinal pigment epithelium (RPE), but controversy exists about whether APMPPE is a primary disease of RPE or a consequence of vasculitis affecting choroidal vessels [4, 5]. A few weeks after the improvement of fundus appearance, plaques begin to heal, leaving RPE mottling and atrophy (Fig. 2).

---

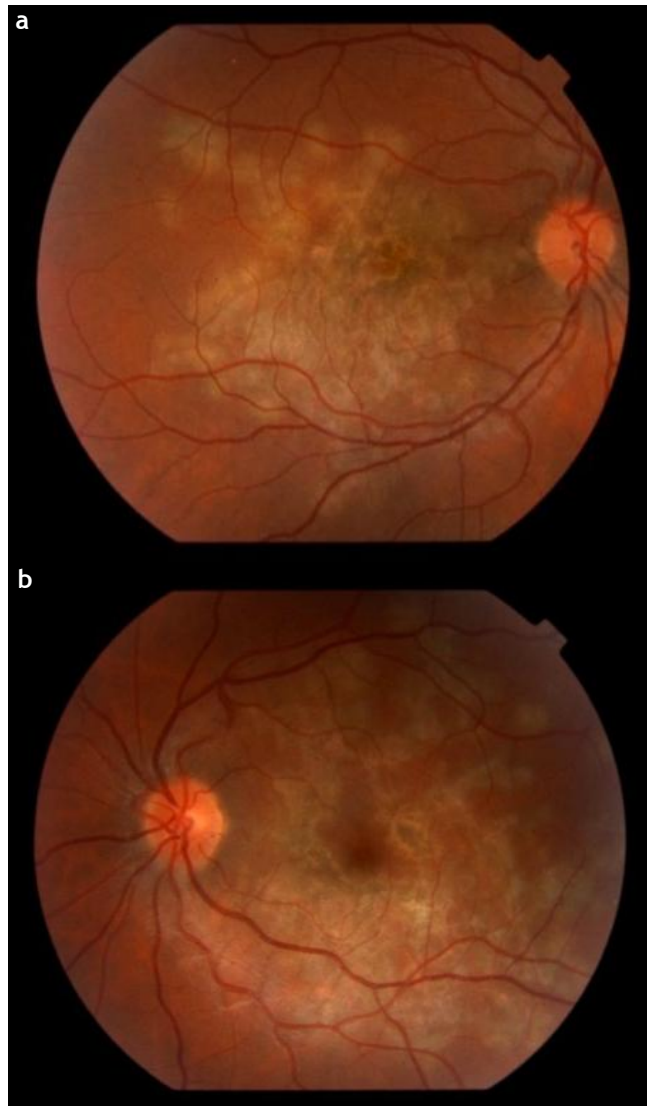\* **Corresponding author Luciana García:** Centro de la Visión Gordon Manavella, Rosario, Santa Fe, Argentina; Tel: +54 (341) 4400239; Email: lu-gar@hotmail.com



**Fig. (1).** (a) and (b) Color fundus photographs showing multiple, deep yellow-white lesions in a case of APMPPE in a young woman with bilateral involvement (Courtesy of Maximiliano Gordon, MD).

Others forms of compromise include serous retinal detachment, retinal vasculitis, papillitis and vitreous haze [6 - 9].

Ancillary tests include fluorescein angiography (FA), indocyanine green angiography (ICGA), visual field perimetry and optical coherence tomography (OCT).



**Fig. (2).** (a) and (b) Color fundus photographs of the same patient after treatment with corticosteroids because of macular involvement and severe visual loss. Observe RPE mottling and atrophy (Courtesy of Maximiliano Gordon MD).

FA shows the characteristic pattern with early blocking hypofluorescence in the acute phase followed by staining and pooling in the late frames. Late state is characterized by hyperfluorescence without leakage (Fig. 3), a consequence of windows defect [8]. Hypofluorescence, in both intermediate and late frames [6], is observed in ICGA.

Static perimetry shows objectively the scotoma referred by patients.

## **Multiple Evanescent White Dot Syndrome**

**Ariel Schlaen\***

*Hospital Universitario Austral, Buenos Aires, Argentina*

### **ESSENTIALS OF DIAGNOSIS**

Multiple evanescent white dot syndrome (MEWS) is a rare, predominantly unilateral posterior uveitis [1, 2]. It is characterized by the presence of multiple, small, white or yellowish white dots located at the level of the outer retina, RPE, and inner choroid. The lesions may range in size from 100  $\mu\text{m}$  to a half disc diameter and may concentrate around the optic disc and along the vascular arcades extending to mid-periphery (Figs. 1 and 3). Each lesion is composed of many smaller dots which can be appreciated at high magnification by slit lamp biomicroscopy [3]. Macular examination reveals the presence of tiny white or orange specks, which confer the fine granular aspect of the fovea, considered to be pathognomonic of this syndrome [4, 5]. Optic disc inflammation, along with vitreous cells, can accompany the deep retinochoroidal lesions. In infrequent occasions, a mild anterior segment inflammation is observed [6]. Sometimes a relative afferent pupillary defect is noted [3].

Symptoms include the development of vision loss of sudden onset, visual field defects, floaters, photopsias and dyschromatopsia [2].

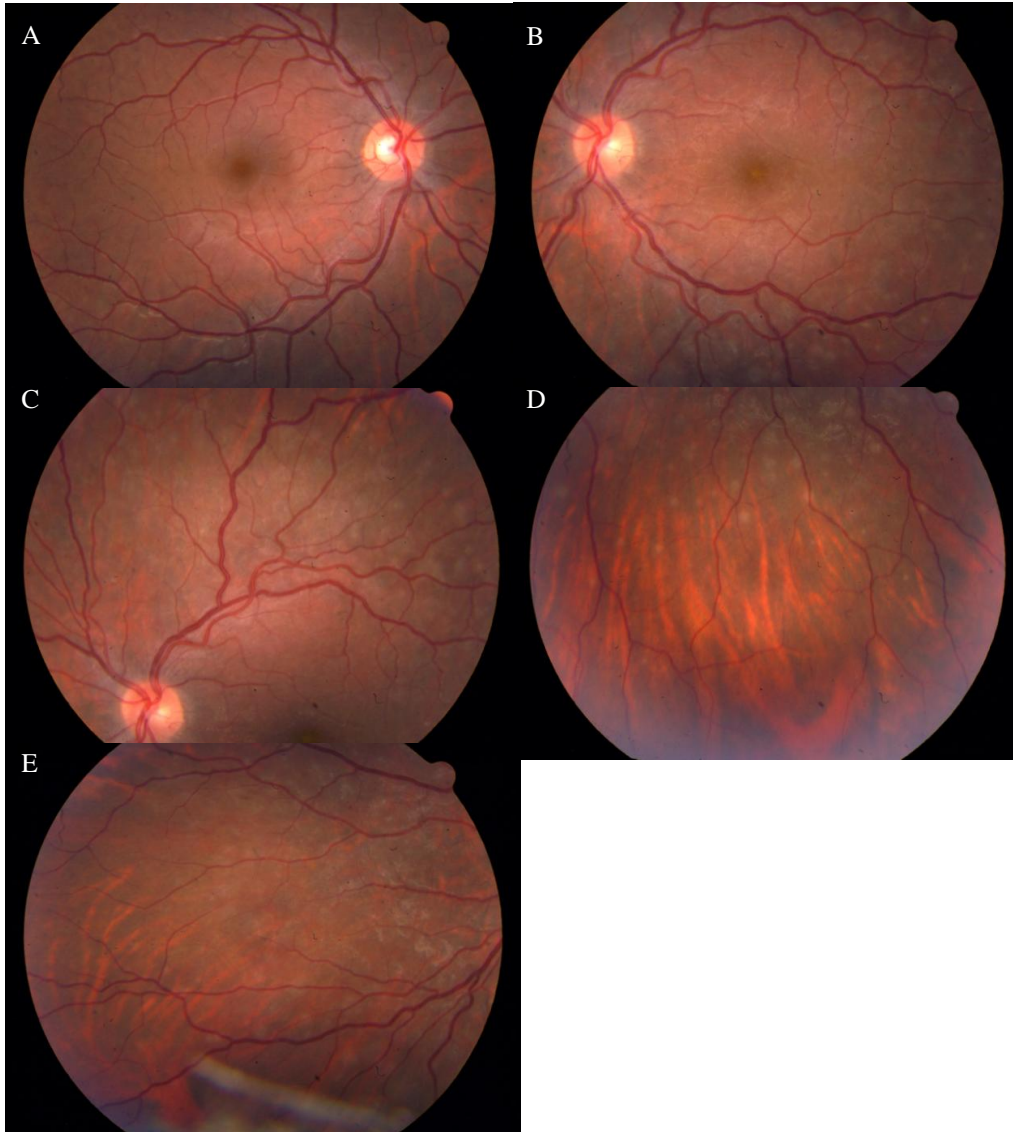
Approximately one third of the cases are preceded by a flu-like illness [3]. Women are more frequently affected than men [1]. In spite of the fact that initially MEWDS was thought to be an acute, monophasic, self-limited, unilateral disease with a quick resolution of the alterations, the disorder may have bilateral involvement, relapse, be complicated by choroidal neovascularization, or develop chorioretinal scars [2, 3]. Occasionally, it has been reported to be associated to acute multifocal choroiditis and panuveitis [7], acute zonal occult outer retinopathy [8], acute idiopathic blind spot enlargement syndrome [9] or acute macular neuroretinopathy [10].

---

\* **Corresponding author Ariel Schlaen:** Hospital Universitario Austral, Buenos Aires, Argentina; Tel/Fax: +54 911 43931844; Email: ariel.schlaen@gmail.com



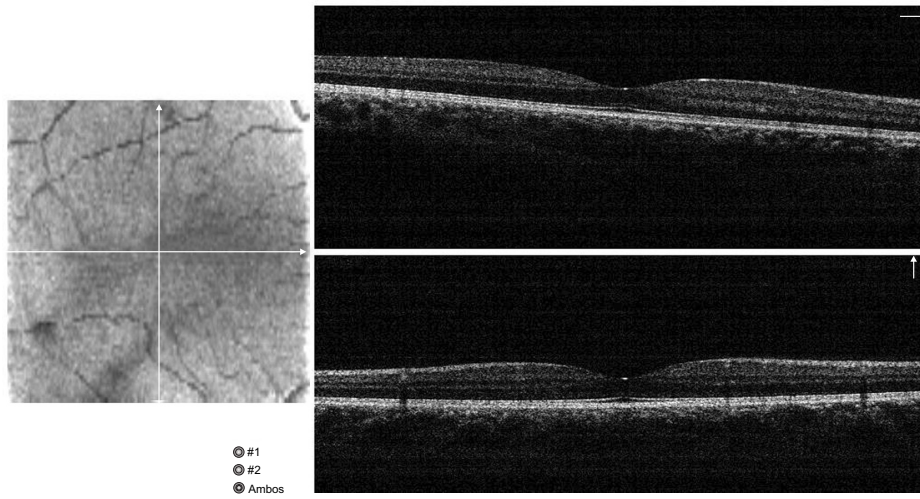
Visual field tests usually show a blind spot enlargement, associated to paracentral, temporal, or scattered scotomas, which may not be correlated with ophthalmologic findings [2, 3, 11].



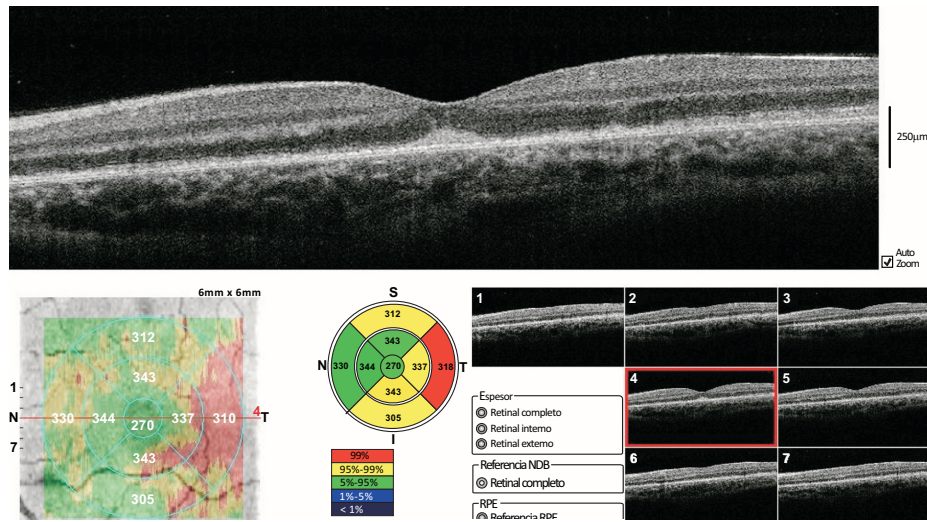
**Fig. (1).** 24-year-old male patient. Multiple evanescent white dot syndrome was diagnosed in his left eye. **(A)** Right eye is unaffected. **(B)** Macular granularity along with subtle undefined multiple white dots at posterior pole can be observed. **(C)** Temporal, **(D)** inferior, and **(E)** nasal periphery are also involved with the typical lesions.



A



B



**Fig. (2).** Spectral-domain optical coherence tomography of the same patient from Fig. (1). (A) Right eye is unremarkable. (B) At left eye, outer layers are disrupted, and a dome-shaped pattern can be observed at the fovea.

## **Multifocal Choroiditis**

**Amina L. Chaudhry and Debra A. Goldstein\***

*Northwestern University, Chicago, IL 60611, USA*

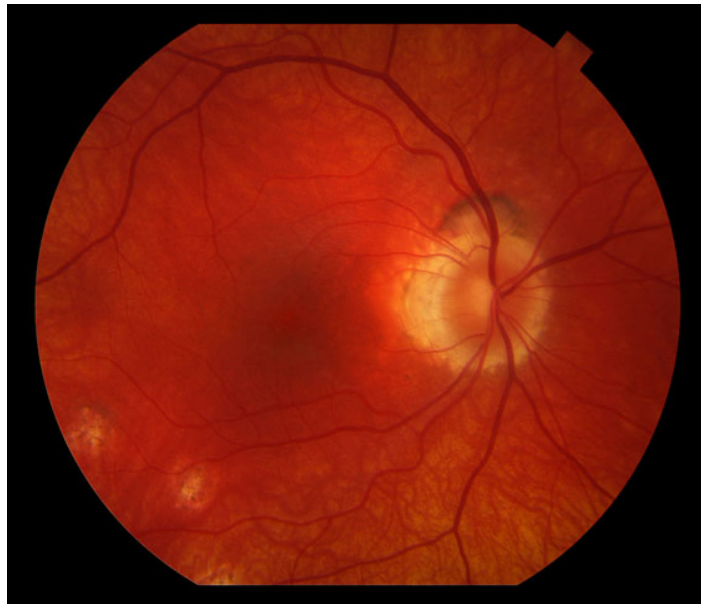### **ESSENTIALS OF DIAGNOSIS**

There has been much discussion over the years regarding whether multifocal choroiditis (MFC) and punctate inner choroidopathy (PIC) represent different names for the same disease entity [1]. However, there are clearly differences between MFC with panuveitis and PIC [2, 3]. This chapter will deal only with the forms of MFC with associated intraocular inflammation, rather than PIC/MFC without inflammation.

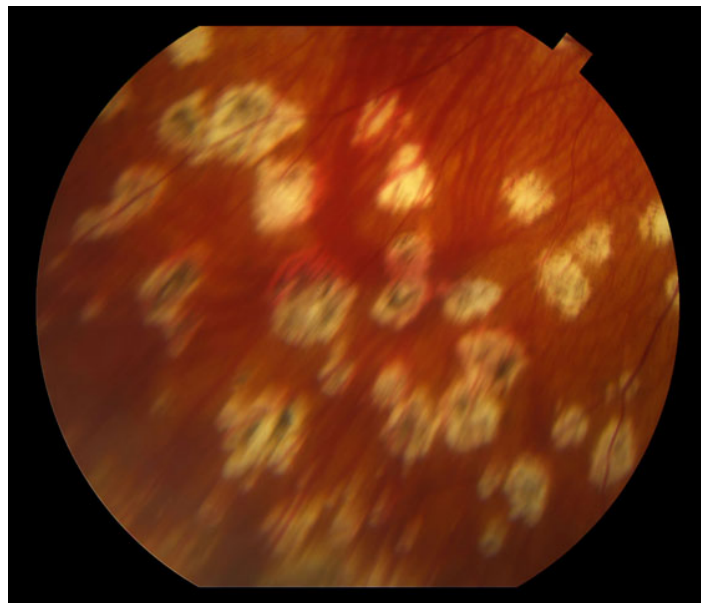
Multifocal choroiditis (MFC) is a chronic inflammatory condition that is typically bilateral, and more commonly seen in women. The age range is broad, but it most commonly affects young to middle-aged myopic females [2 - 4]. The most common presenting complaints are decreased visual acuity, floaters, and photopsias. On exam most patients will present with vitreous cells, and approximately 50% will have anterior chamber cells. Fundoscopic findings consist of multiple yellow to grey lesions, 50 to 1,000 microns in size, at the level of the retinal pigment epithelium (RPE) and inner choroid layer [3, 5]. The lesions may be distributed anywhere in the fundus from the peripapillary region, within the arcades, and into the periphery. Active lesions may be associated with indistinct borders and subretinal fluid. Some patients present with disc edema, cystoid macular edema (CME); and in 25 to 39% of patients, macular and peripapillary choroidal neovascularization may develop [2, 3]. Inactive lesions appear as clearly defined, punched-out scars with variable pigmentation (Figs. **1a**, **1b** and **1c**).

---

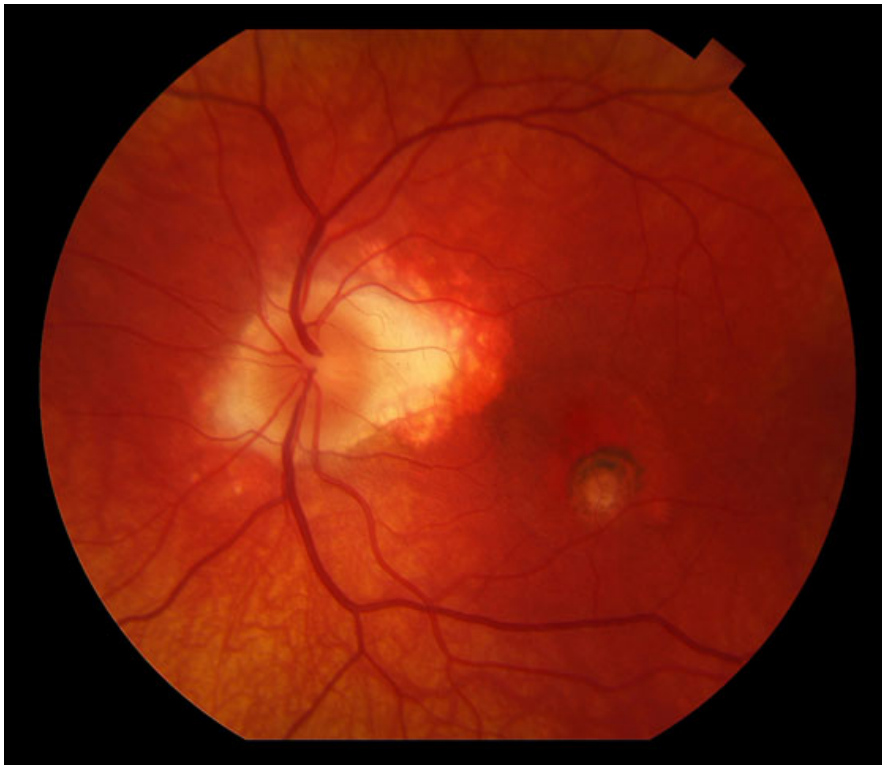\* **Corresponding author Debra A. Goldstein:** Northwestern University, Chicago, Illinois, 60611, USA; Tel: (312) 9088152; Fax: (312) 5038152; Email: [debrgold@yahoo.com](mailto:debrgold@yahoo.com)



**Fig. (1).** 25-year-old woman with chronic granulomatous iridocyclitis and multifocal choroiditis. She presented 3 years earlier with granulomatous KP OU, AC cells, vitreous cell, haze and multifocal choroidal lesions as well as subretinal neovascular membranes OU. The uveitis has recently been well controlled on systemic immunomodulatory therapy, with no new lesions or subretinal neovascular membranes. Fig. (1a). Color fundus photo -- Posterior pole (Right eye). There is no vitreous haze. There is mild disc hyperemia. There are inactive atrophic choroidal lesions, and a white ring of subretinal fibrosis around the disc, with two old peripapillary subretinal neovascular membranes.



**Fig. (1b).** Color fundus photo -- Periphery (Right eye). Inactive atrophic lesions with distinct borders and variable pigmentation.



**Fig. (1c).** Color fundus photo -- Posterior pole (Left eye). There is no vitreous haze. There is mild disc edema and hyperemia. There is an atrophic lesion inferior to the fovea with an adjacent scar of a subretinal neovascular membrane. There are extensive peripapillary scarring and evidence of a peripapillary neovascular membrane.

Active lesions show conical sub-RPE material, underlying choroidal hyper-reflectivity, and overlying vitreous cells on SD-OCT imaging [1, 2]. Choroidal hyper-reflectivity is thought to result from changes in both photoreceptors overlying the sub-RPE deposits and from disturbance in RPE itself [2]. In the inactive phase, depending on permanent photoreceptor and RPE damage, there may be variable reconstitution of the normal outer retinal layers, reduction of choroidal hyper-reflectivity, persistent RPE elevation, or small punched out scars with absence of RPE [1, 2] (Figs. **1d**, **1e** and **1f**).

On fluorescein angiography (FA), active lesions show early hypofluorescence with late staining and leakage. Inactive scars demonstrate window defects with early hyperfluorescence, well defined borders, and late fading [1, 4]. Indocyanine angiography (ICG) demonstrates hypofluorescent round spots, 200 to 500 microns in size, in the posterior pole. On fundus autofluorescence (FAF), the RPE elevations are seen as round areas of minimal hyperautofluorescence or absent autofluorescence in areas of RPE dehiscence [1].

## **Punctate Inner Choroidopathy**

**Amina L. Chaudhry and Debra A. Goldstein\***

*Northwestern University, Chicago, IL 60611, USA*

### **ESSENTIALS OF DIAGNOSIS**

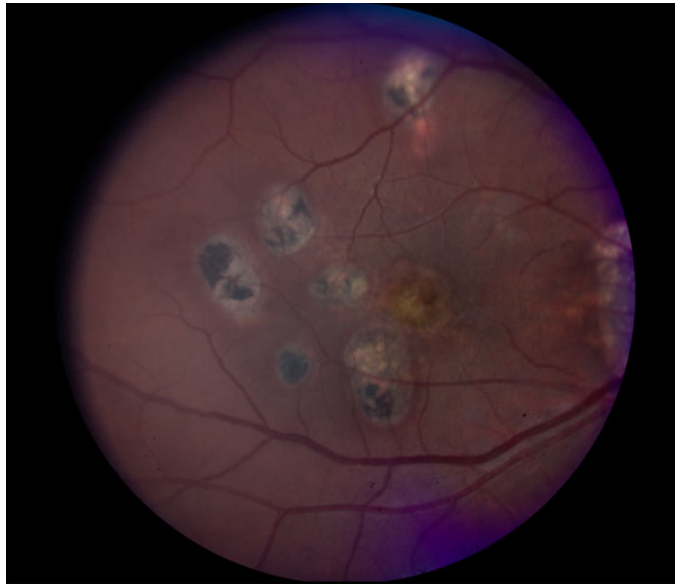Punctate inner choroidopathy (PIC) typically affects young myopic females, with a mean age of onset of 26 years (range 16 to 40 years) [1]. Clinically, patients present with blurred vision, central or paracentral scotomas, enlargement of the blind spot, or photopsias. On exam there is no clinically apparent intraocular inflammation [1, 2]. Fundoscopic findings consist of yellow lesions with indistinct borders that measure 100 to 300 microns in size, typically located in the posterior pole or the mid periphery. These PIC lesions occur at the level of the inner choroid and retinal pigment epithelium (RPE). Active lesions may be associated with small amounts of subretinal fluid and serous retinal detachment. Occasionally, the optic nerve is hyperemic, but cystoid macular edema (CME) does not occur. The acute lesions may resolve after a few weeks, leaving atrophic spots with a punched out appearance and variable pigmentation [2, 3] (Figs. 1 and 2). In many patients, such resolution leads to improvement of visual symptoms but in about 25% of eyes more severe visual loss subsequently occurs, primarily due to development of choroidal neovascularization (CNV).

Active lesions in PIC demonstrate early mild hyperfluorescence with late leakage on fluorescein angiography. With disease progression, damage to the RPE occurs and window defects are seen. Leakage of fluorescein into the subretinal space may be observed in patients with a serous retinal detachment [2, 4]. The small, multiple subretinal lesions demonstrate hypofluorescence in the early, middle, and late phases of the ICG [2, 4]. ERG may be normal or show mild asymmetry of b-wave amplitude. SD-OCT may show RPE elevation with hyper-reflective sub-RPE signals, obscuration and displacement of photoreceptors and disruption of Bruch's membrane. Over time with resolution of RPE elevations, the photoreceptor layer may become visible again. Some patients may show no RPE

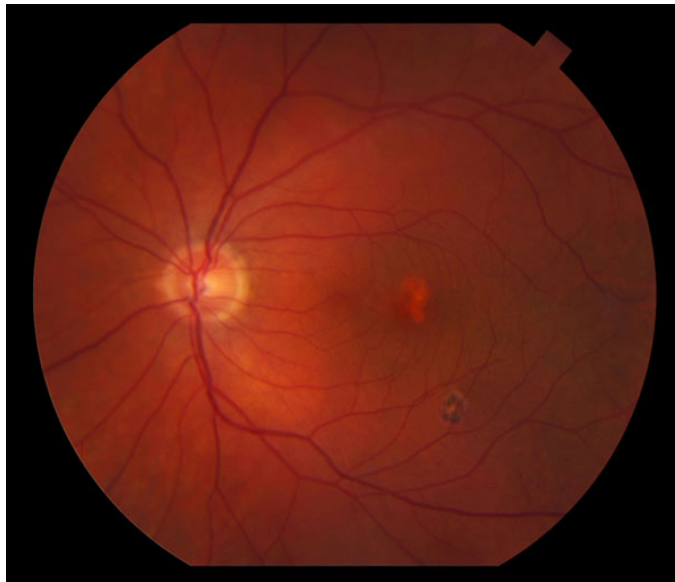
---

\* **Corresponding author Debra A. Goldstein:** Northwestern University, Chicago, Illinois, USA; Tel: (312) 9088152; Fax: (312) 5038152; Email: [debgold@yahoo.com](mailto:debgold@yahoo.com)

elevation, but localized disruption of the outer retinal layers and RPE, with sparing of the choroid and Bruch's membrane [4] (Figs. 3a and 3b).

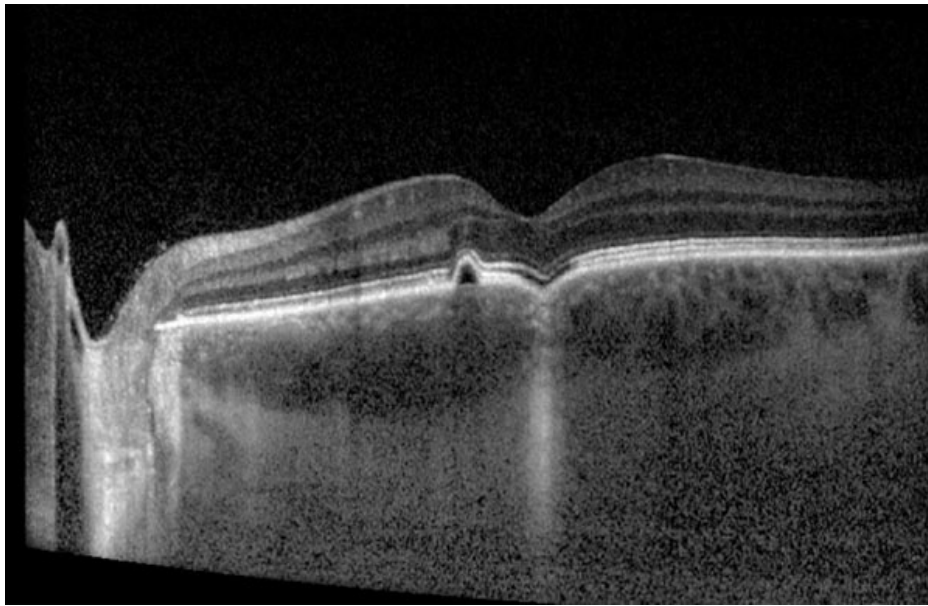


**Fig. (1).** Atrophic lesions in the macula of the right eye of a patient with MFC without inflammation/PIC. This patient developed multiple CNVM over time in both eyes, with no evidence of intraocular inflammation at any point. This is the type of presentation which is typically referred to as PIC, but may also be considered MFC without inflammation.

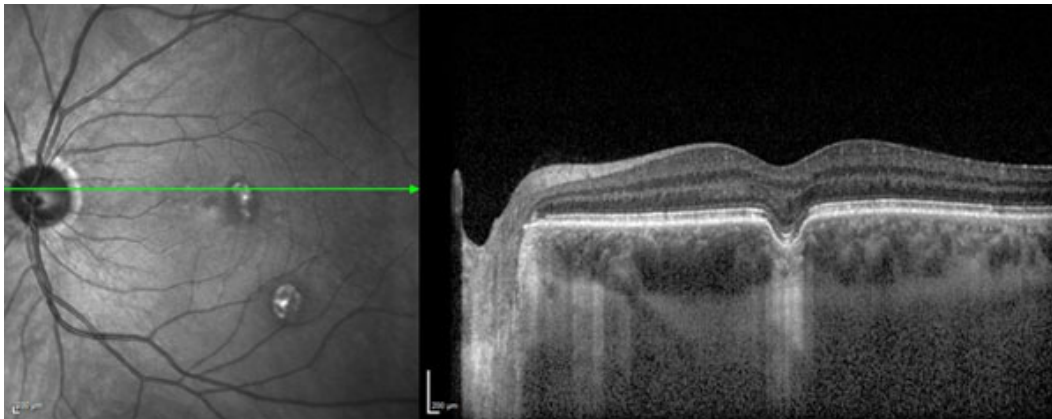


**Fig. (2).** Atrophic lesions in the macula of the left eye of a 39-year-old male with PIC. The patient had multiple bilateral atrophic spots in both fundi and developed multiple CNVM over time in both eyes, with no evidence of intraocular inflammation.





**Fig. (3a).** SD-OCT of the left eye of the patient in Fig. (2). Nasal to the fovea, a focal elevation of the RPE is seen with corresponding disruption of the overlying inner segment- outer segment layer (Ellipsoid layer, EZ). Adjacent OPL shows moderate reflectivity. No edema of surrounding retina is seen. Temporal to this hump, underlying the foveal contour, a V-shaped hernia of the OPL, ILM and disrupted EZ, into the inner choroidal layer is seen.



**Fig. (3b).** IR image of the left macula of the patient in Fig. (2), showing atrophic macular lesions in PIC. The SD-OCT scan of the sectioned lesion (green arrow) shows sub foveal V- shaped incarcerated hernia of the OPL and inner retina into the choroid. Loss of outer retina and RPE is seen in the V shaped depression.

## DIFFERENTIAL DIAGNOSIS

Ocular histoplasmosis syndrome (OHS) lesions may appear identical to PIC lesions, however OHS lesions are typically also present in the periphery, which is spared in PIC. Neither condition is associated with vitritis. Some authorities believe PIC to be a variant of MFC as these two different entities share many

## Birdshot Retinochoroidopathy

Ariel Schlaen\*

*Hospital Universitario Austral, Buenos Aires, Argentina*

### ESSENTIALS OF DIAGNOSIS

Birdshot retinochoroidopathy is a relatively rare autoimmune chronic posterior uveitis, which always has bilateral involvement [1]. Its progression is slow, but it can lead to a severe retinal dysfunction in spite of the fact that visual acuity may not be significantly altered [2, 3]. It is mainly characterized by the presence of multifocal, hypopigmented choroidal lesions with indistinct borders [1 - 5] (Figs. **1a-d, 2a-d, 3a-b, 4**). The latter have a spectrum of presentation, typically oval or round spots, but can be irregular in shape, or they can present a linear configuration. They are usually found around the optic disc, and frequently located in the inferior and nasal periphery [5]. However, they can be seen sometimes in other locations [1]. Anterior segment inflammation is mild or absent. There is no synechia formation. Vitritis is mild or moderate, although it is present in all cases. Retinal vasculitis is frequently observed, mostly as phlebitis [1, 4, 5]. Optic disc edema is also seen [1] (Figs. **1c-d, 3c-d**).

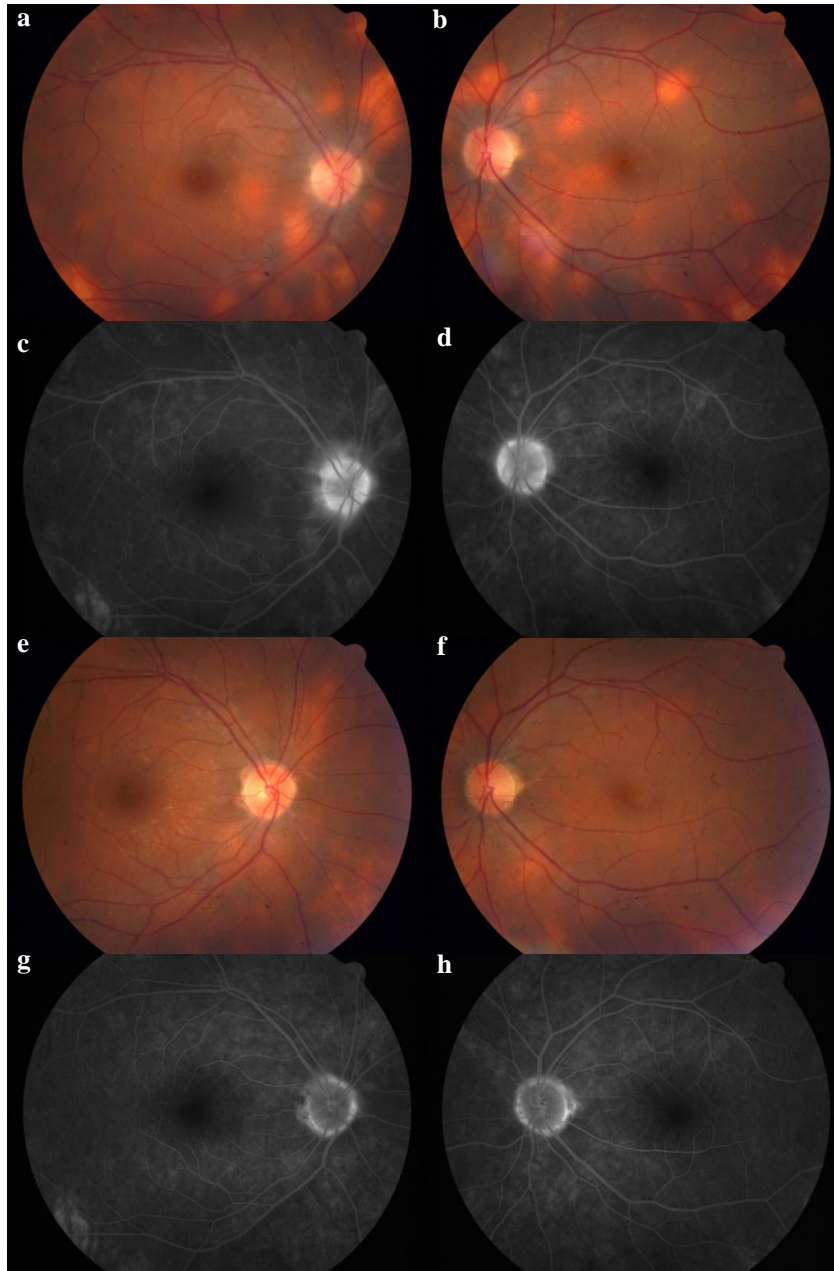
Related symptoms reported, besides visual acuity impairment, include the presence of blurred vision, floaters, color vision deficiency, poor contrast sensitivity, nyctalopia, glare, photopsia, photophobia, fluctuating vision, decreased peripheral vision, metamorphopsia, and loss of depth perception [1 - 4, 6].

The most frequent complication is macular edema, which is the most common cause of decreased visual acuity in patients with this ailment [7, 8]. Other complications described include optic atrophy [7, 9], epiretinal membrane [10], choroidal neovascular membrane [7, 9], and retinal neovascularization [7].

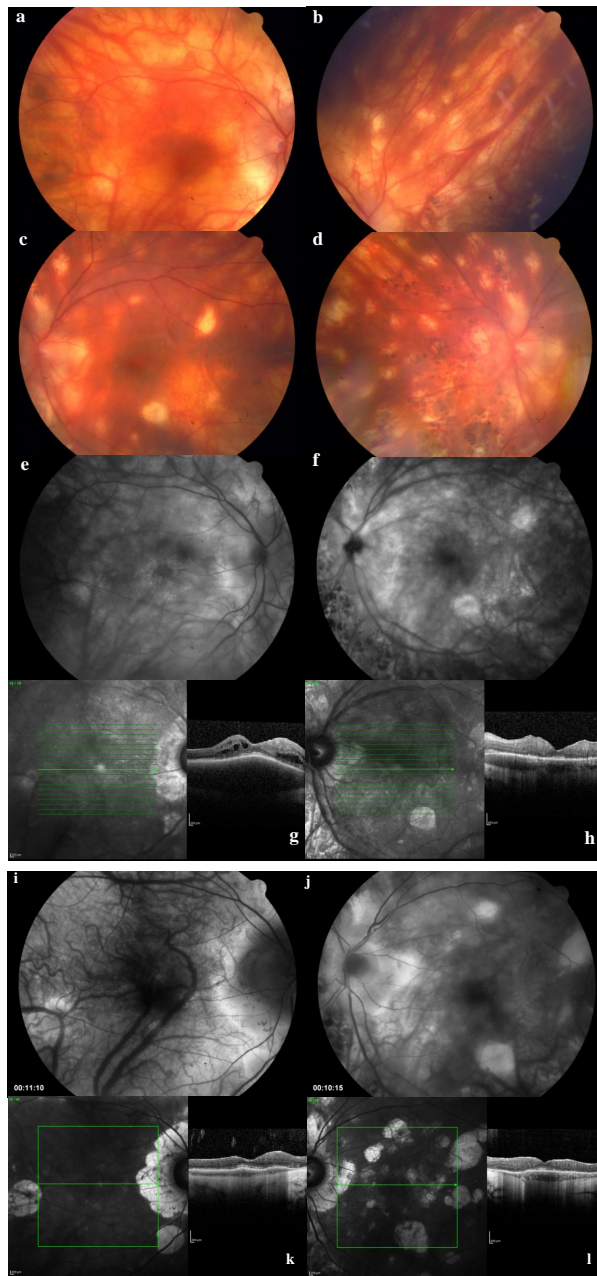
---

\* **Corresponding author Ariel Schlaen:** Hospital Universitario Austral, Arenales 981 2nd floor, Buenos Aires C1061AAE, Argentina; Tel/Fax: +5411 43284441; Email: ariel.schlaen@gmail.com





**Fig. (1).** 37-year-old female patient who complained about mild blurred vision in both eyes. Typical birdshot spots can be seen in both eyes at posterior pole (**a** and **b**) and periphery. Fluorescein angiography revealed the presence of hyperfluorescence of the optic disc in both eyes, without correlation between choroidal lesions and the angiographic features (**c** and **d**). She was treated with oral cyclosporine for 5 years, and her birdshot spots gradually disappeared (**e** and **f**). It can be noted that the hyperfluorescence of the optic disc in both eyes also disappeared due to the treatment (**g** and **h**).



**Fig. (2).** 48-year-old male patient who had been diagnosed with birdshot retinochoroidopathy 7 years ago. Choroidal lesions at posterior pole and periphery are more discrete, and some of them are mildly pigmented (a, b, c and d). Fluorescein angiography and OCT revealed the presence of macular edema in both eyes (e, f, g, and h). After one year of treatment with cyclosporine and periocular corticosteroids, macular edema was adequately controlled in both eyes, as it can be observed in fluorescein angiography and OCT (i, j, k, and l).

## Serpiginous Choroiditis

Rafael Cortez\*

*Centro de Cirugía Oftalmológica (CECOF), Caracas, Venezuela*

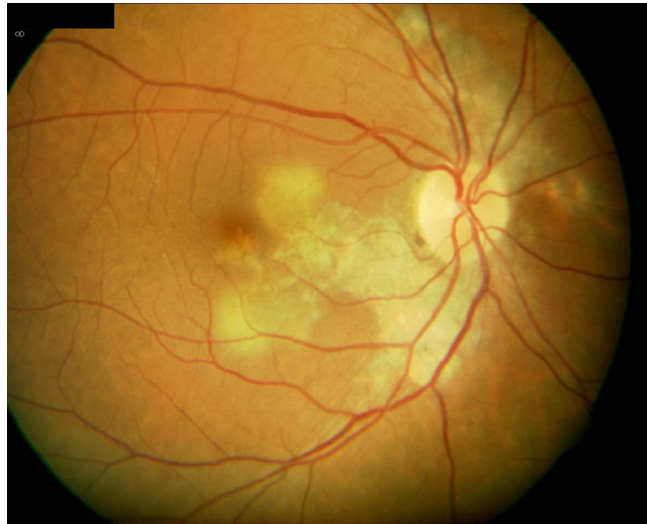
Serpiginous choroiditis (SC) is an acute and chronic inflammatory disease which is usually bilateral but may also be asymmetric. Its etiology is unknown. This rare, recurrent and multifocal disorder affects the inner choroid, the retinal pigment epithelium (RPE), and, secondarily, the retina. The average onset interval between the two eyes is about 5 years [3]. The disease is most often seen in otherwise healthy young to middle-aged individuals, and reports indicate that men have a higher prevalence than women [1, 4]. As per most uveitis epidemiological reports, SC constitutes less than 5% of cases of posterior uveitis [2, 6], except for one report from India, which found that 19% of their posterior uveitis cases correspond to SC [2, 5].

### ESSENTIALS OF DIAGNOSIS

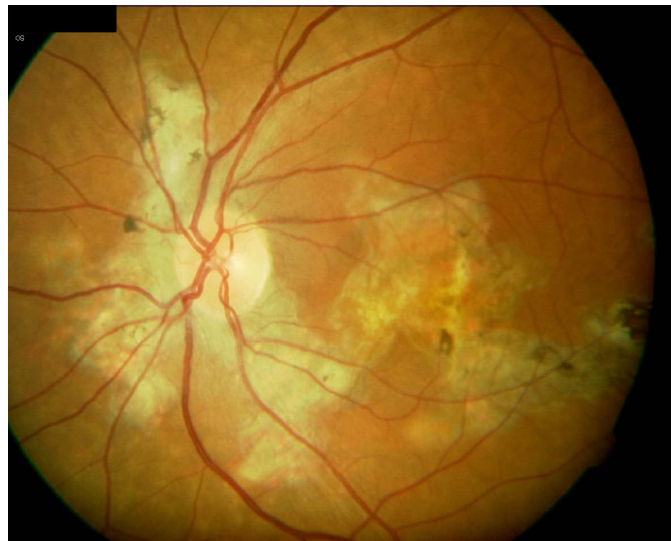
Patients present with painless, unilateral paracentral scotoma, metamorphopsia, or decreased vision. It typically extends from the peripapillary region, characterized by patches of gray-white inflammation in the retina and choroid, and spreads centrifugally, over a period of months or years, by means of recurrent episodes of patchy choroiditis in a serpiginous distribution outward from the optic disc to involve the macula and peripheral fundus [1, 2] (Fig. 1A and 1B). Far less commonly, macular (macular serpiginous choroiditis) or peripheral lesions in isolation, or in a multifocal pattern (atypical or ampiginous choroiditis), are observed [2, 6]. Acute lesions appear gray-white, or yellow, and involve the choriocapillaris and RPE [2]. Approximately one third of the patients present vitreous cellular inflammation during the active phase of the disease [1]. Over a period of weeks, the acute gray-white lesions, which may appear identical to those of the acute stage of acute posterior multifocal placoid pigment epitheliopathy (APMPPE), with or without treatment, are partially replaced by mottling and depigmentation of the RPE (Fig. 1E); the grayish-white appearance in the boundaries of the active lesion often remains for a month or longer [1]. Over a

\* Corresponding author Rafael Cortez: Centro de Cirugía Oftalmológica (CECOF), Caracas, Venezuela; Tel/Fax: +58 (212) 2852433; Email: rafaelcortezh@gmail.com

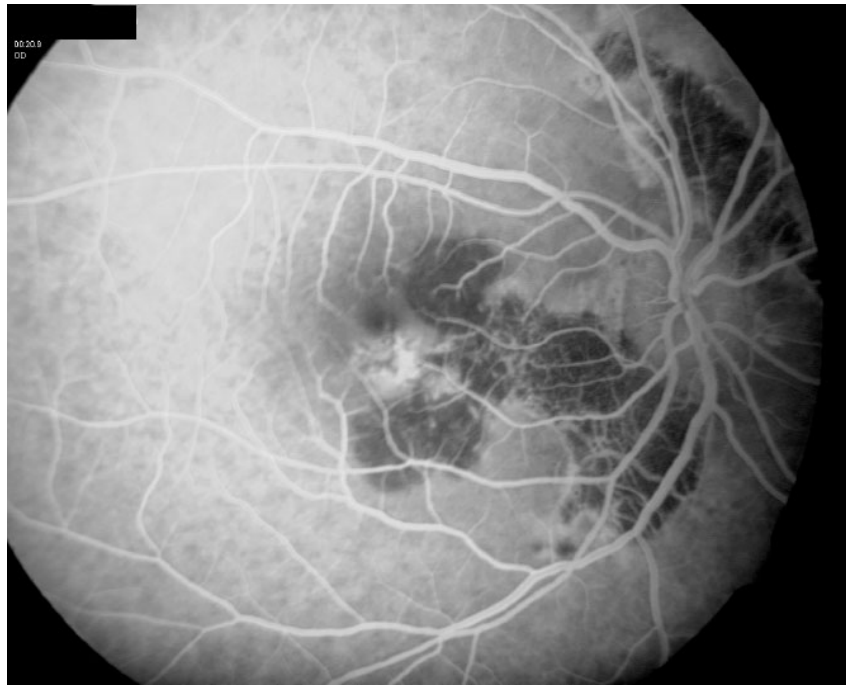
period of months, varying degrees of atrophy of the underlying choroid develop within the discrete zone of previous activity [2, 7]. Chorioretinal atrophy, subretinal fibrosis, and extensive areas of pigment clumping in the RPE may be described in chronic cases [1, 2, 7] (Fig. 3A and 3B). In about two thirds of patients with SC, one or both eyes present scarring in the initial stage [1, 2]. At intervals, varying from weeks to years, the patients are subject to recurring episodes of activity that involve a different area of the fundus each time, usually a contiguous one [1, 2].



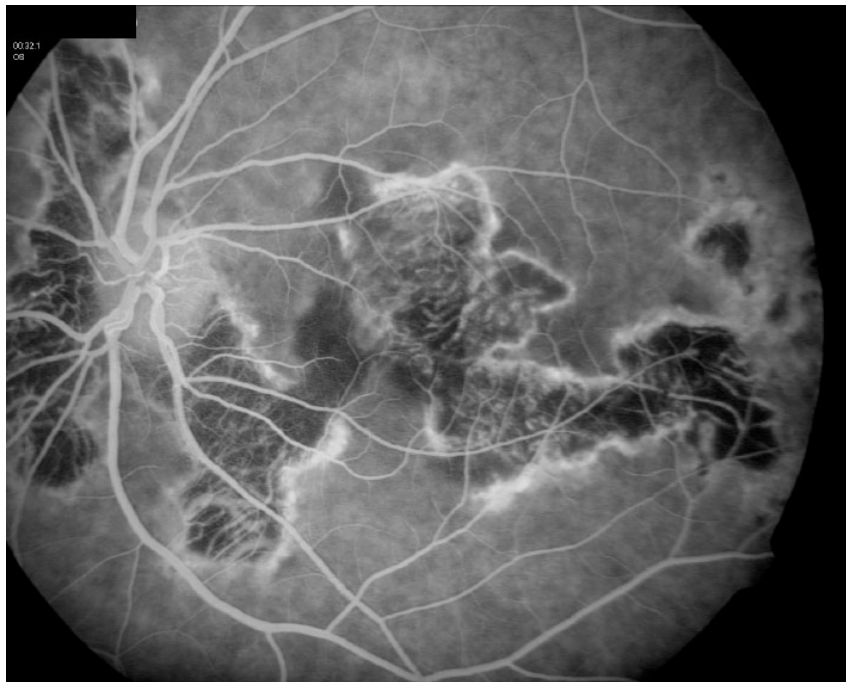
**Fig. (1A).** This 48-year-old woman had a history of paracentral scotoma in her right eye. Note the inactive scar in her right eye, and the yellow-white active lesions at the nasal border of the fovea.



**Fig. (1B).** Left eye shows the characteristic serpiginous extension of the inactive process from the disc.



**Fig. (1C).** The fluorescein shows that the active lesions seen in Fig. (1A) appear nonfluorescent.



**Fig. (1D).** Left eye: Failure of the atrophic areas to fluoresce. As fluorescein diffuses from the neighboring choriocapillaris, the atrophic areas show progressive staining from the margin centrally.

## **Diffuse Subretinal Fibrosis Syndrome**

**Andrée Henaine-Berra**

*Hospital General "Dr. Manuel Gea González", Mexico City, Mexico*

Diffuse subretinal fibrosis syndrome (also known as subretinal fibrosis and uveitis syndrome) is a rare entity that occurs primarily in young female patients. It is characterized by permanent visual loss due to multifocal choroiditis and progressive areas of subretinal fibrosis. In 1984, Palestine and associates described three young women with vitreous inflammation, multifocal progressive fibrotic subretinal lesions, cystoid macular edema, electroretinogram and electro-oculogram changes [1]. In 1996, Gass and colleagues described the clinical and histopathological findings in four eyes of three elderly patients with multifocal choroiditis and massive subretinal fibrosis [2].

### **ESSENTIALS OF DIAGNOSIS**

Usually the presentation is bilateral, but asymmetrical. In most of the patients, the initial symptoms are unilateral visual loss, floaters, metamorphopsias and photopsia [3]. The clinical findings consist in numerous small yellow choroidal lesions in the posterior pole which may extend out to the mid peripheral retina. Within days or weeks, turbid subretinal fluid begins to accumulate around the lesions causing a retinal detachment [3, 4]. The choroidal lesions coalesce creating areas of subretinal fibrosis (Figs. 1 and 2). Mild to moderate anterior chamber reaction and/or vitreous cells are typically present. In some cases there may be cystoid macular edema or choroidal neovascularization. The manifestations in the second eye can be observed in the following months. Recurrent episodes of inflammation can occur [4, 5].

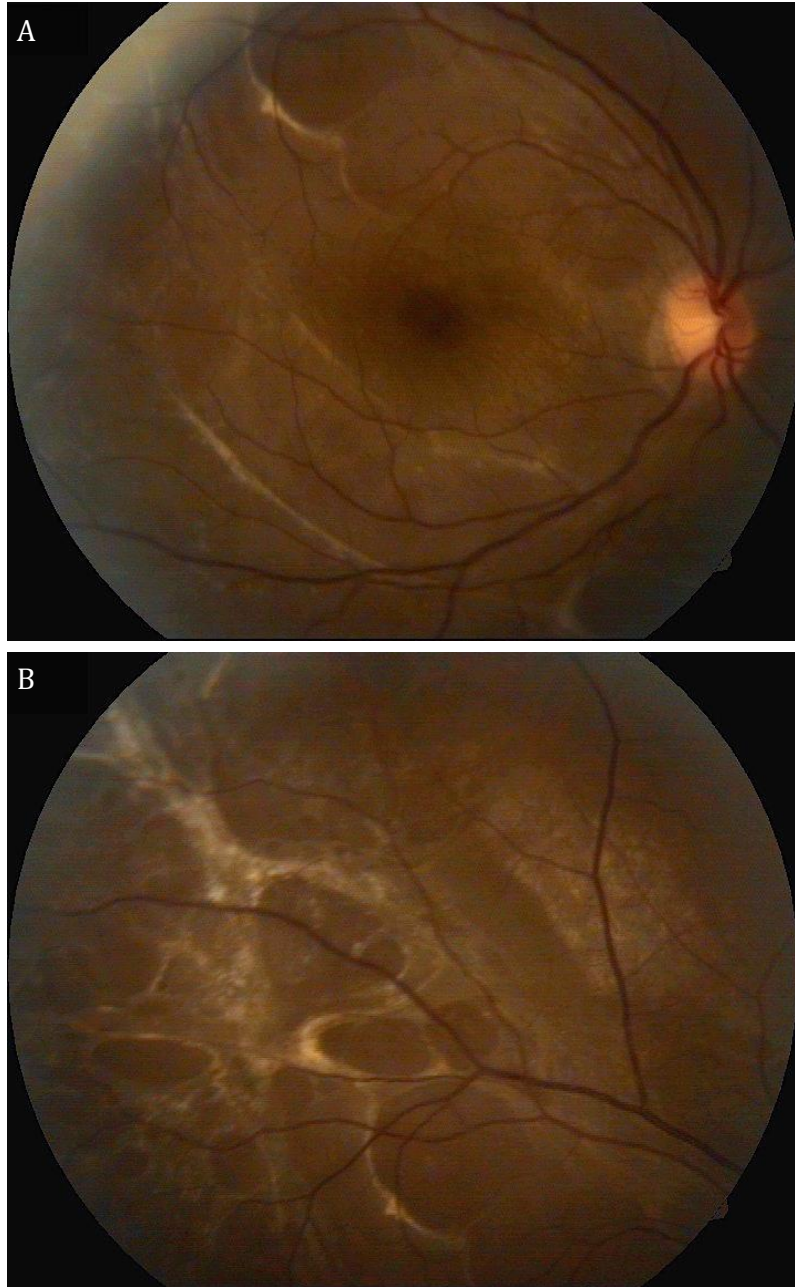
The underlying cause of the disease remains unknown; however, histopathologic examination shows that immune mechanism may play a role in the pathogenesis of the disease, suggested by the presence of local antibodies against the retinal pigment epithelium [6]. Gass *et al.* [2] showed degeneration of the outer retina and retinal pigment epithelium, fibrous tissue proliferation between the retina and

---

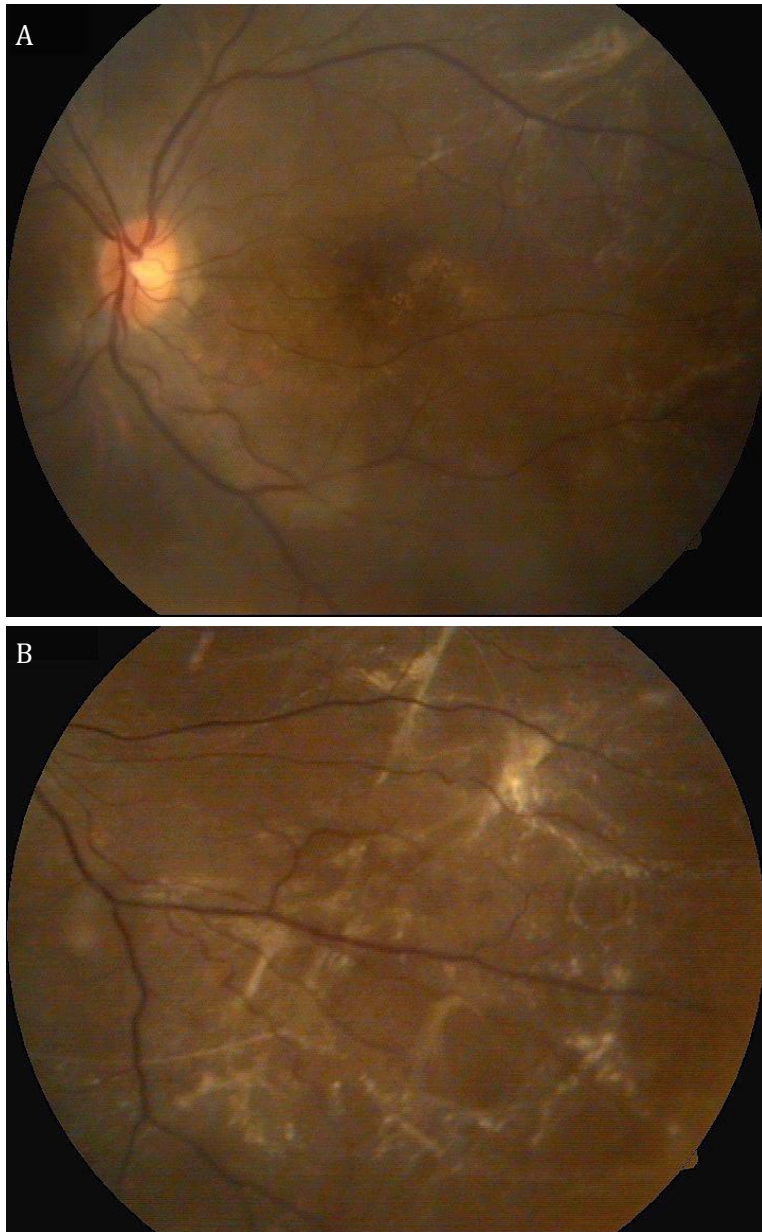
\* **Corresponding author** **Andrée Henaine-Berra**: Hospital General "Dr. Manuel Gea González", Mexico City, Mexico; Tel/Fax: +52(55)96886525; Email: andreehenaine@gmail.com



Bruch's membrane, and granulomatous inflammation.



**Fig. (1).** Fundus photographs of the right eye of a 22-year-old female patient. Image **a** shows lines of subretinal fibrosis in the macular area. Image **b** shows the superior temporal quadrant with marked subretinal fibrotic tissue.



**Fig. (2).** Fundus photographs of the left eye of a 22-year-old female patient (same patient as Fig. (1)). Images **a** and **b** show marked subretinal fibrotic tissue in the macular area and in the temporal mid-periphery, respectively.

During the active phase, fluorescein angiography shows early hypofluorescence followed by late leakage in choroidal lesions. Leakage could be due to inflammation or the presence of choroidal neovascularization. The areas of subretinal fibrosis show late staining [3] (Fig. 3).



## Diffuse Unilateral Subacute Neuroretinitis

**Antonio Marcelo B. Casella\*** and **Rodrigo F. Berbel**

*Universidade Estadual de Londrina, Rodovia Celso Garcia Cid, Km 380, s/n - Campus Universitario, Londrina - PR, 86057-970, Brazil*

Diffuse Unilateral Subacute Neuroretinitis mainly affects children and young adults. Brazil, Latin America, southeastern and mid-western United States are endemic areas. There are also case reports from South Africa, China, and India [1-3].

In 1983, Gass defined the disease as a syndrome caused by a retinal nematode, though the etiological agent has remained uncertain. At least two agents have been described and classified according to the size of the larva and the endemic area of the disease: *Ancylostoma caninum*, the smaller agent, measuring about 400-1000 micrometers, most likely in the third larval stage is the most prevalent in Latin America and southern United States; *Baylisascaris procyonis*, between 1,500 and 2,000 micrometers, prevails in northern and midwestern United States and usually infests the raccoon and opossum. Other hypothesized causes of the disease have been *Toxocara canis* and a trematode, *Alaria mesocercaria*, coming from contaminated frog meat [4].

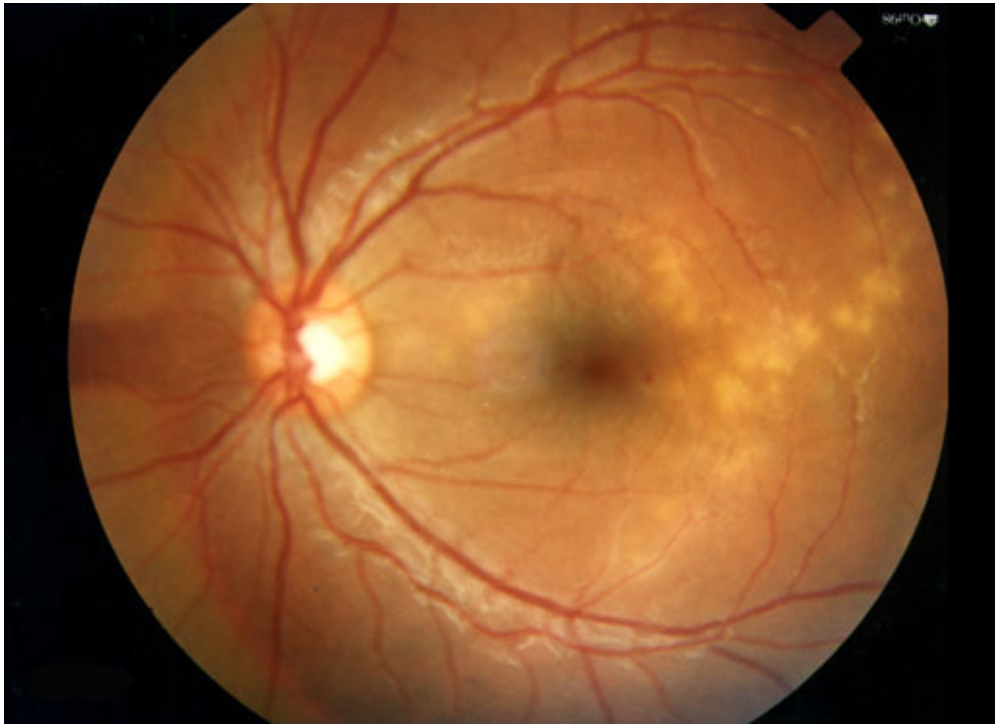### ESSENTIALS OF DIAGNOSIS

In its initial stage, the disease is characterized by vision loss, usually unilateral, vitritis, papillitis, retinal vasculitis, and grayish-white evanescent lesions in the outer retina (Fig. 1). In the late stage, it shows progression of vision loss, optic atrophy, narrowing vascular and diffuse changes in the retinal pigment epithelium (Fig. 2), which may occur months or years after disease onset. The pathophysiology of the syndrome is related to two effects: a local toxic effect in the outer retina caused by products released by the worm, and also by a diffuse toxic reaction affecting both the outer and inner retina. This first effect would be related to the gray-white lesions and the second, to the loss of visual function and

---

\* **Corresponding author Antonio Marcelo B. Casella:** Universidade Estadual de Londrina, Rodovia Celso Garcia Cid, Km 380, s/n - Campus Universitario, Londrina - PR, 86057-970, Brazil; Tel/Fax: +55(433) 324-1177; Email: mbcasella@gmail.com

alterations diagnosed on electroretinography, loss of retinal ganglion cells, and vascular narrowing.

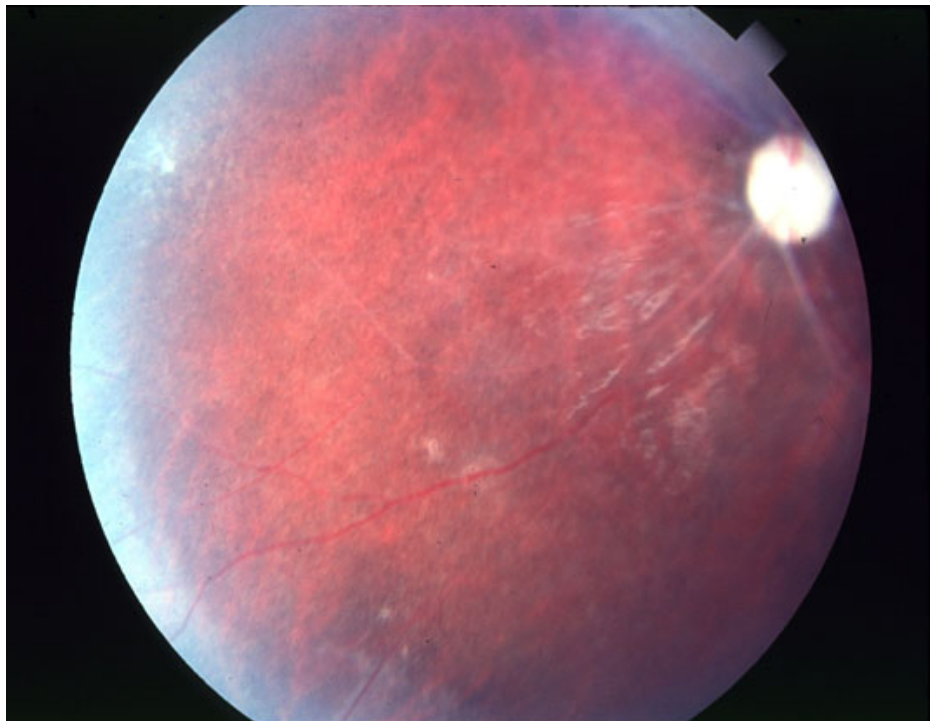


**Fig. (1).** Example of a case in the acute phase with active retinal lesions.

With the evolution of the disease, involvement of the retinal pigment epithelium as well as vascular narrowing increases. Some cases may progress to choroidal neovascularization and subretinal fibrosis [1 - 5].

The diagnosis is made by identification of a mobile larva in the retina, a pathognomonic finding in fundus examination. The nematode usually appears in the shape of an “S”, due to its motion, where it moves by coiling and uncoiling. The most likely place to find it is close to the retinal areas with the greatest amount of white lesions. The agent is usually identified in less than 50% of cases because of the nematode’s characteristic retinal location, which may be confused with reflexes of the retina itself, and the difficulty in examining some patients, especially children. Increased vitreous cellularity is found in all patients, but the amount is associated with the stage of disease. Relative afferent pupillary defect (Marcus Gunn pupil) is also found in virtually all cases. Some patients may have ciliary injection, cellular reaction in the anterior chamber, flare, keratic precipitates, and hypopyon. Atypical presentations have been described, with

serous retinal detachment or areas of hemorrhage and retinal exudation [6, 7]. In fluorescein angiography, the early stages of the disease usually show hyperfluorescence by contrast extravasation from the capillaries in the optic nerve and early hypofluorescence in gray-white lesions, which, in the later stages of the examination, acquire a slight coloration. There may be a large leak of perivenous contrast in the early stages of the disease, as well as some evidence of change in the retinal pigment epithelium. With the evolution of the disease and the progressive loss of pigmentation in the retinal pigment epithelium, the angiographic manifestations appear as increased choroidal fluorescence by transmission. The electroretinogram shows changes in almost all patients, with the B-wave being more affected than the A-wave, usually with subnormal findings or even rarely an extinct electroretinogram. Optical coherence tomography (OCT) identifies the diffuse atrophy of the nerve fiber layer and focal edema in the area affected by the parasite. From retinal fundus images, it is postulated that the causative agent of the disease is located in the subretinal space, but through OCT, the worm has been described in additional topographies such as the intraretinal or even premacular space [2, 5 - 10].



**Fig. (2).** Example of a case in the chronic phase, with vascular narrowing, degeneration of the RPE and optic nerve pallor.

## **Vogt Koyanagi Harada Disease**

**Lourdes Arellanes\***

*Uveitis Department, Asociación para evitar la Ceguera, Hospital Dr. Luis Sánchez Bulnes IAP, Mexico City, Mexico*

### **ESSENTIALS OF DIAGNOSIS**

Vogt Koyanagi Harada Disease (VKH) is an acute bilateral, granulomatous panuveitis that presents typically with an exudative retinal detachment and variable association with extraocular manifestations. It is common in pigmented populations, and certain ethnic groups have a genetic predisposition to develop it. Most authors have reported that it more frequently affects female patients (ratio 2-3:1), age range 4-73 years. Typically three different stages have been described: prodromal, acute uveitic, and convalescent [1].

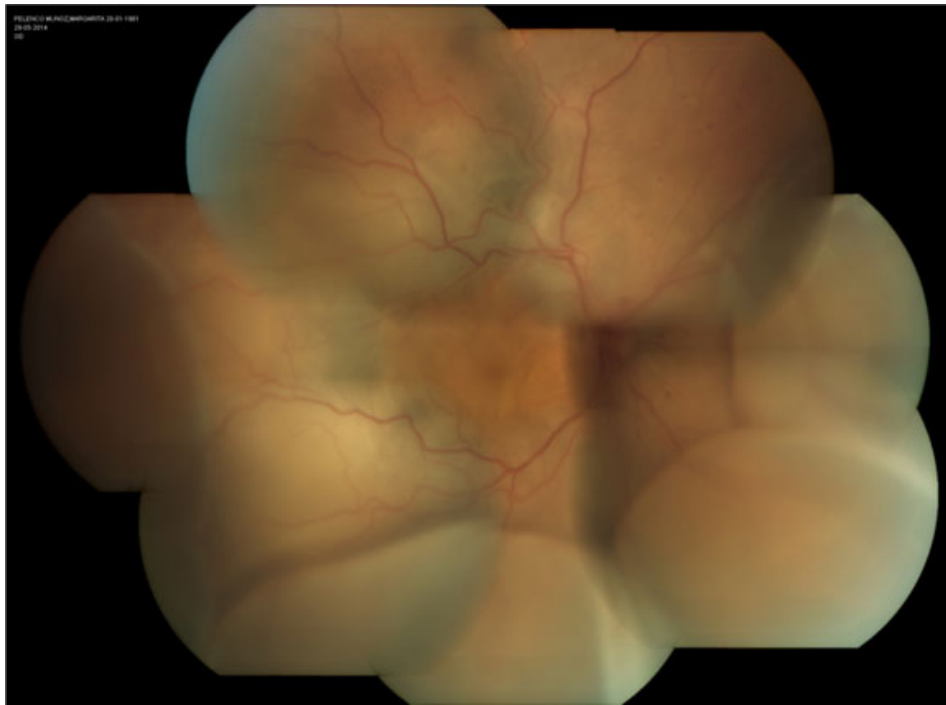The prodromal stage is characterized by symptoms similar to those of aseptic meningitis, like neck stiffness and headache; in addition, sensitivity of the hair and skin can be observed. Less frequently, focal neurologic signs have been reported. Deafness and tinnitus may also be present.

In the acute uveitic stage the patient may refer bilateral redness, photophobia, and blurred vision; in some patients a delay of 2 to 4 days between the first and the second eye can be found. In the early stage, the characteristic lesion is a diffuse choroiditis that may be observed clinically as subretinal fluid or serous retinal detachment (Fig. 1). Other clinical findings are anterior uveitis, optic disc hyperemia, and mild vitreous haze.

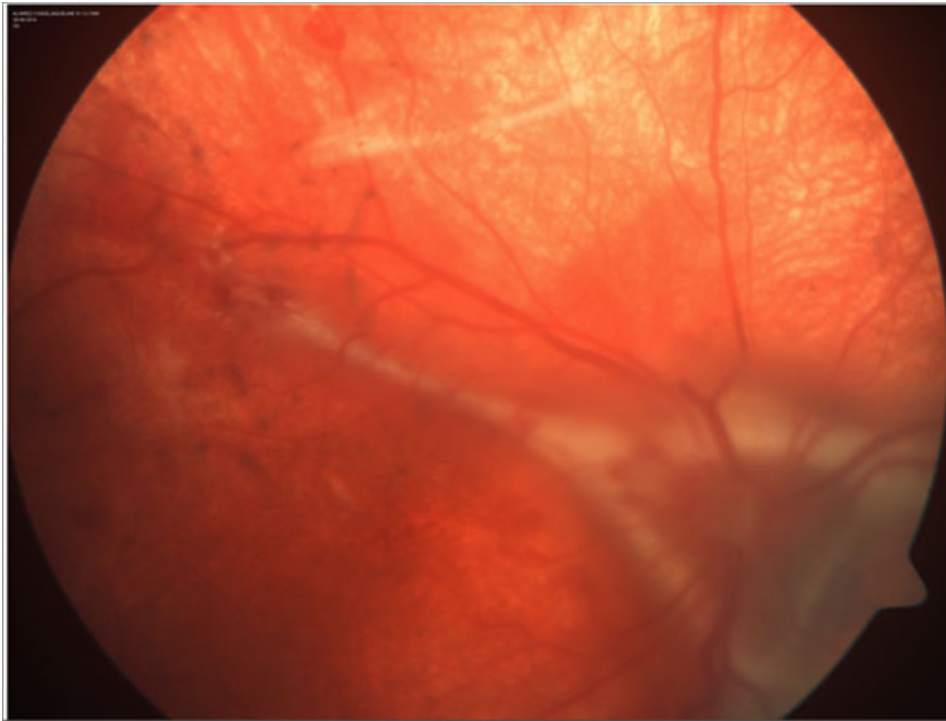
The convalescent stage is characterized by depigmentation; alopecia, poliosis and vitiligo may also be observed (Fig. 6). Vitiligo can be found in the head, eyelids, and trunk, particularly on the sacrum (Fig. 5). A sunset-glow fundus appearance is frequently observed (Fig. 2). Multiple depigmented, small, round areas of chorioretinal atrophy can be found in the mid-periphery (Fig. 3).

---

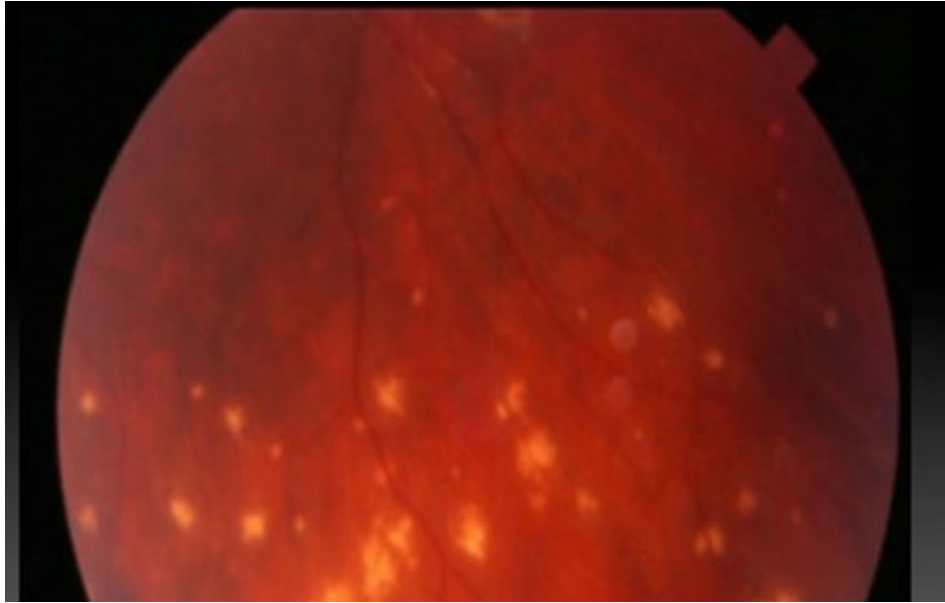
\* **Corresponding author Lourdes Arellanes:** Uveitis Service, Asociación para Evitar Ceguera, Hospital Luis Sanchez Bulnes IAP, Mexico City, Mexico; Tel/Fax: +52(55)10841400; Email: lourdes.arellanes@apec.com.mx



**Fig. (1).** Bullous serous retinal detachment. Acute uveitic stage.

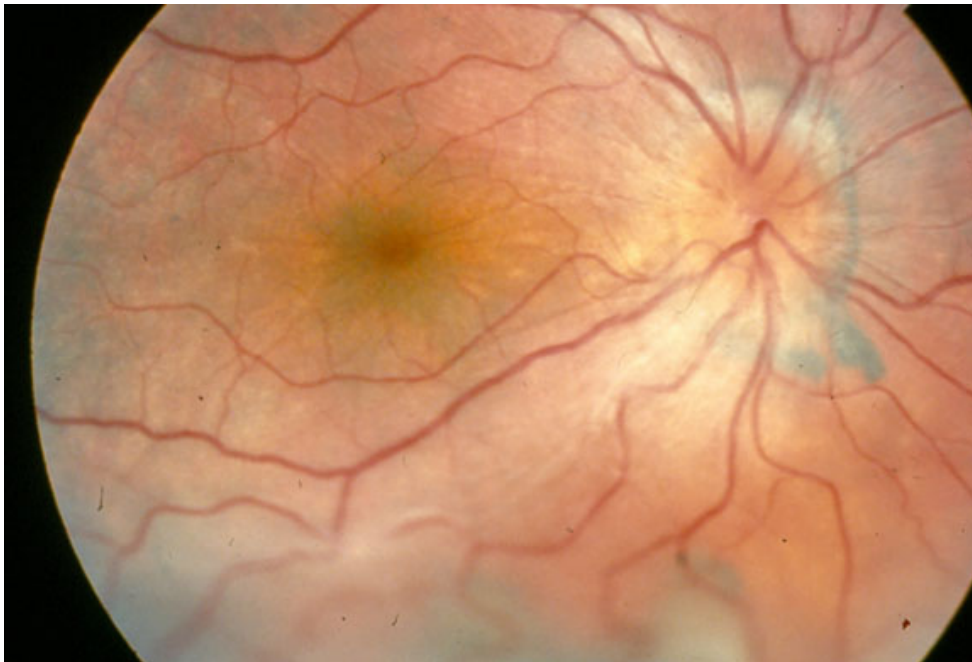

**Fig. (2).** “Sunset glow fundus”, subretinal and peri-papillary fibrosis. Convalescent stage.



**Fig. (3).** Nummular lesions. Convalescent stage.

Some patients, particularly the undertreated ones, may go into the chronic–recurrent phase (Fig. 4), which is characterized by a smoldering panuveitis with a recurrent anterior granulomatous uveitis and focal choroiditis.



**Fig. (4).** Pigment migration and serous retinal detachment. Chronic stage.

## **Pars Planitis**

**Gerardo García-Aguirre<sup>\*1</sup> and José Antonio Unzueta-Medina<sup>2</sup>**

<sup>1</sup> *Retina Department, Asociación para Evitar la Ceguera en México, and School of Medicine, Instituto Tecnológico y de Estudios Superiores de Monterrey, Mexico*

<sup>2</sup> *Ophthalmology Department, Hospital Angeles Chihuahua, Chihuahua, Mexico*

Pars planitis is a type of intermediate uveitis of unknown etiology that tends to affect children and young adults. The term “intermediate uveitis” indicates that the main site of inflammation resides in the pars plana, peripheral retina and the vitreous base [1, 2].

### **ESSENTIALS OF DIAGNOSIS**

Pars planitis mainly affects patients in the first and second decades of life. It may be completely asymptomatic, since external signs of inflammation are rare, and manifest late in the course of the disease when there is strabismus or lack of a red reflex.

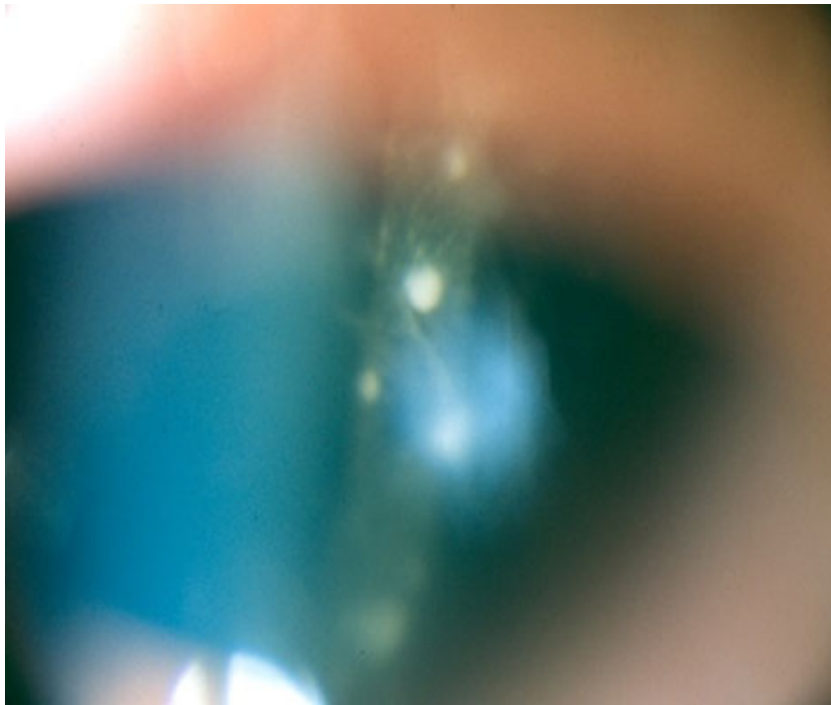The main manifestations of this disease occur in the vitreous, where inflammatory cells are observed. These cells tend to coalesce and form white roundish opacities that float in the anterior vitreous, called “snowballs” because of their characteristic appearance (Figs. 1 and 2). Snowballs may also merge into whitish plaques that lie over the retina called “snow banks”, which are more frequently (but not always) found inferiorly [3]. Snow banks may eventually undergo fibrotic transformation, originating a cyclitic membrane, which is usually pretty adherent to the inferior peripheral retina, pars plana and posterior capsule.

Pars planitis may also affect the anterior segment. Cells, flare and posterior synechiae may be present. Band keratopathy and autoimmune epitheliopathy may also be observed in more advanced and chronic cases [1 - 5].

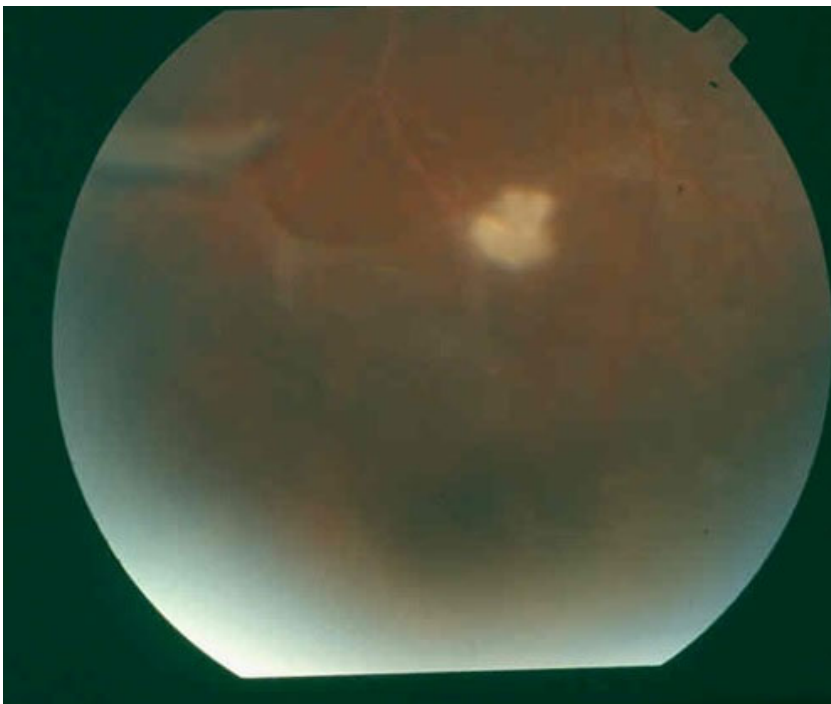
---

<sup>\*</sup> **Corresponding author Gerardo García-Aguirre:** Asociación para Evitar la Ceguera en México, Vicente García Torres 46, San Lucas Coyoacan, Ciudad de México, México, 04030; Email: jerry\_gar\_md@yahoo.com



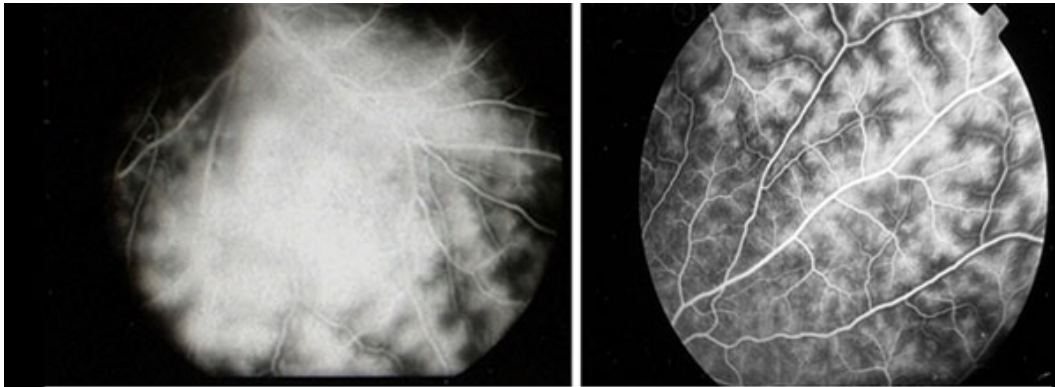


**Fig. (1).** Snowballs: floating, globular and yellow-white conglomerates of inflammatory cells in the anterior vitreous.

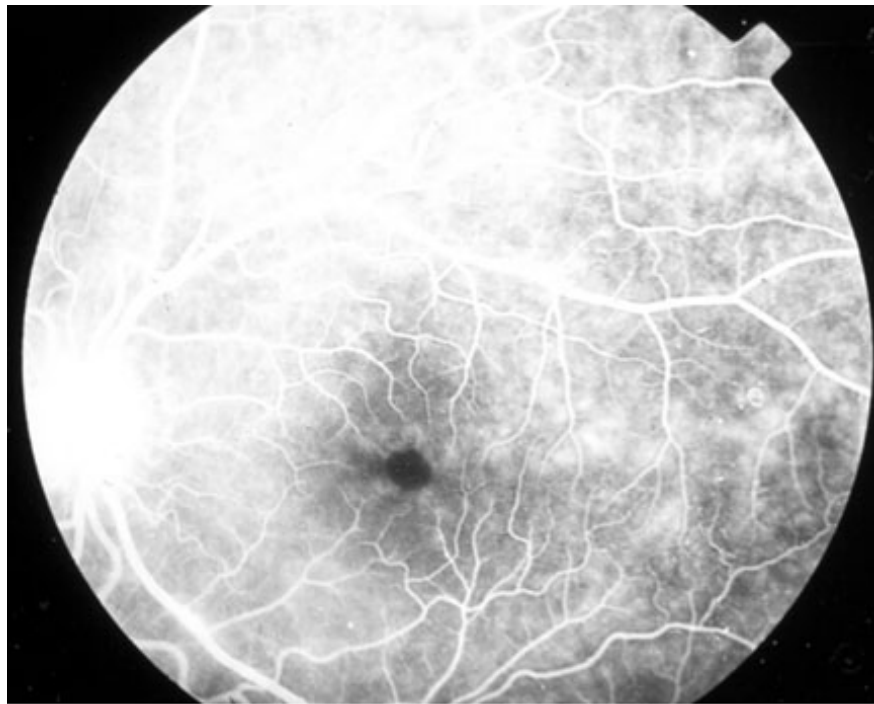


**Fig. (2).** Snowball located in the inferior vitreous cavity.

Fluorescein angiography is a very useful diagnostic tool for this disease. Perivascular hyperfluorescence in a “fern” pattern is very characteristic of pars planitis (Fig. 3). Optic disc hyperfluorescence and cystoid macular edema may also be present [1, 6]. Cystoid macular edema, observed in 44% to 63% of eyes, is the main cause of visual loss in these patients, and can readily be diagnosed using fluorescein angiography (Fig. 4) and optical coherence tomography (Fig. 4) [1, 3, 6].



**Fig. (3).** Retinal fluorescein angiography showing retinal vasculitis in a characteristic “fern” pattern.



**Fig. (4).** Retinal fluorescein angiography showing perifoveal hyperfluorescence compatible with cystoid macular edema, hyperfluorescence of the optic disc and perivascular hyperfluorescence due to vasculitis.

## Sarcoidosis

Veronica Kon Graversen\*

Ophthalmology Department, University of North Carolina at Chapel Hill, NC, USA

Sarcoidosis is a multisystem disease of unknown etiology, characterized by a chronic inflammatory process leading to formation of noncaseating granulomas [1]. Ocular sarcoidosis can precede systemic involvement in 9% of the cases [2], and 10-90% of patients will have ocular compromise during the course of the disease [3]. The most common ophthalmological manifestation is uveitis [4].

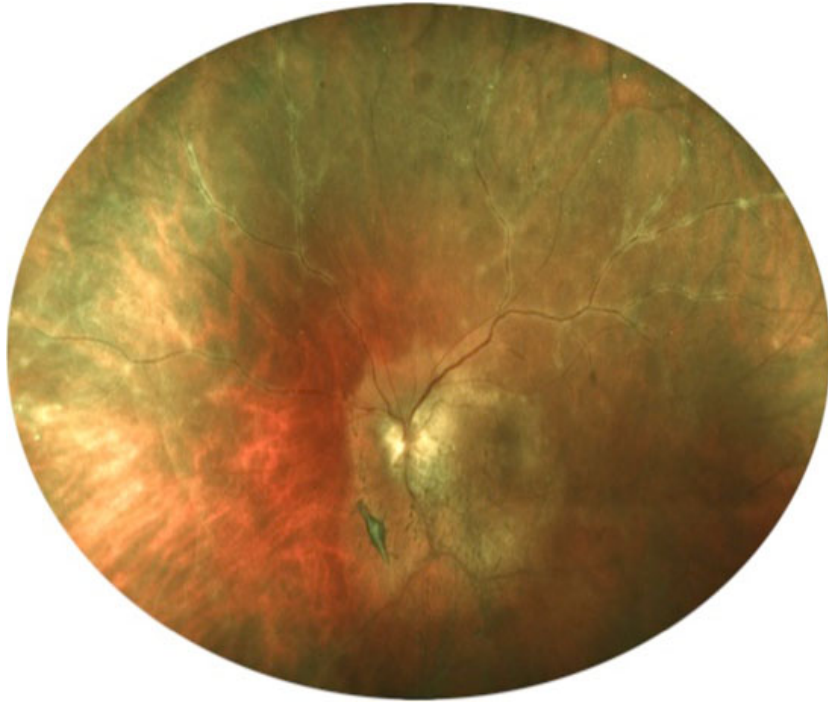
### ESSENTIALS OF DIAGNOSIS

*Clinical features:* A wide range of pathology including anterior, intermediate, posterior uveitis or panuveitis can be seen. Posterior uveitis occurs in 20-25% of patients. The clinical presentation is usually bilateral and insidious, with mild to severe inflammation. Iridocyclitis with mutton-fat keratic precipitates, iris nodules and posterior or peripheral synechiae are commonly described. Snowball-like opacities described as “string of pearls” are observed in inferior periphery. Optic nerve edema or infiltration have been reported in few cases. Retinal periphlebitis is the hallmark of sarcoidosis, producing the so-called “candle-wax drippings” [5]. This appearance is secondary to dense aggregates of mononuclear cells (Fig. 1). Periphlebitis is usually nonocclusive. However, cases of severe vasculitis with vascular occlusions and retinal ischemia have been reported. These findings may lead to peripheral retinal neovascularization, vitreous hemorrhage and rarely, retinal detachment [6]. Punch-out peripheral chorioretinal lesions can also be seen (Fig. 2). Cystoid macular edema may occur in the setting of chronic inflammatory changes. Choroidal neovascular membranes (CNV), posterior scleritis and sarcoid granulomas of the choroid are less frequent complications [7, 8].

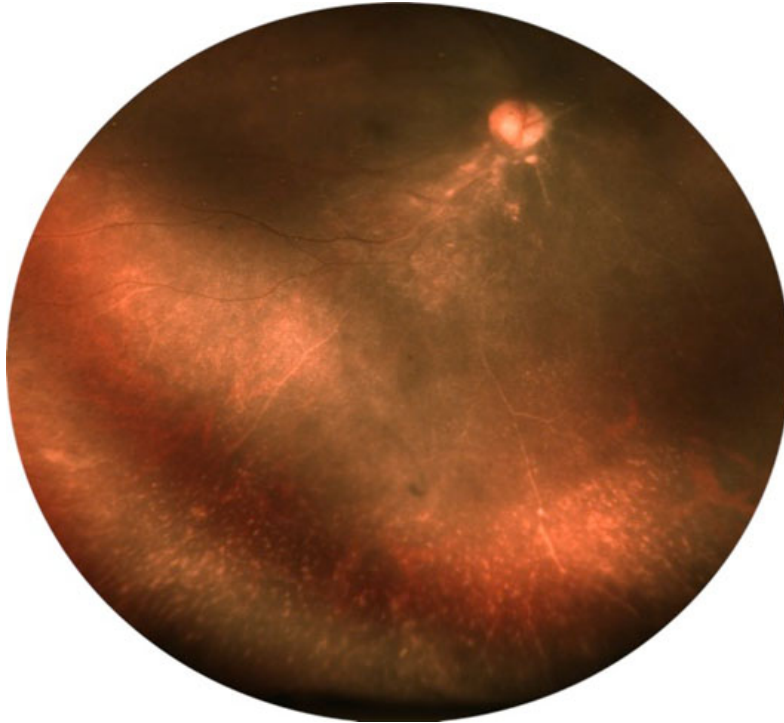
*Imaging:* Retinal diagnostic imaging is helpful in challenging cases. Optical coherence tomography is useful to monitor macular changes, and fluorescein angiography will detect early complications. Segmental staining of the venous wall is a classic finding (Fig. 3).

---

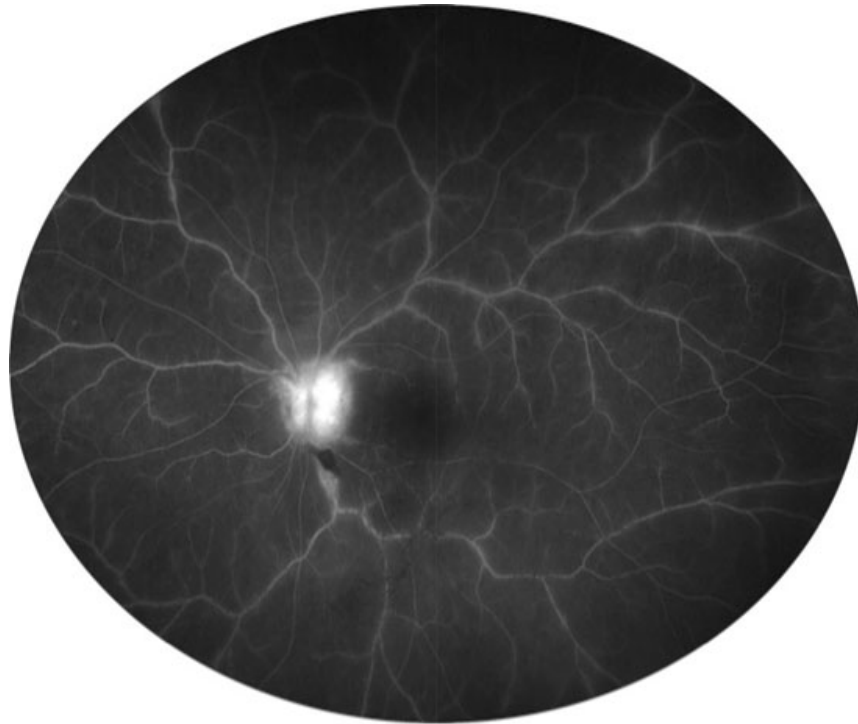\* Corresponding author Veronica Kon Graversen: Ophthalmology Department, University of North Carolina at Chapel Hill, NC, USA; Tel/Fax: (919)518-6361; Email: veronicakonjara@gmail.com



**Fig. (1).** Disc edema and periphlebitis on presentation.



**Fig. (2).** Peripheral hypopigmented chorioretinal lesions in a case of sarcoid.



**Fig. (3).** Fluorescein angiogram showing segmental staining of venous wall and hyperfluorescence of the disc.

*Other tests:* **Angiotensin converting enzyme** levels can be elevated in 60-90% of patients with sarcoidosis, but a normal result doesn't exclude the diagnosis. **Lysozyme** levels are likely to increase in patients with active disease. **Chest radiograph** may show hilar adenopathy. If significant clinical suspicion with negative test results, a CT scan of the chest and/or gallium scan can be requested; however, definite diagnosis requires a biopsy showing noncaseating granulomas.

#### **DIFFERENTIAL DIAGNOSIS (*POSTERIOR UVEITIS*)**

1. Toxoplasmosis
2. Toxocariasis
3. Vogt-Koyanagi-Harada syndrome
4. Intraocular lymphoma
5. Behcet's disease
6. Whipple's disease
7. Birdshot retinochoroidopathy
8. HIV paraviral syndrome
9. Eales disease
10. Multiple sclerosis

## Retinoblastoma

María Ana Martínez-Castellanos<sup>1,\*</sup>

<sup>1</sup> Retina Service, Asociación para Evitar la Ceguera en México, Hospital Luis Sanchez Bulnes IAP, Mexico City, Mexico

Retinoblastoma is the most frequent malignant intraocular tumor in childhood, and one of the most frequent malignant tumors overall at this age. Around 8000 new cases occur annually worldwide [1], and most of them in the first 8 years of life. The importance of early diagnosis lies in the fact that it is almost always fatal without a timely treatment.

### ESSENTIALS OF DIAGNOSIS

Although leukocoria is the classic symptom, when leukocoria is observed the tumor is usually in a late stage. Ideally, diagnosis must be made when the tumor is small, which needs a dilated funduscopy performed by a trained ophthalmologist. Retinoblastomas usually appear as whitish tumors that may grow towards the vitreous cavity (endophytic) or to the subretinal space (exophytic), or may seed into the vitreous. Rare presentations include seeding of the anterior chamber and an endophthalmitis-like picture [2 - 4].

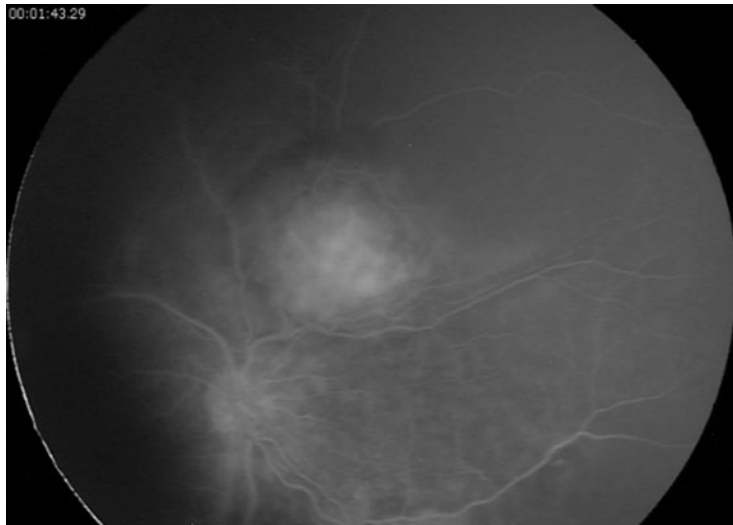
B-scan ultrasound shows a hyper-reflective mass, with foci of higher hyper-reflectivity corresponding to calcification, and orbital shadowing behind the mass. Computed tomography shows an intraocular tumor with calcifications.

The severity of the disease is divided in different stages according to the International Classification of Retinoblastoma [5]:

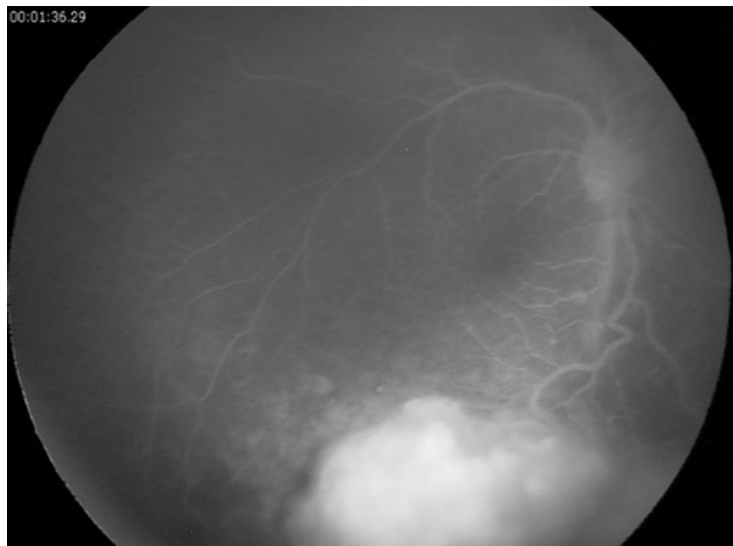
1. Group A (Fig. 1): Small tumors ( $\leq 3$  mm), confined to the retina,  $>3$  mm from the fovea,  $>1.5$  mm of the optic disc.
2. Group B (Fig. 2): Larger tumors ( $>3$  mm) confined to the retina, in any location, with clear subretinal fluid  $\leq 6$  mm from the tumor margin.

---

\* Corresponding author María Ana Martínez-Castellanos: Retina Service, Asociación para Evitar la Ceguera en México, Hospital Luis Sanchez Bulnes IAP, Mexico City, Mexico; Tel/Fax: +52(55)10841400; Email: mariamtzc@me.com



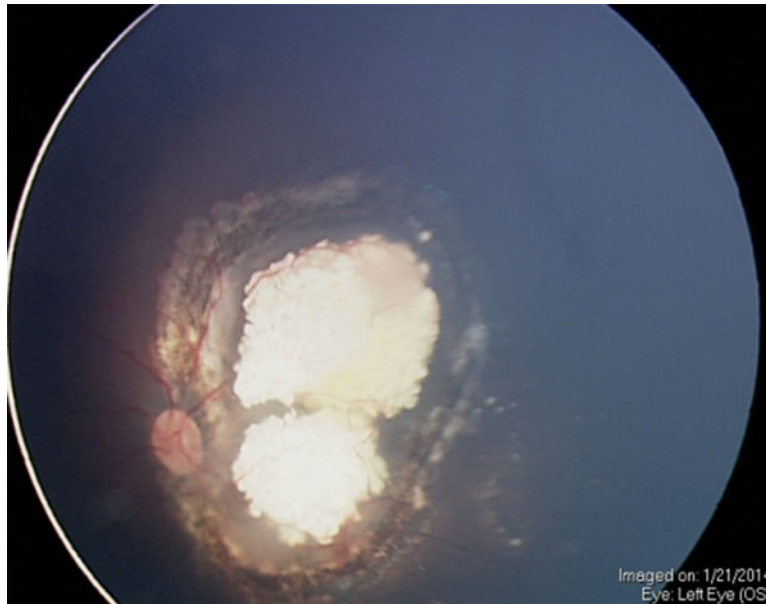
**Fig. (1).** Fluorescein angiogram showing a hyperfluorescent mass superonasal to the optic disc classified as Group A.



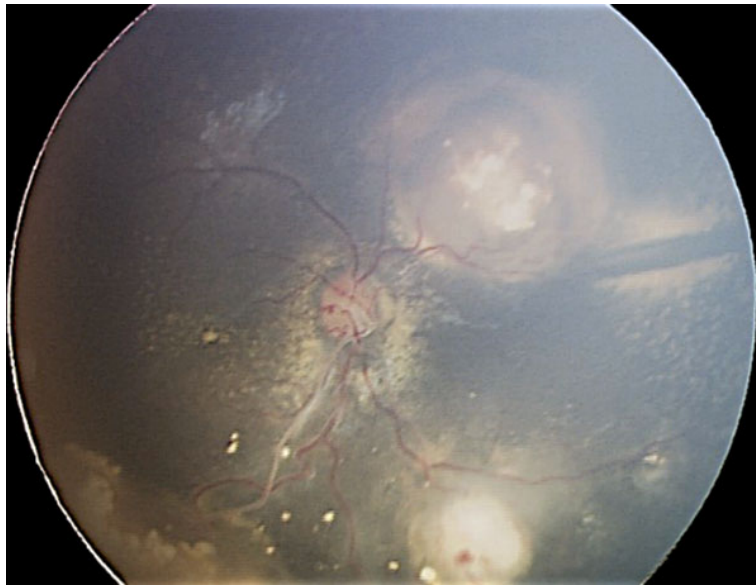
**Fig. (2).** Fluorescein angiogram showing a large (>3 mm) hyperfluorescent mass in the inferior retina, classified as Group B retinoblastoma.

3. Group C (Fig. 3): Localized vitreous and/or subretinal seeding (<6 mm in total from tumor margin). If there is more than 1 site of subretinal/vitreous seeding, then the total of these sites must be <6 mm.
4. Group D (Fig. 4): Diffuse vitreous and/or subretinal seeding (>6 mm in total from tumor margin). If there is more than 1 site of subretinal/vitreous seeding, then the total of these sites must be  $\geq 6$  mm. Subretinal fluid >6 mm from tumor margin.





**Fig. (3).** Fundus photograph showing two whitish subretinal tumors in the posterior pole, classified as Group C retinoblastoma.



**Fig. (4).** Fundus photograph showing multiple exophytic and endophytic tumors, with subretinal and vitreous seeding, classified as Group D retinoblastoma.

5. Group E (Figs. 5 & 6): No visual potential; or presence of any 1 or more of the following: Tumor in the anterior segment, tumor in or on the ciliary body, neovascular glaucoma, vitreous hemorrhage obscuring the tumor or significant hyphema, phthisical or pre-phthisical eye, or orbital cellulitis-like presentation.

## Cavernous Hemangioma of the Retina

Gerardo García-Aguirre<sup>1,2,\*</sup>

<sup>1</sup> Retina Department, Asociación para Evitar la Ceguera en Mexico, Mexico City, Mexico

<sup>2</sup> Clinical Professor of Ophthalmology, Escuela de Medicina - Tec de Monterrey, Mexico City, Mexico

Cavernous hemangioma of the retina is a rare congenital vascular hamartoma with a very particular appearance, which was described as early as 1937 [1]. It may be an isolated finding, or it may be associated with one or more intracranial cavernous hemangiomas, as well as with angiomatous hamartomas of the skin [1]. If the tumor does not affect the macula, patients are usually asymptomatic, unless vitreous hemorrhage or macular fibrosis develop.

### ESSENTIALS OF DIAGNOSIS

*Clinical examination* reveals a group of blood-filled saccules within the inner retinal layers or on the surface of the optic disc [1, 3]. The appearance is usually described as a “cluster of grapes” (Fig. 1), that may be located anywhere in the retina, but usually follows the course of a retinal vein. It may be associated to an epiretinal membrane or a vitreous hemorrhage [3].

Fluorescein angiography shows delayed filling of the saccules, due to the low-flow status of this tumor [3]. Fluorescence blockage may be observed if there is hemorrhage present (Fig. 2).

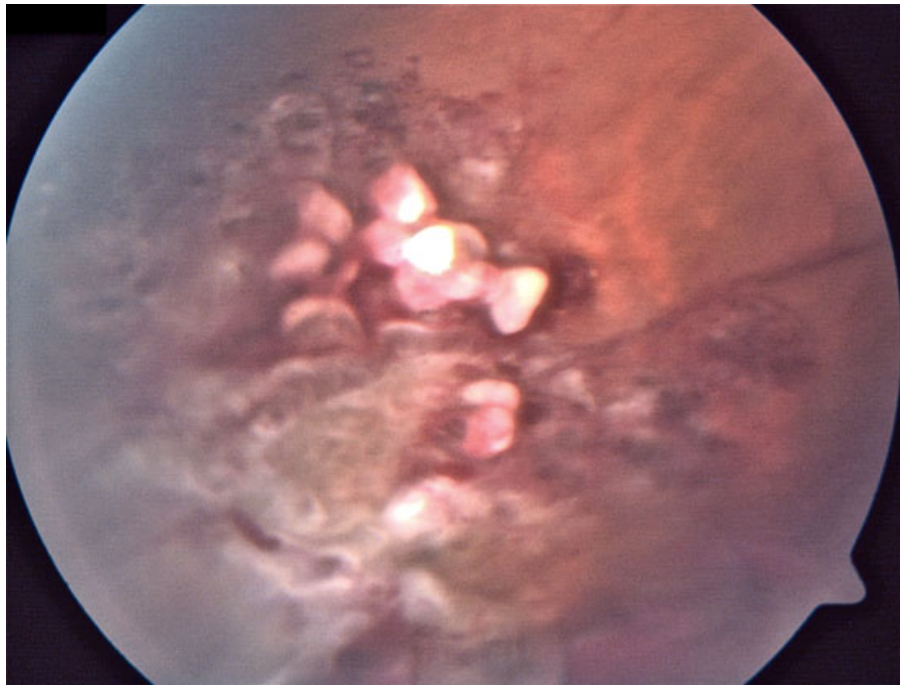### DIFFERENTIAL DIAGNOSIS

Since the clinical appearance of the tumor is quite peculiar, differential diagnosis does not pose a significant challenge most of the times.

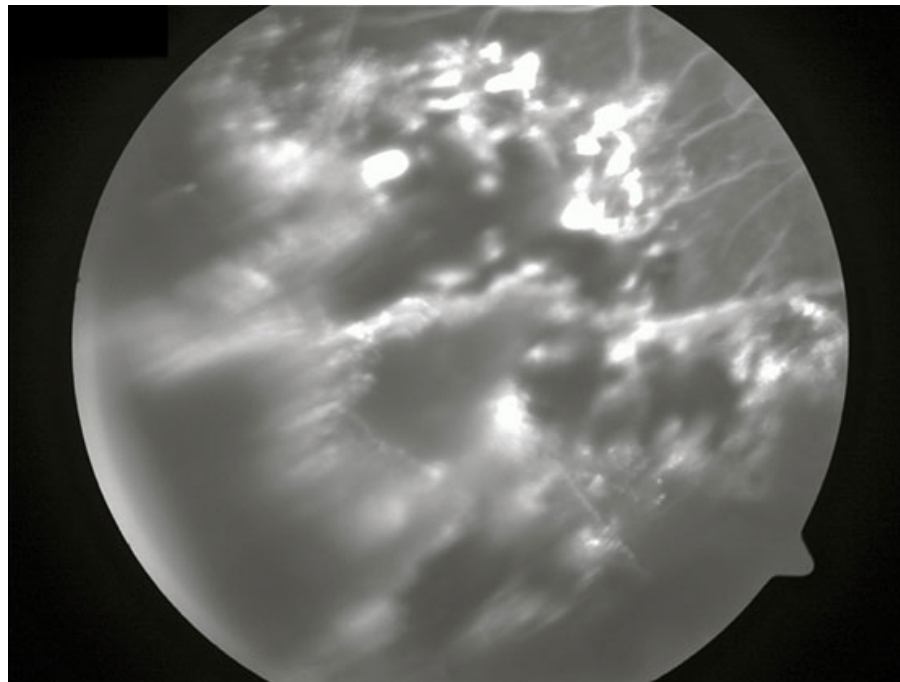
The main differential diagnosis is with a capillary hemangioma of the retina, which differs from a cavernous hemangioma in that the former has prominent feeder vessels that may be easily observed clinically and with fluorescein angiogram.

---

\* Corresponding author Gerardo García Aguirre: Vicente García Torres 46, San Lucas Coyoacan, Mexico City, Mexico, 04030; Tel: +52 (55) 10841400; Email: jerry\_gar\_md@yahoo.com



**Fig. (1).** Cavernous hemangioma of the retina with characteristic “cluster-of-grapes” appearance.



**Fig. (2).** Fluorescein angiography shows hyperfluorescent saccular caps and blocked fluorescence due to retinal hemorrhages.

## **MANAGEMENT**

In most instances, treatment for a cavernous hemangioma of the retina is not necessary because the lesion is outside of the macula. These tumors, however, can develop an epiretinal membrane or vitreous hemorrhage that may require vitrectomy [1, 4]. If the tumor involves the macula and visual acuity is decreased, photocoagulation [2, 3] or intravenous infliximab [1, 5] have been advocated.

## **CONFLICT OF INTEREST**

The author confirms that author has no conflict of interest to declare for this publication.

## **ACKNOWLEDGEMENTS**

Declared none.

## **REFERENCES**

- [1] Scheyhing H. Ein seltner Fall von angiomatosen Vernderungen der Netzhaut. *Klin Mbl Augenheilk* 1937; 99: 362.
- [2] Gass JD. Cavernous hemangioma of the retina. A neuro-oculo-cutaneous syndrome. *Am J Ophthalmol* 1971; 71(4): 799-814.  
[[http://dx.doi.org/10.1016/0002-9394\(71\)90245-5](http://dx.doi.org/10.1016/0002-9394(71)90245-5)] [PMID: 5553009]
- [3] Turell ME, Singh AD. Vascular tumors of the retina and choroid: diagnosis and treatment. *Middle East Afr J Ophthalmol* 2010; 17(3): 191-200.  
[<http://dx.doi.org/10.4103/0974-9233.65486>] [PMID: 20844673]
- [4] Haller JA, Knox DL. Vitrectomy for persistent vitreous hemorrhage from a cavernous hemangioma of the optic disk. *Am J Ophthalmol* 1993; 116(1): 106-7.  
[[http://dx.doi.org/10.1016/S0002-9394\(14\)71757-X](http://dx.doi.org/10.1016/S0002-9394(14)71757-X)] [PMID: 8328530]
- [5] Japiassú RM, Moura Brasil OF, de Souza EC. Regression of Macular Cavernous Hemangioma with systemic infliximab. *Ophthalmic Surg Lasers Imaging* 2010; 9: 1-3.  
[PMID: 20337337]

## Von Hippel-Lindau Disease

Gabriela Lópezcarasa\*

Ophthalmology Department, Hospital Angeles Lomas, Mexico City, Mexico

Von Hippel-Lindau disease (VHL) is an autosomal dominant systemic syndrome that results from a mutation in the *VHL* gene on chromosome 3 (3p25-26) [1, 3]. *VHL* mutations have been associated to the development of different tumors. The most frequent are hemangioblastomas of the retina and central nervous system, clear-cell renal carcinoma and pheochromocytomas, pancreatic islet cell tumors and endolymphatic sac tumors [2, 4 - 6]. All of these tumors may occur sporadically, so a clinical diagnosis of VHL disease in a patient without a positive family history requires the presence of two tumors. Approximately 20% of VHL disease patients result from a *de novo* mutation and do not have a family history [2, 7]. Vascular tumors of the retina and choroid are a major source of long-term visual disability [8]. Capillary hemangioma of the retina (RCH) associated with VHL appears in the second and third decades of life with a median of 17.6 years, there is no sex or racial predisposition, but it is more common in whites [1].

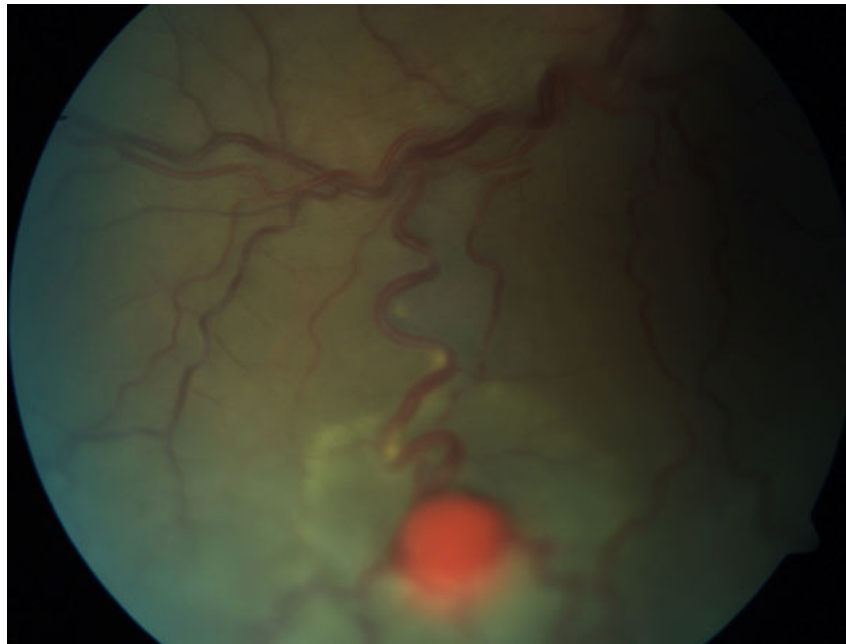
The estimated incidence of VHL is 1/36000 [1, 11]. VHL disease is suggested to account for approximately a third of patients with a CNS hemangioblastoma [2, 9, 10]. Retinal hemangioblastoma is seen in more than 60% of patients with VHL disease [3].

### ESSENTIALS OF DIAGNOSIS

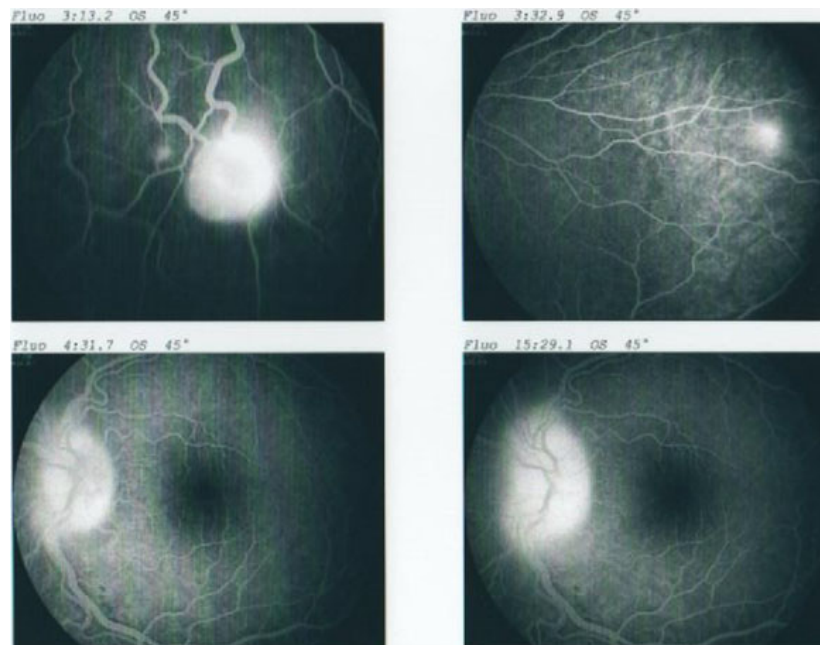
The hallmark lesion of VHL disease is the RCH, which can occur as a peripheral lesion in 90.4% of cases (Figs. 1-6, 8-10) and a juxtapapillary tumor in 9.6% of the cases (Figs. 7 and 12) [11]. Half of the patients with retinal hemangioblastoma have bilateral involvement [3].

---

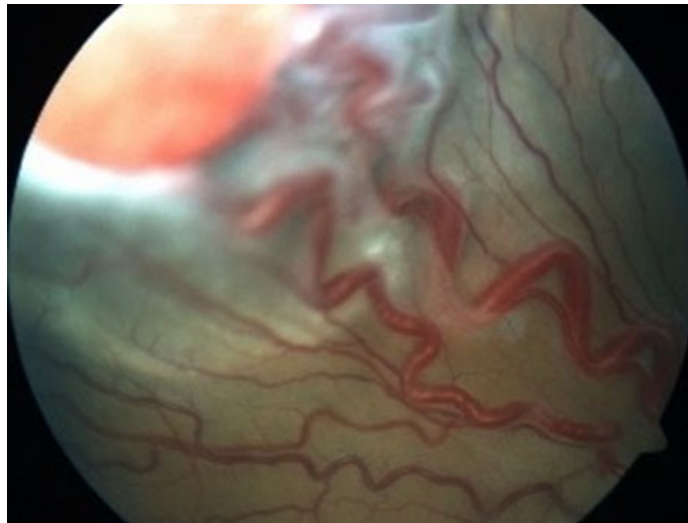
\* Corresponding author Gabriela Lópezcarasa: Ophthalmology Department, Hospital Angeles Lomas, Mexico City, Mexico; Tel: +52(55)52469809; Email: gabylcarasa@hotmail.com



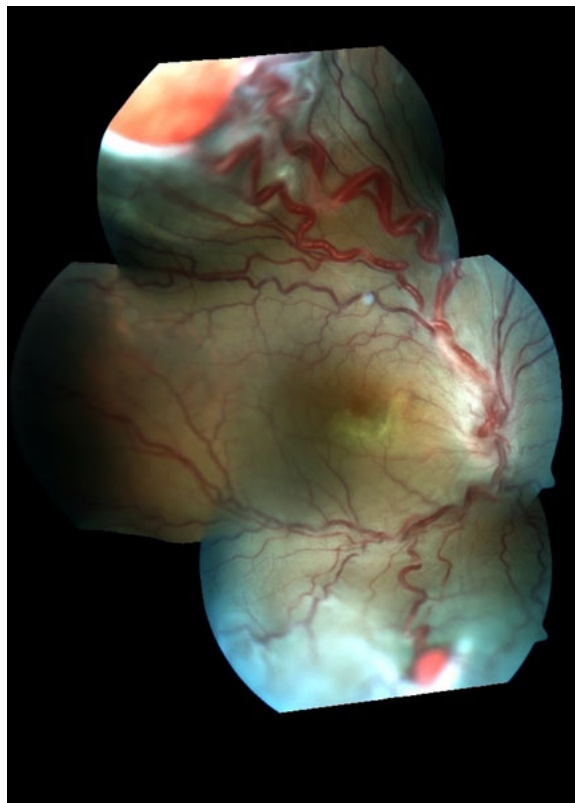**Fig. (1).** Small peripheral angioma with characteristic feeder and draining vessels and the presence of subretinal fluid.



**Fig. (2).** Fluorescein angiogram at 3 minutes and late-phases with hyperfluorescence and leakage of the tumor. In this angiogram we can see 2 different-sized angiomas as well as optic nerve hyperfluorescence secondary to papilledema.



**Fig. (3).** Large peripheral angioma with prominent feeder vessels and serous retinal detachment, located supero temporal.



**Fig. (4).** Composed color photograph of the right eye of a patient with VHL where we can see 2 different-sized angiomas with serous retinal detachment, feeder and draining vessels as well as early macular edema and papilledema.



## Astrocytoma Tuberous Sclerosis

Noel Millán Moreno<sup>1,2,\*</sup>

<sup>1</sup> Instituto de Especialidades Oftalmológicas del Centro (IDEOF), Maracay, Venezuela

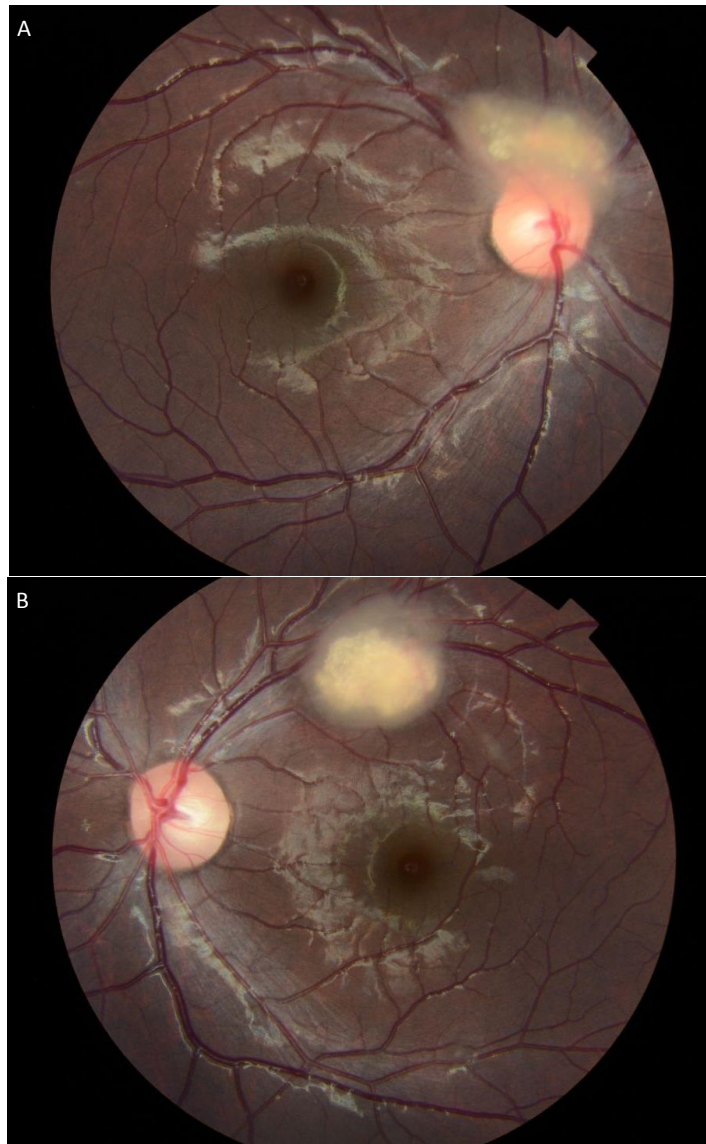
<sup>2</sup> Centro Oftalmológico Regional Aragua (CORA), Maracay, Venezuela

Tuberous sclerosis complex (TSC), also known as Bourneville's disease, was first identified in 1880, after the autopsy of a 15-year-old teenager who suffered from lifelong epilepsy [1]. It is described as an autosomal-dominant, neurocutaneous disease that has a great number of manifestations, involving many organ systems, but most frequently the brain, skin, kidney, heart, and eyes. In 80-90% of the cases, it is diagnosed before the age of 10, even in stages of intrauterine development [2, 3]. The incidence is estimated at 1:6,000-10,000 live births [4, 5]. TSC is caused by a mutation in either of two tumor suppressor genes: TSC1 on chromosome 19q34 or TSC2 on chromosome 16p13 [6, 7]. Both genes act cooperatively to regulate cellular growth and differentiation [8]. Mutations of these genes result in the formation of hamartomas.

### ESSENTIALS OF DIAGNOSIS

TSC diagnosis may not be easy because some signs and symptoms vary from one individual to another. However, during the first TSC consensus conference in 1998, the diagnostic criteria were divided into major features and minor features. Major features are facial angiofibromas, periungual fibromas, three or more hypomelanotic macules, Shagreen patch (connective tissue nevus), cortical tuber, subependymal nodules, subependymal giant cell astrocytomas, multiple retinal nodular hamartomas, cardiac rhabdomyoma (multiple or single), lymphangioma, lymphangioma, and renal angiomyolipoma. Minor features include the following: multiple, randomly-distributed pits in dental enamel (more than 14), hamartomatous rectal polyps, bone cysts, cerebral white matter migration lines, gingival fibromas, non-renal hamartoma, retinal achromic patch, "confetti" skin lesions, and multiple renal cysts [9]. In 2012, during the second TSC consensus conference, the existing criteria were revised and some minor changes were made.

\* Corresponding author Noel Millán Moreno: Instituto de Especialidades Oftalmológicas del Centro (IDEOF), Torre Sindoni, Mezzanine floor, Maracay, Venezuela; Tel: +58 (243)-6153933; Email: noelmillan@hotmail.com



**Fig. (1).** Color fundus photographs of 9 year-old male patient with Tuberous Sclerosis showed solid grey-yellowish lesions with a jelly-like translucent appearance on top and accumulation of circular opacities in the inside, spread in the center of the tumor, having the appearance of fish eggs, located at the superior periphery of the optic nerve in the right eye (A) and at the level of the superior temporal vascular arcade in the left eye (B).

A strong emphasis was placed on the importance of genetic testing, which was included in the major criteria and was made a definite criterion for diagnosis, irrespective of the clinical presentation [10]. It was also established that the combination of two major features or the combination of one major feature with

two minor features are sufficient to make a definite diagnosis. Patients with TSC have demonstrated numerous eye findings, which may affect the orbit and eye adnexa, as well as the intraocular structures of the eye, including the anterior and posterior segments, and in some cases, may result in secondary glaucoma. The retina is the eye layer most frequently affected. According to different studies, retinal astrocytic hamartoma or retinal astrocytoma is present in 25-53% of TSC patients [11, 12]. It can occur as a calcified or non-calcified lesion. Calcified astrocytic hamartoma is a multinodular, elevated, ovoid, or circular “mulberry-like” lesion usually located at the posterior pole near the optic nerve, with a yellowish color due to calcification (Fig. 1). The non-calcified variant appears as a flat or slightly elevated grey-yellow lesion, generally found on the peripheral retina. It is a benign tumor composed of a proliferation of well-differentiated astrocytes. Astrocytoma can be congenital or can become apparent some time after birth. Although it is usually a stable lesion, there have been cases that showed progressive growth [13, 14].

### **DIFFERENTIAL DIAGNOSIS**

Differential diagnosis should always consider retinoblastoma, as well as choroidal melanoma.

### **MANAGEMENT**

Treatment for these tumors is not necessary except if visual acuity is compromised because of macular edema or intraretinal hemorrhages. In those cases, the use of a combined bevacizumab and triamcinolone acetonide intravitreal injection has shown good results [15].

### **CONFLICT OF INTEREST**

The author confirms that author has no conflict of interest to declare for this publication.

### **ACKNOWLEDGEMENTS**

Declared none.

### **REFERENCES**

- [1] Bourneville D. Scleros tubereuse des circonvolutions cerebrales idiotie et epilepsy hemipelegique. Arch Ophthalmol 1880; 1: 181-1.
- [2] Staley BA, Vail EA, Thiele EA. Tuberous sclerosis complex: diagnostic challenges, presenting symptoms, and commonly missed signs. Pediatrics 2011; 127(1): e117-25. [<http://dx.doi.org/10.1542/peds.2010-0192>] [PMID: 21173003]

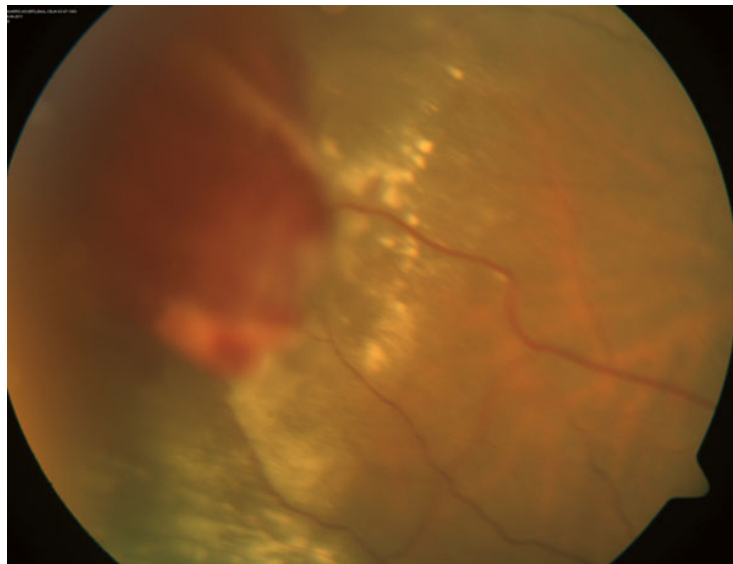
## Retinal Vasoproliferative Tumor

Gerardo García-Aguirre<sup>1,2,\*</sup>

<sup>1</sup> Retina Department, Asociación para Evitar la Ceguera en Mexico, Mexico City, Mexico

<sup>2</sup> Clinical Professor of Ophthalmology, Escuela de Medicina - Tec de Monterrey, Mexico City, Mexico

Retinal vasoproliferative tumor (RVPT, also known as peripheral vascular tumor, pseudoangiomatous proliferation of the retina or reactive retinal astrocytic tumor) is a relatively uncommon vascular disease of the retina, characterized by the presence of a solid retinal lesion located in the periphery (Fig. 1), which can be an isolated finding (76%) or secondary to a pre-existing ocular inflammatory or vascular disease, such as intermediate uveitis, retinitis pigmentosa or Coats' disease [1, 2]. This entity is more common in males, and typically occurs in the 3<sup>rd</sup> and 4<sup>th</sup> decades of life. It is usually asymptomatic, until there is a vitreous hemorrhage, or the macula becomes affected [3].



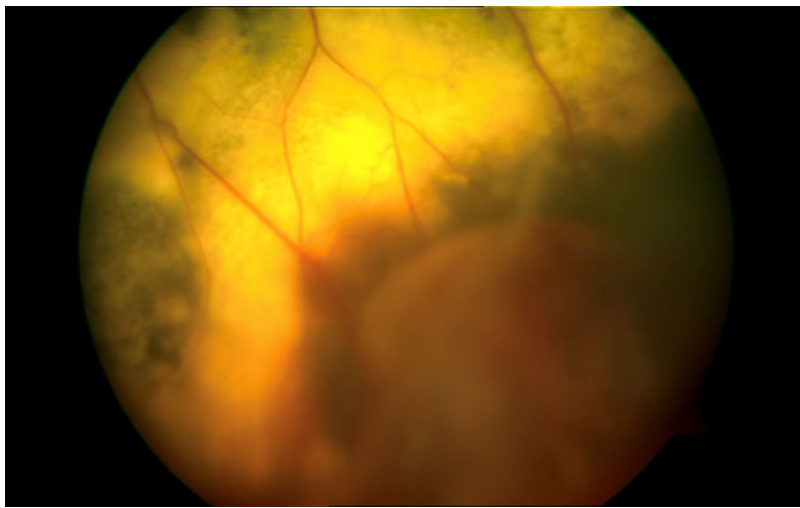
**Fig. (1).** Fundus photograph of the superotemporal retinal periphery on the right eye of a 17 year-old male, showing a tumor surrounded by hard exudates, with intra and preretinal hemorrhage.

\* Corresponding author Gerardo García-Aguirre: Vicente García Torres 46, San Lucas Coyoacan, Mexico City, Mexico, 04030; Tel: +52 (55) 10841400; Email: jerry\_gar\_md@yahoo.com

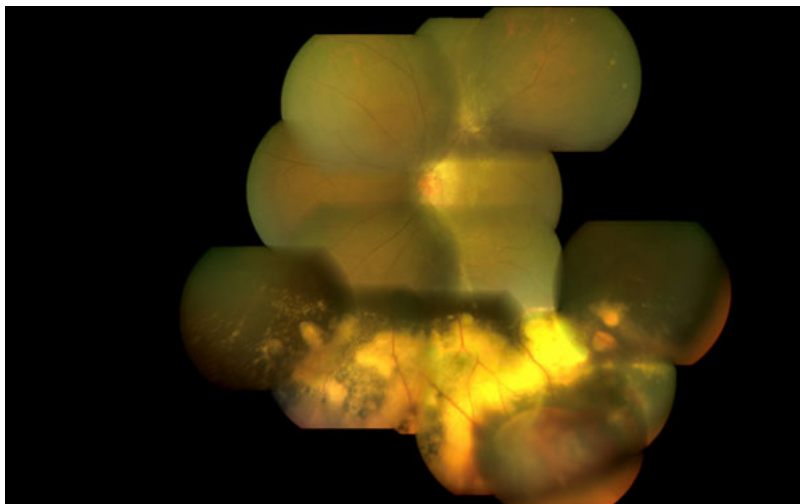
Mitz E. Torres Soriano, Gerardo García-Aguirre, Maximiliano Gordon & Veronica Kon Graversen (Eds.)  
All rights reserved-© 2017 Bentham Science Publishers

## ESSENTIALS OF DIAGNOSIS

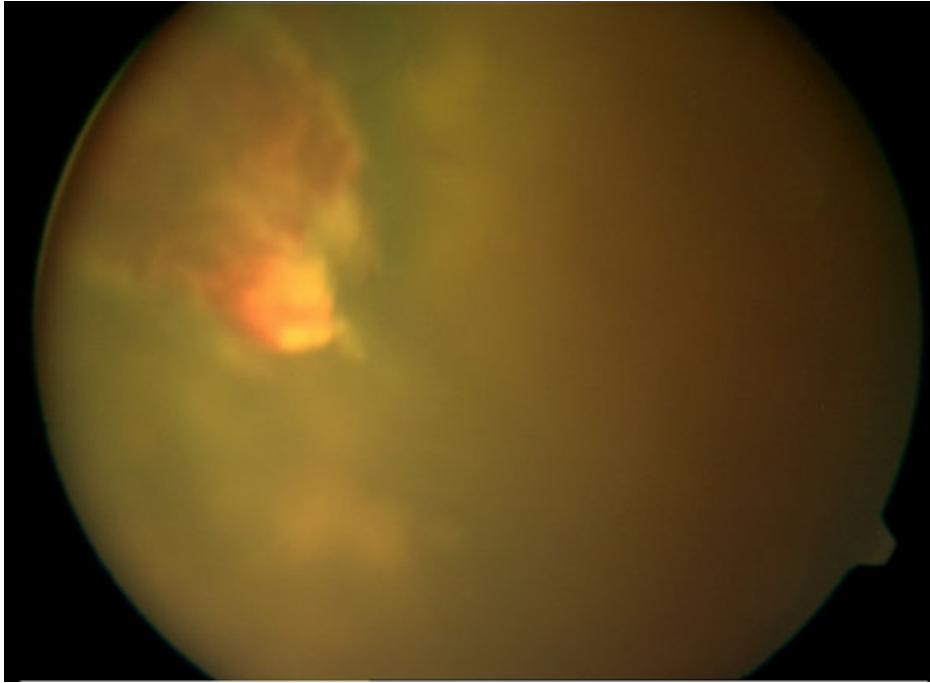
*Clinical examination* reveals a peripheral orange or pinkish retinal mass (Fig. 2) that is generally located in the inferotemporal quadrant (Fig. 3), usually with concomitant intra or preretinal hemorrhage (Figs. 4-6). Hard exudates and a serous retinal detachment may be observed surrounding the lesion in 80% and 50% of cases, respectively. The macula may be affected by an epiretinal membrane (25%) (Fig. 7) or cystoid macular edema (14%). Vitreous hemorrhage is present in 18% [1].



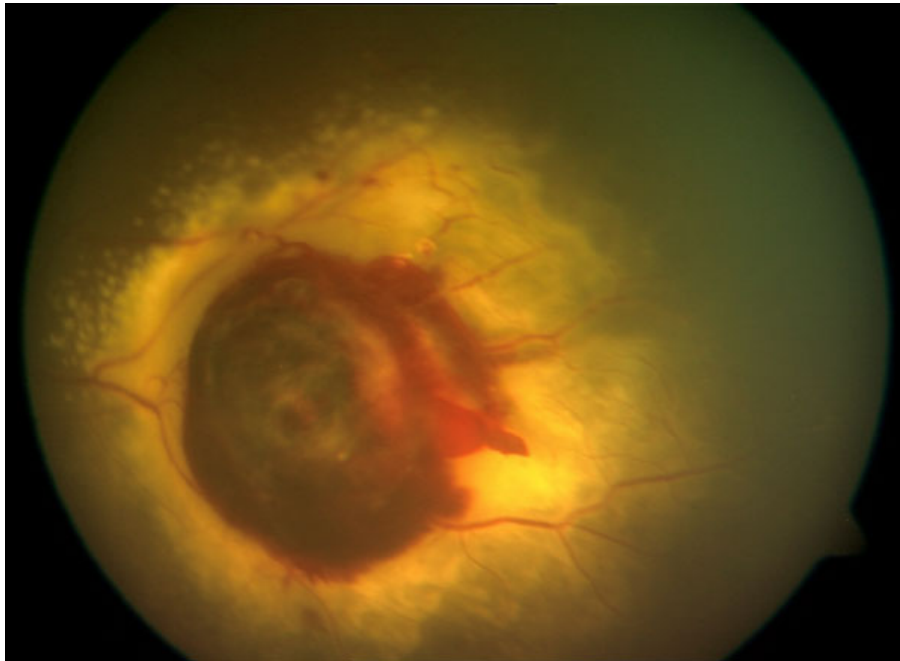
**Fig. (2).** Fundus photograph of the inferotemporal retinal periphery on the left eye of a 35 year-old male, showing a tumor surrounded by hard exudates and a shallow retinal detachment, and with some preretinal hemorrhage.



**Fig. (3).** Composite photograph of the same eye described in Fig. (2).



**Fig. (4).** Fundus photograph of the superotemporal retinal periphery on the right eye of a 25 year-old male, showing a tumor with preretinal and vitreous hemorrhage.



**Fig. (5).** Fundus photograph of the left eye of a 29 year-old male, showing a tumor with preretinal hemorrhage surrounded by hard exudates.

## **Melanocytoma**

**Gerardo García-Aguirre<sup>1\*</sup> and Andrée Henaine-Berra<sup>2</sup>**

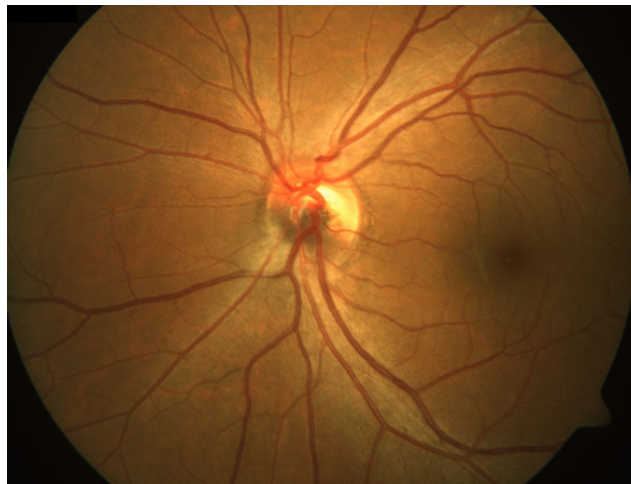
<sup>1</sup> *Retina Department, Asociación para Evitar la Ceguera en Mexico, Mexico City, Mexico*

<sup>2</sup> *Hospital General “Dr. Manuel Gea González”, Mexico City, Mexico*

Melanocytoma is a variant of a melanocytic nevus, which usually appears in the optic disc (although it may appear anywhere in the uveal tract), characterized by a very dark color and composed by heavily pigmented round to oval cells with small, round, uniform nuclei [1].

### **ESSENTIALS OF DIAGNOSIS**

Melanocytomas appear as a very dark mass, usually near the optic disc, although they may be observed in any component of the uveal tract. Most of them are asymptomatic, but some visual loss is expected in one fourth of the cases, usually related to the presence of intra or subretinal fluid secondary to exudation [2]. More severe visual loss may occur in case of an associated retinal vein occlusion, tumor necrosis, malignant transformation or choroidal neovascularization (Fig. 3) [1 - 6].

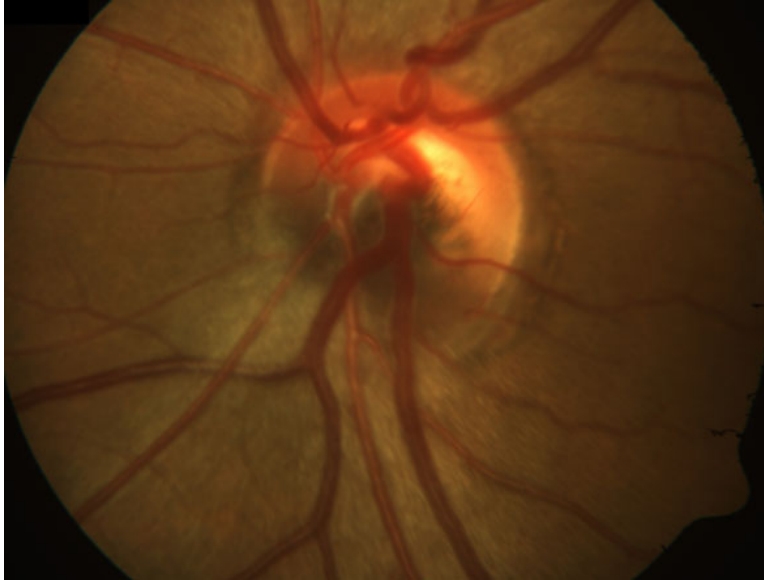


**Fig. (1).** Fundus photograph showing an intensely pigmented lesion on the inferior aspect of the optic nerve.

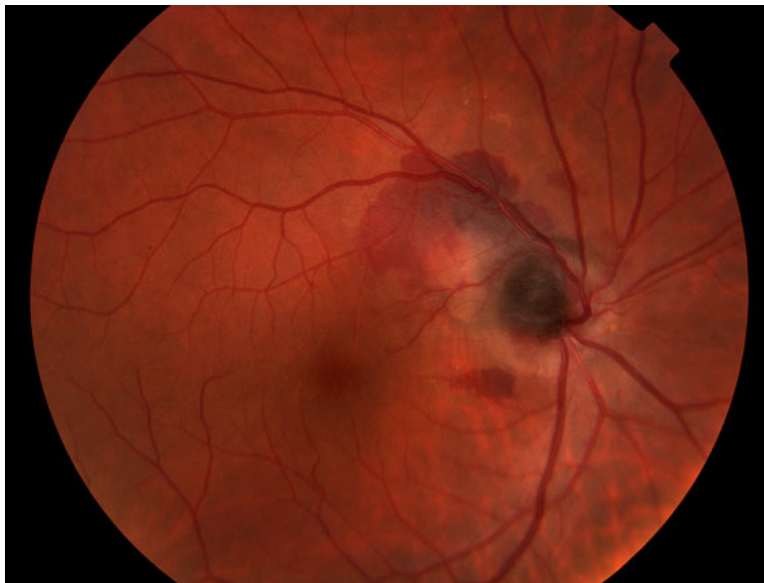\* **Corresponding author Gerardo García-Aguirre:** Vicente García Torres 46, San Lucas Coyoacan, Mexico City, Mexico, 04030; Tel: +52 (55) 10841400; Email: jerry\_gar\_md@yahoo.com



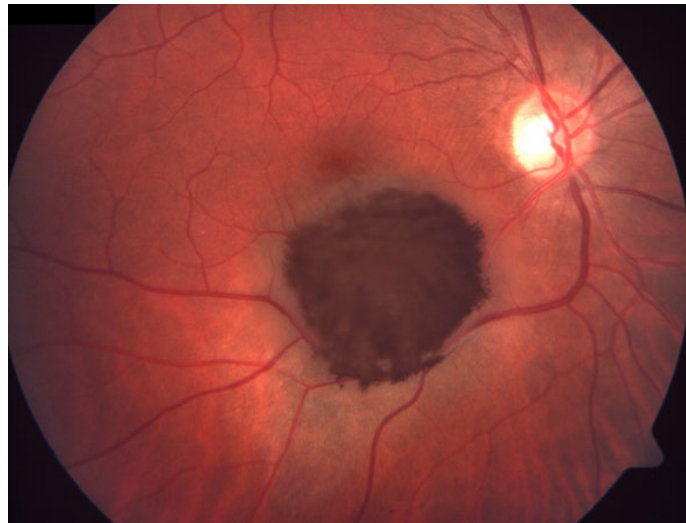The diagnosis of melanocytoma is usually reached with fundoscopic examination, where a very darkly pigmented mass is observed over or near the optic disc (Figs. 1-3). Rarely, melanocytomas may appear elsewhere, making the diagnostic process harder (Fig. 4). Since the tumor usually involves different layers of the retina, it may obscure some features such as vessels or the border of the optic disc.



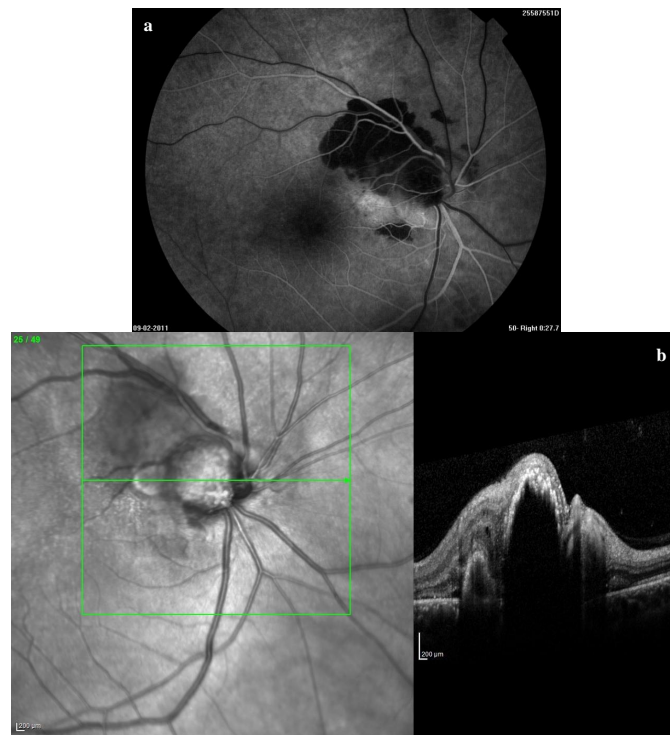
**Fig. (2).** Close-up of the same lesion shown in Fig. (1).



**Fig. (3).** Fundus photograph showing optic disc melanocytoma associated with subretinal hemorrhage due to CNV.



**Fig. (4).** Fundus photograph showing a dark pigmented lesion that appears to have subretinal, intraretinal and epiretinal components.



**Fig. (5).** FA and OCT of the same patient of Fig. (3). (a) Fluorescein angiogram shows an area of hypofluorescence that results from subretinal hemorrhage and optic disc melanocytoma, as well as a peripapillary focus of hyperfluorescence (CNV) in early arteriovenous phase. (b) Spectral domain OCT of the lesion shows hyper-reflectivity at its anterior tumor surface and dense posterior shadowing with an optically empty appearance.

## Congenital Hypertrophy of the Retinal Pigment Epithelium

Raul Velez-Montoya\* and Gerardo García-Aguirre

*Retina Department, Asociación para Evitar la Ceguera en México, AIP, México City, México*

Congenital hypertrophy of the retinal pigment epithelium (CHRPE) is a hamartoma of the retinal pigment epithelium (RPE) [1], first described by Reese and Jones in the 1950s [2, 3], but its congenital nature was not described until 1974 by Buettner *et al.* [4].

### ESSENTIALS OF DIAGNOSIS

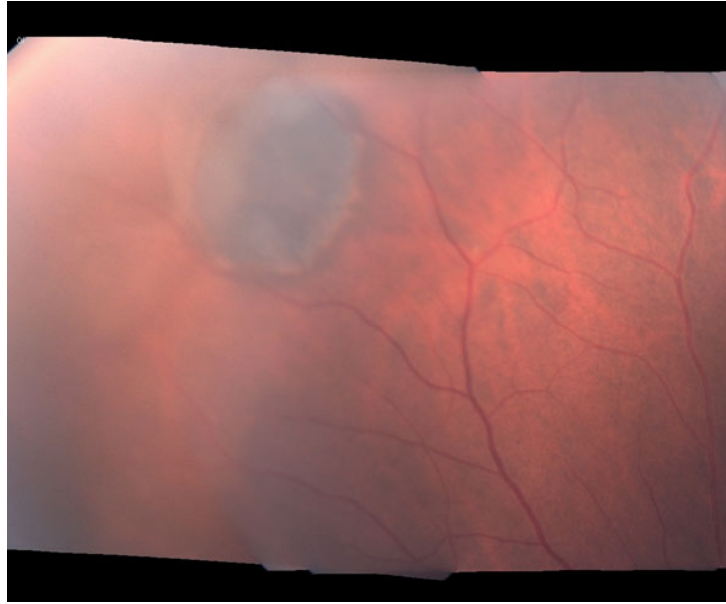
It is characterized by a flat, well-demarcated, darkly pigmented lesion, typically located at the midperiphery of the retina [2, 5, 6]. It has two different clinical manifestations: a solitary congenital form whose etiology is still not well understood, but it is believed to be the result of a local process occurring during retina development [7]; and the lesions occurring as part of the Familial Adenomatous Polyposis (FAP) clinical spectrum, in which a truncating mutation between codons 463 and 1387 in the APC gene induces the additional formation of intestinal polyps, osteomas, skin tumors, supernumerary teeth and desmoid tumor (Gardner's syndrome) [2, 7, 8].

Solitary CHRPE, also named “benign melanoma of the RPE” or “hypertrophy with hyperpigmentation of the RPE” [6], is usually discovered coincidentally during a fundus examination [6]. It can present as single (Figs. 1, 4, 5) or multiple (Figs. 2 and 3) hyperpigmented lesions, which can be surrounded by a marginal halo and depigmented lacunae within the lesions (Figs. 4 and 5) [5, 6]. The prevalence in normal population ranges between 1.2 and 4.4% [9 - 11]. The coloration and shape of the lesions are variable and can range from gray to black and from round to oval respectively [9]. There is no predilection for gender, although some studies have found a slightly higher incidence in females [6], and

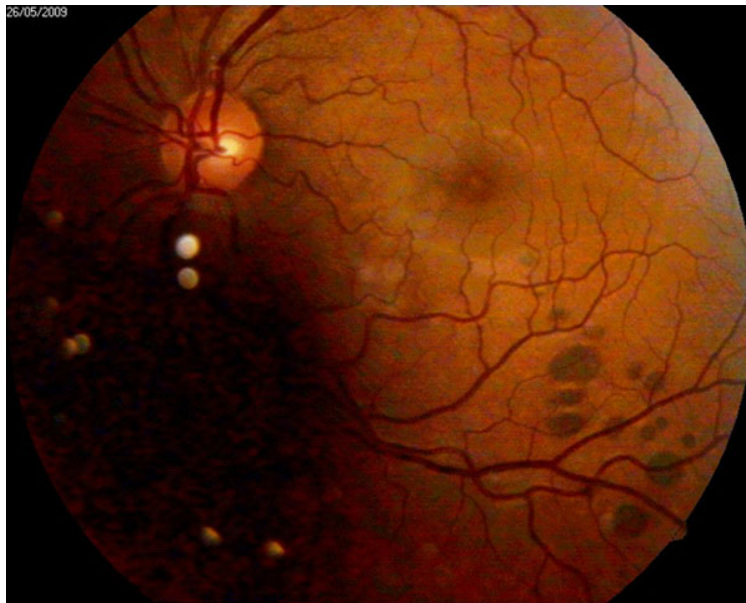
---

\* Corresponding author Raul Velez Montoya: Vicente García Torres, 46. San Lucas Coyoacán, México DF. México 04030; Tel: +52 55 10841400; Fax: +52 55 10841404; Email: rvelezmx@yahoo.com

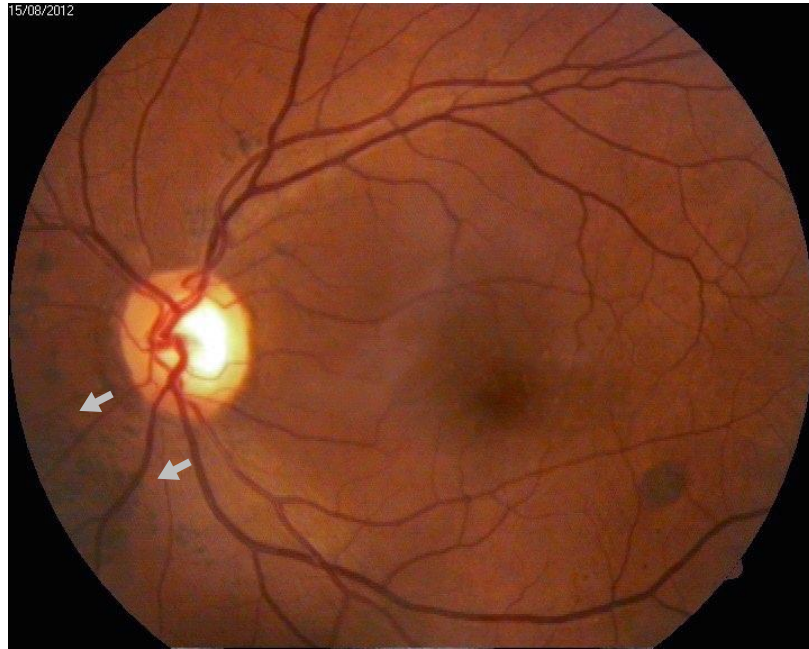
the most frequent localization seems to be the inferonasal quadrant [5]. The size of the lesion varies widely and can range from 3 to 11 mm, and the median distance to the fovea and optic nerve head is approximately 12 mm [5].



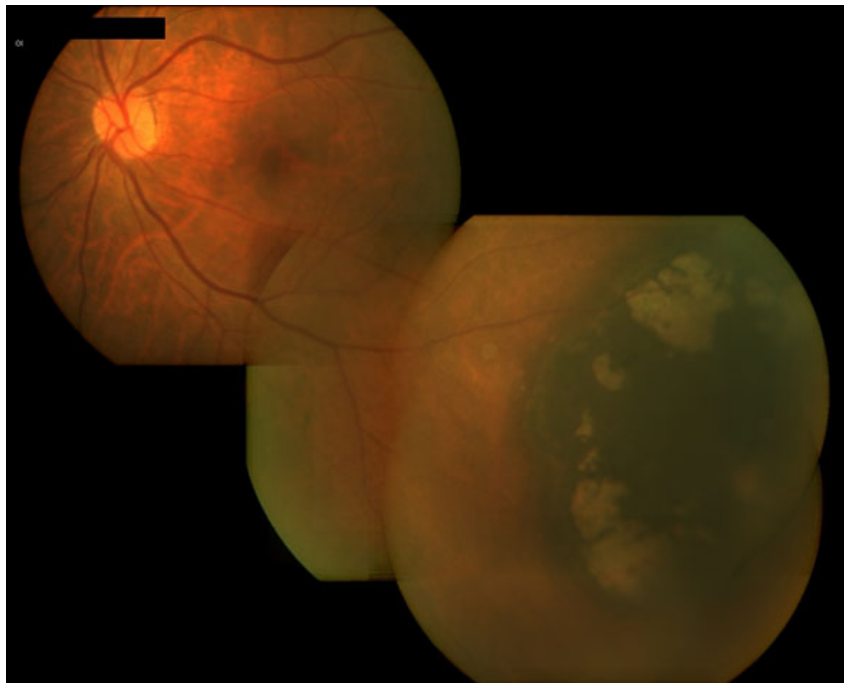
**Fig. (1).** Peripheral fundus photograph showing an intensely pigmented lesion with well-demarcated borders and a hypopigmented halo around it.



**Fig. (2).** Congenital grouped pigmentation of the retina (bear tracks) (Courtesy of Mitzy E. Torres Soriano MD).



**Fig. (3).** Grouped congenital hypertrophy of the retinal pigment epithelium (Grey arrows) (Courtesy of Mitzy E. Torres Soriano MD).



**Fig. (4).** Image showing a pigmented lesion in the inferotemporal periphery, with well-demarcated borders and hypopigmented lacunae within the lesion.

## **Combined Hamartoma of Retina and Retinal Pigment Epithelium**

**Maximiliano Gordon**<sup>1,2,\*</sup>

<sup>1</sup> *Centro de la Visión Gordon- Manavella, Rosario, Argentina*

<sup>2</sup> *Hospital Provincial del Centenario, Rosario, Argentina*

### **ESSENTIALS OF DIAGNOSIS**

In 1973, Gass reported a series of 7 patients with an unusual lesion of the retinal pigment epithelium (RPE) and retina simulating either choroidal melanoma or retinoblastoma. He used the term “combined hamartoma of retina and RPE” (CHRRPE) to define it [1]. It is a benign tumor, but it can cause significant visual loss [2]. It is typically found in young children, often with symptoms of strabismus or reduced visual acuity [1].

It is usually a solitary, unilateral lesion located at the optic disc or posterior pole and typically appears slightly elevated, having various amounts of pigmentation, retinal vascular tortuosity, and epiretinal membrane (ERM) [2] (Figs. 1 and 2).

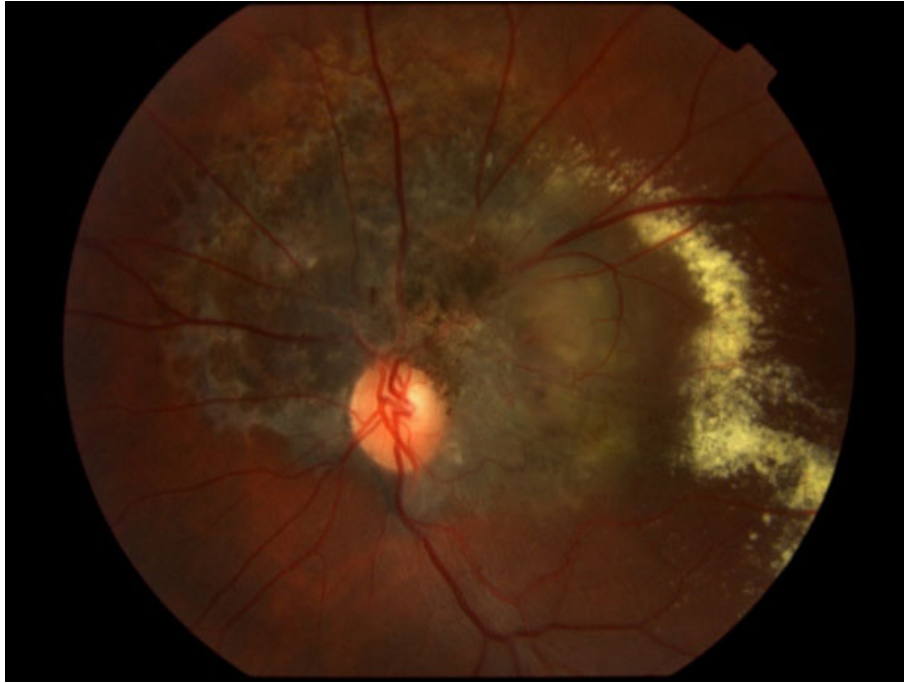Different complications may occur that produce decreased visual acuity, particularly with macular tumors, including epiretinal membrane (ERM), macular exudation, macular edema, retinal detachment, vitreous hemorrhage, choroidal neovascularization, foveal or optic disc dragging [1 - 3].

Fluorescein angiography shows hypofluorescence of choroid background in the arterial phase. Retinal vascular is tortuous and telangiectatic. Dye leakage from vessels within the lesion in late phases [2] (Fig. 3). OCT can reveal elevated lesion with high reflectivity of the inner retina, hypo-reflective shadowing of the underlying tissue and epiretinal membrane [2] (Fig. 4). B-scan ultrasound can demonstrate slightly elevated solid mass involving the disc and adjacent retina or the macular area.

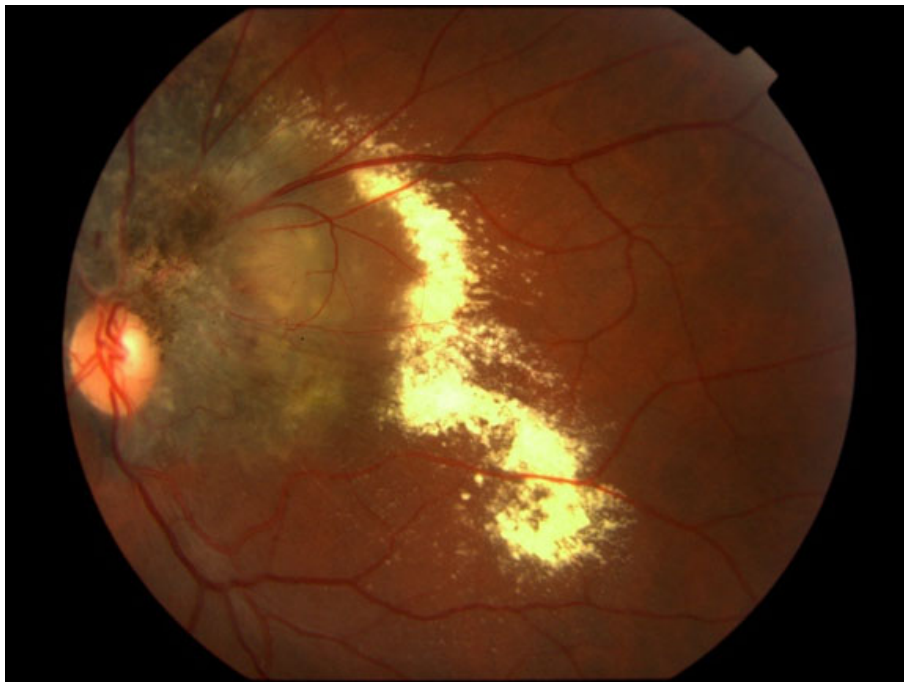---

\* **Corresponding author Maximiliano Gordon:** Centro de la Visión Gordon- Manavella, Montevideo 763, CP 2000, Rosario, Argentina; Tel: +54 (0341)4400239; Email: maximilianogordon19@gmail.com



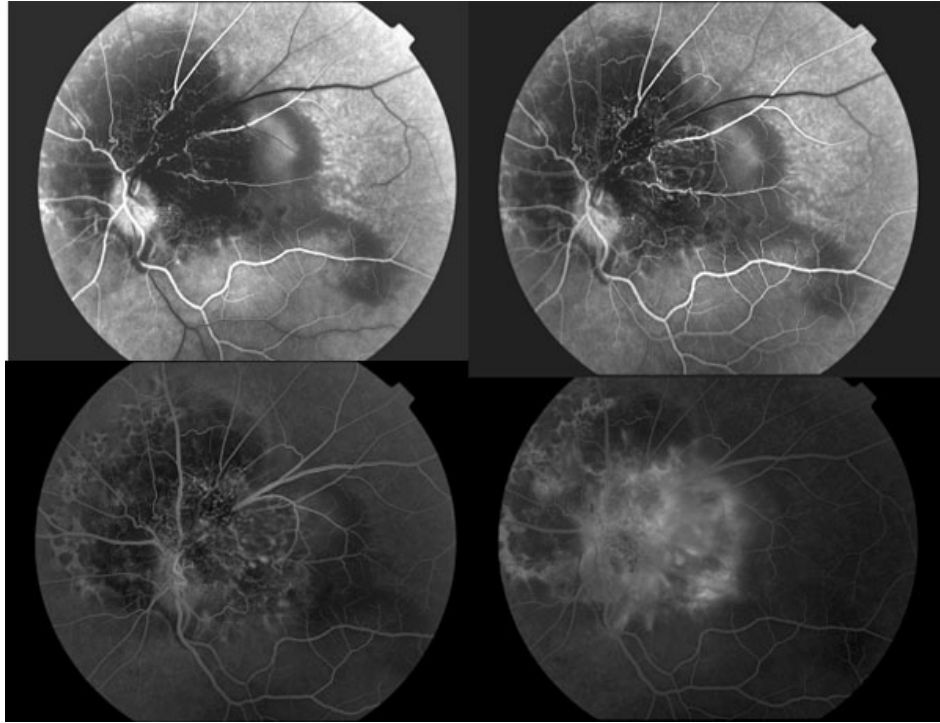


**Fig. (1).** Color fundus photograph: Peripapillary hyperpigmented lesion with exudation in posterior pole.

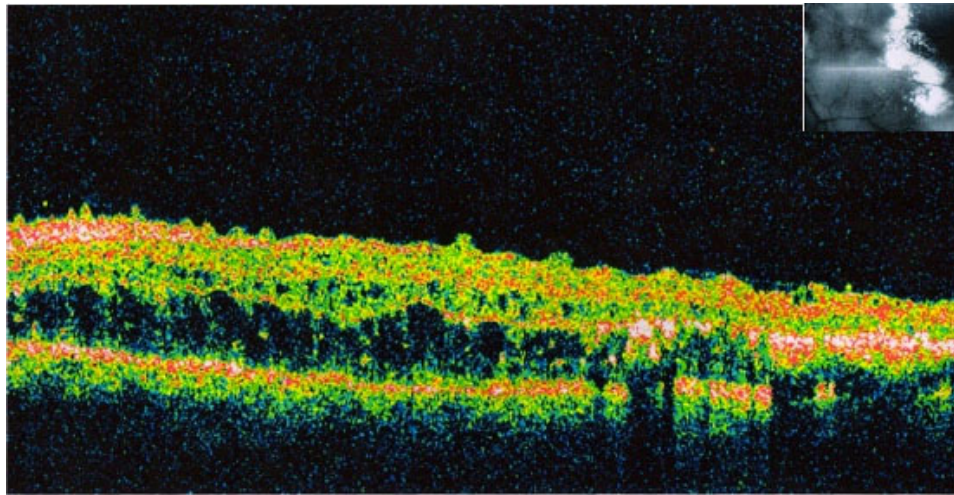


**Fig. (2).** Color fundus photograph: Exudation in the posterior pole.





**Fig. (3).** Fluorescein angiography: Hypofluorescence because of blockage in the early phases, and hyperfluorescence in late phases because of exudation.



**Fig. (4).** Epiretinal membrane with contraction of the macular surface and disorganization of the neuroretinal tissue is observed. Intra and subretinal fluid is present.

### **DIFFERENTIAL DIAGNOSIS**

Choroidal melanoma, choroidal nevus, retinoblastoma, toxocariasis, astrocytoma, hemangioma [1].

## Choroidal Nevi

Miguel Materin<sup>1,2,\*</sup> and Maximiliano Gordon<sup>3,4</sup>

<sup>1</sup> Smilow Cancer Hospital at Yale, New Haven, USA

<sup>2</sup> Department of Ophthalmology and Visual Science at Yale University, School of Medicine, New Haven, USA

<sup>3</sup> Retina Department, Centro de la Visión Gordon-Manavella, Rosario, Argentina

<sup>4</sup> Ophthalmology Department, Hospital Provincial del Centenario, Rosario, Argentina

### ESSENTIALS OF DIAGNOSIS

Choroidal nevi are benign melanocytic tumors of the ocular fundus. They are reported in 6.5% of the general white population [1]. Despite their benign nature and their low potential for causing visual symptoms [2], choroidal nevi have been the subject of interest among ophthalmologists mainly because of their clinical resemblance and potential malignant transformation to choroidal melanoma. Although the true malignant potential of choroidal nevi is not known, these lesions have long been suspected of being precursors of choroidal melanoma [3, 4]. However, most of the interest in choroidal nevi lies in the difficulties associated with differentiating them from small choroidal melanomas leading to delayed or unnecessary treatment with potentially life-threatening consequences or visually damaging complications, respectively [5, 6].

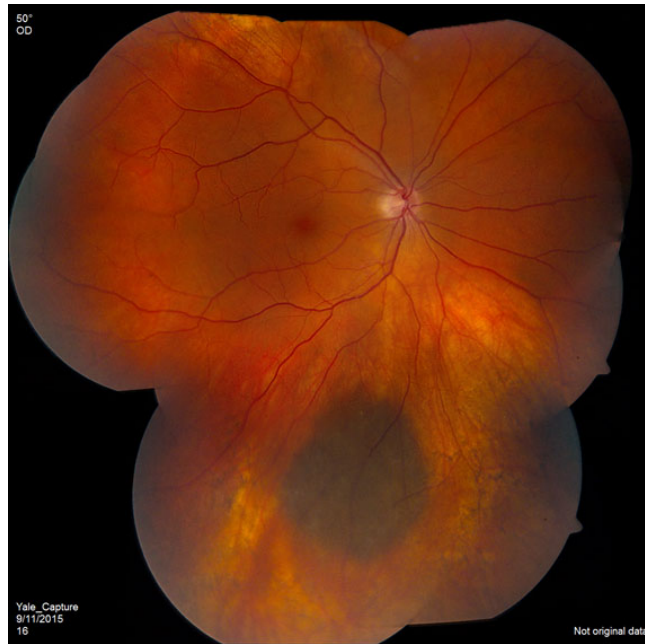
Clinically, choroidal nevi are asymptomatic, and appear as flat melanocytic choroidal lesion; drusen can be present in the surface. They remain unchanged over time (Figs. 1-5).

Optical coherence tomography demonstrated the choroidal mass with overlying drusen and without subretinal fluid (Figs. 4 and 6).

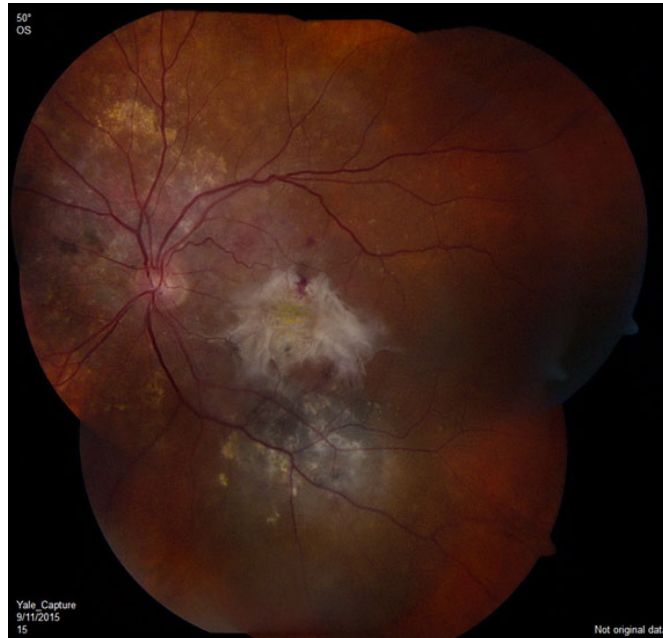
In ultrasonography, a thickness of  $\geq 2$  mm and a largest base diameter of  $\geq 7$  mm were most predictive of conversion to melanoma [7].

---

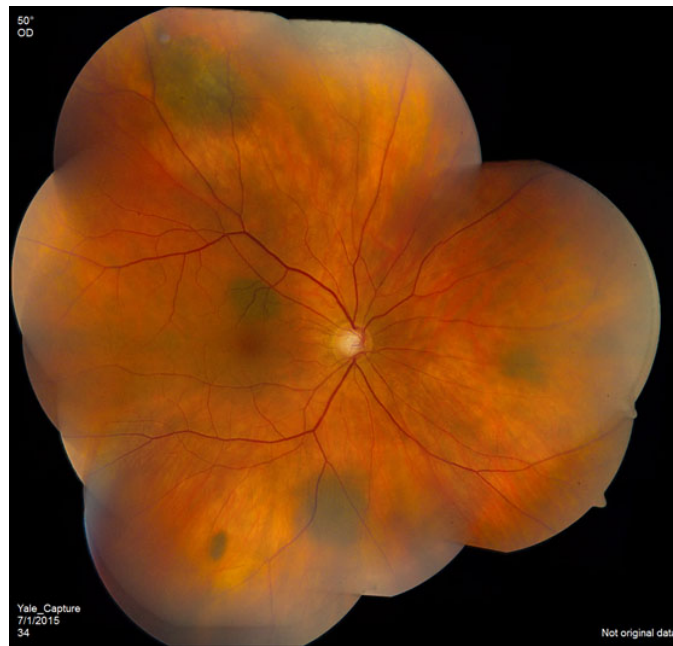\* Corresponding author Miguel Materin: 333 Cedar street, P.O. Box 208028, New Haven, CT 06520-8028, USA; Tel: 203-200-3937; Email: miguel.materin@yale.edu



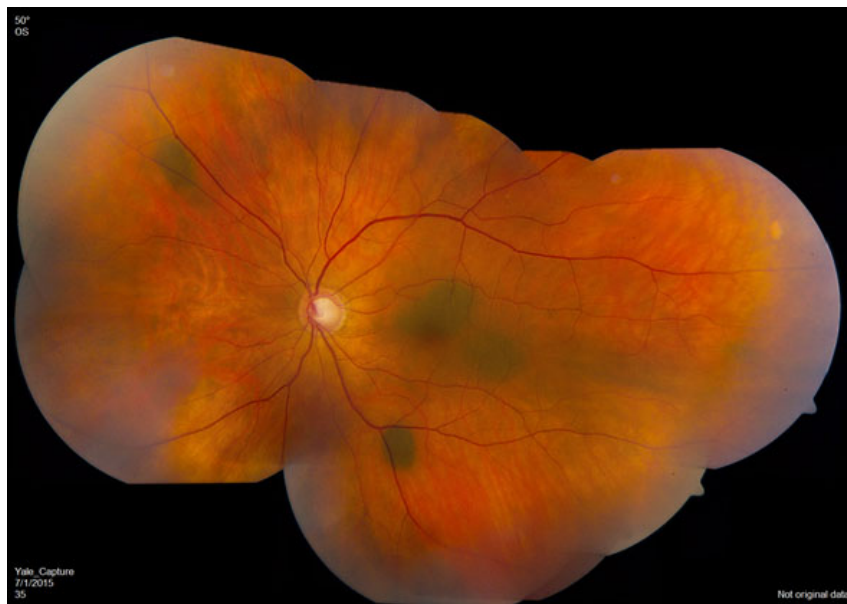**Fig. (1).** 59-year-old female with a choroidal melanocytic lesion followed for a year with no signs of growth, subretinal fluid or lipofuscin deposits. Note the overlying drusen and surrounded retinal pigment epithelium changes. The lesion was less than 2 mm thick.



**Fig. (2).** 88-year-old female with age-related macular degeneration, retinal drusen and a small pigmented melanocytic lesion involving the inferior arcade. Retinal drusen and retinal pigment epithelium hyperplasia are noted over the lesion. Tumor thickness was 2.2 mm. The lesion has been stable with no documented change in 3 years.



**Fig. (3-A).** Right eye of a 76-year-old patient with bilateral multiple pigmented choroidal lesions followed for 8 years with no documented change. No history of cutaneous melanoma or any other cancer was present (differential diagnosis includes metastatic cutaneous melanoma and bilateral diffuse uveal proliferation – BDUMP)



**Fig. (3-B).** Left eye of a 76-year-old patient with bilateral multiple pigmented choroidal lesions followed for 8 years with no documented change. No history of cutaneous melanoma or any other cancer was present (differential diagnosis includes metastatic cutaneous melanoma and bilateral diffuse uveal proliferation – BDUMP)

## **Choroidal Melanoma**

**Daniel Moreno Páramo\* and Stefanie Reyna Vielma**

*Ophthalmology Department, Hospital General de Mexico, Mexico City, Mexico*

Choroidal melanoma is the most common primary malignant intraocular tumor and the second most common type of primary malignant melanoma in adults, affecting approximately 5–11 individuals per million per year. Uveal melanoma at all ages is more common in men. The mean age at presentation is 60 years [1,2].

Two important risk factors for the development of uveal melanoma are a preexisting choroidal nevus and the presence of congenital ocular or oculodermal melanocytosis [2].

Uveal melanomas arise from melanocytes within the uveal tract [1]. Four cell types are recognized in choroidal and other uveal melanomas: spindle A, spindle B, epithelioid and mixed. The epithelioid cell type is usually the most aggressive, conveying a worse prognosis.

### **ESSENTIALS OF DIAGNOSIS**

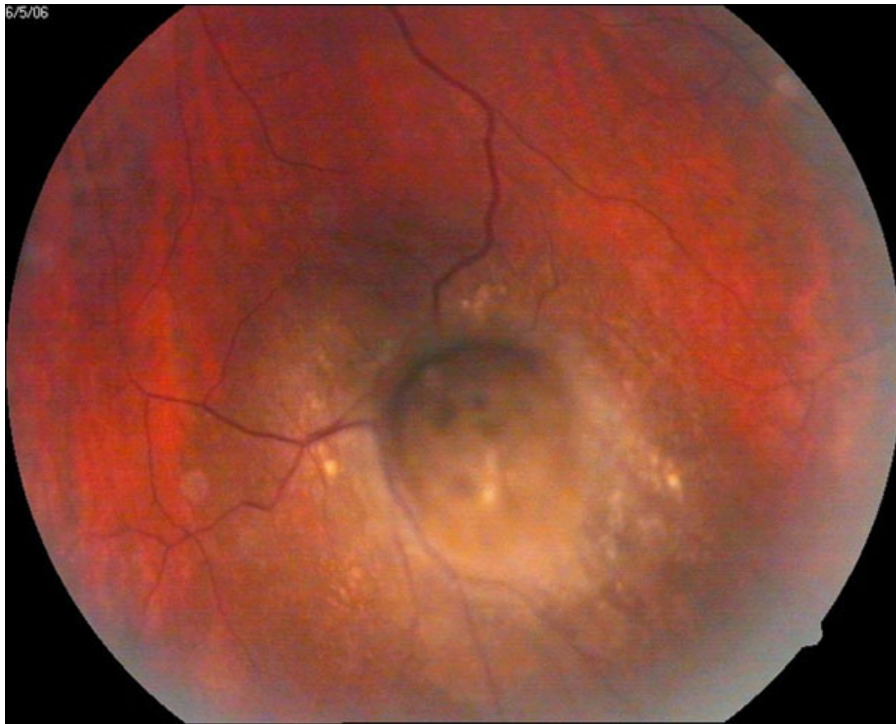
Choroidal melanoma appears as a pigmented (55%) (Figs. 1 and 2), nonpigmented (15%) (Figs. 3 and 4), or mixed pigmented (30%), elevated, oval-shaped mass [3, 4]. It may assume different configurations: dome-shaped (75%), mushroom-shaped (19%), or flat/diffuse (6%). It is often associated with subretinal fluid, orange pigment, and occasional subretinal or vitreous hemorrhage (Fig. 5) [3].

Choroidal melanomas may be asymptomatic for prolonged periods of time, and may be found incidentally during ophthalmoscopy. When symptomatic, they may cause photopsia, floaters, visual field loss, or visual acuity loss [2, 3].

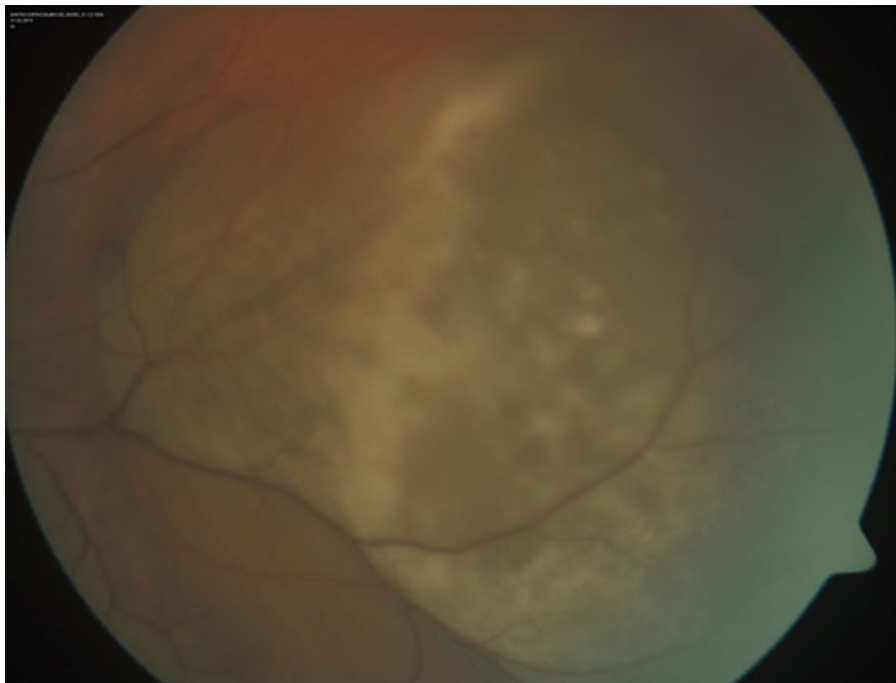
---

\* **Corresponding author Daniel Moreno Páramo:** Departamento de Oftalmología, Hospital General de Mexico, Dr. Balmis 148, Col. Doctores Del. Cuauhtémoc, 06726, México DF, Mexico City, Mexico; Tel/Fax: +52(55)65886715; Email: danomp@hotmail.com

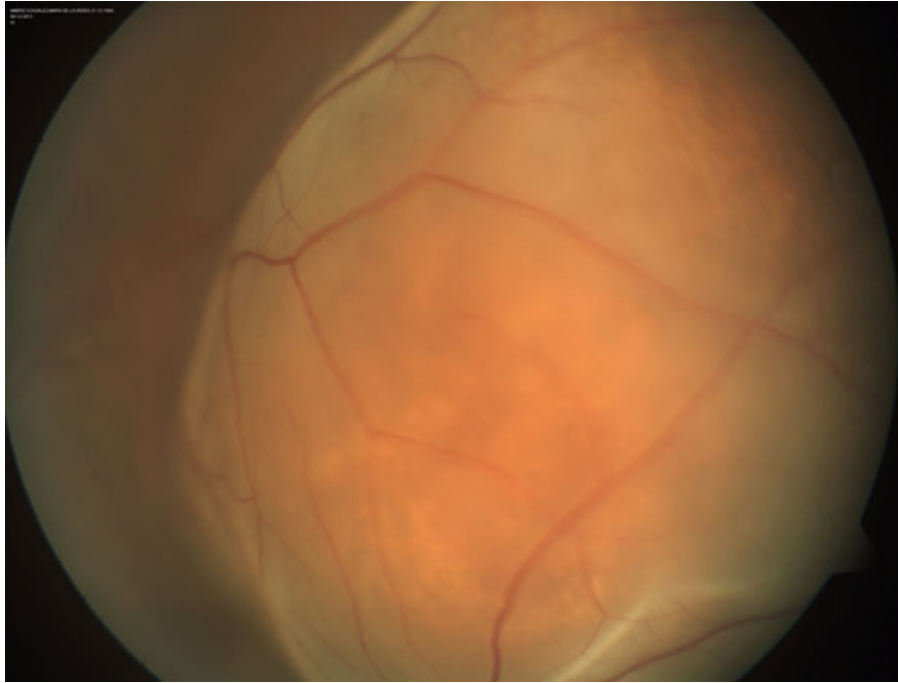




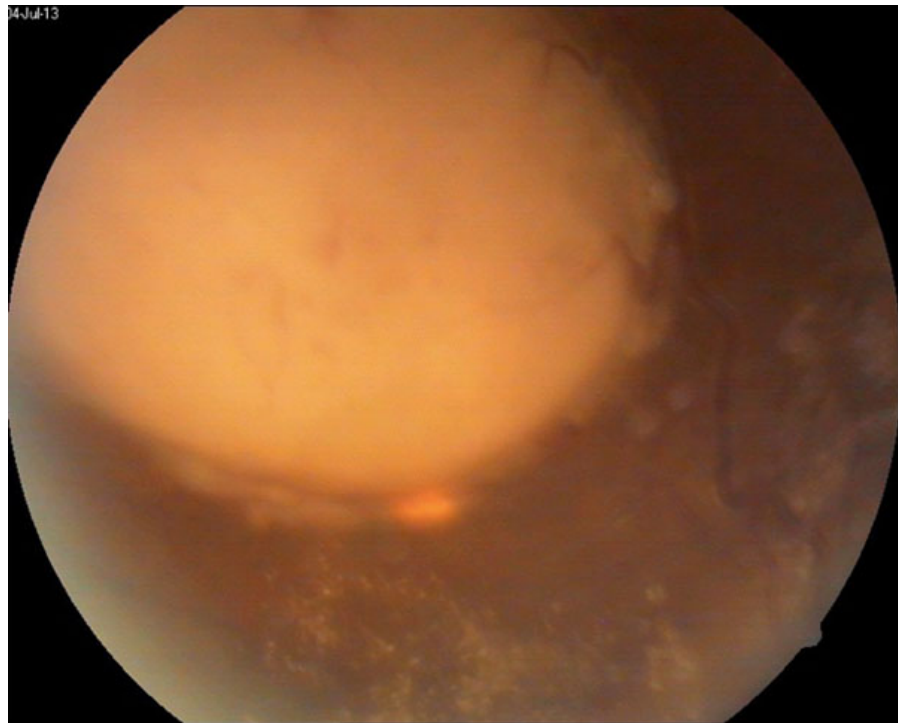
**Fig. (1).** Peripheral fundus photograph showing a pigmented subretinal mass surrounded by defects in the retinal pigment epithelium.



**Fig. (2).** Peripheral fundus photograph showing a large pigmented subretinal mass.



**Fig. (3).** Peripheral fundus photograph showing a large nonpigmented subretinal mass with surrounding subretinal fluid.



**Fig. (4).** Peripheral fundus photograph showing a large nonpigmented subretinal mass.



## Choroidal Metastasis

Jennifer F. Williamson\*

*Department of Ophthalmology, University of North Carolina, Chapel Hill, NC, USA*

Metastatic lesions are the most common malignancy of the eye, with the choroid as the most common location for ocular metastases. Choroidal metastases have been recorded in up to 12% of patients with solid tumors during necropsy [1]. Breast and lung cancers are most likely to metastasize to the choroid, but metastases have been reported with thyroid carcinomas, skin melanomas, gastrointestinal tumors, and pelvic cancers. There is a high rate of concurrent extra-ocular metastases in patients with choroidal lesions (37 to 86%), but up to 32% have no other metastatic lesions when ocular involvement is diagnosed [2].

### ESSENTIALS OF DIAGNOSIS

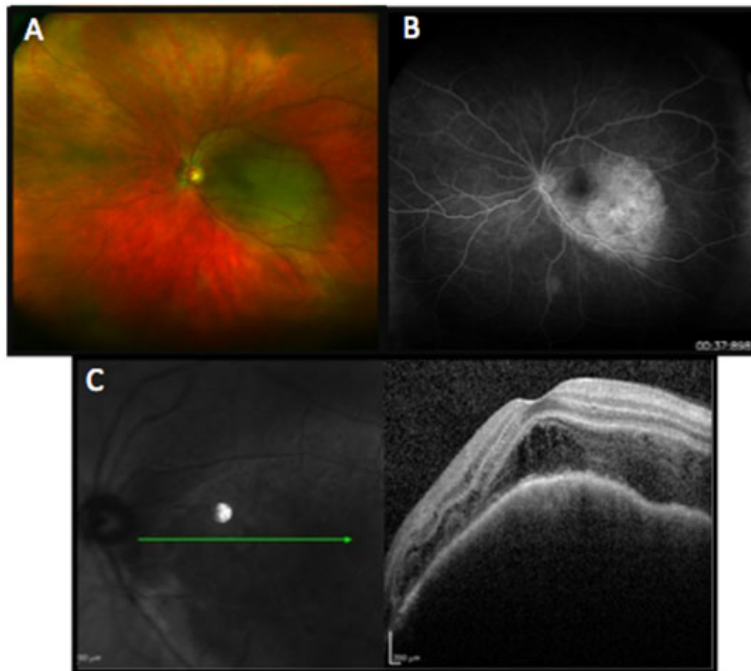
**Clinical features:** Symptoms include decreased visual acuity, scotoma, metamorphopsia, photopsia, floaters, and pain [2 - 4]. Patients may also be asymptomatic. The lesions are bilateral in 36 to 56% of patients at diagnosis [2]. The lesions appear as yellow subretinal masses in 94% of patients, and 73% are associated with subretinal fluid (Fig. 1A) [3, 5]. The lesions are single in most cases but may be multiple, and most are posterior to the equator [5]. Posterior uveitis, anterior uveitis, and conjunctival hyperemia have also been reported in association with choroidal lesions.

**Imaging:** On autofluorescence, the lesions appear hypoautofluorescent with overlying hyperautofluorescence corresponding to lipofuscin and subretinal fluid [6]. Ultrasonography shows medium to high internal reflectivity with A-scan and the height-to-base ratio is significantly lower than in melanomas [5, 7]. On fluorescein angiography, the lesions typically are hypofluorescent during the arterial and early venous phase, becoming hyperfluorescent in the late venous phase (later than in the case of choroidal hemangioma or melanoma) (Fig. 1B). They also often contain dilated retinal capillaries with pinpoint leakage at the

---

\* Corresponding author Jennifer F. Williamson: Department of Ophthalmology, University of North Carolina, Chapel Hill, NC, USA; Tel/Fax: (919) 920-4231; Email: jennifer.williamson@unchealth.unc.edu

border [4, 6, 8]. Optical coherence tomography may reveal a pattern of hyperintense irregular spots in the context of the photoreceptor layer and in the retinal pigment epithelium, subretinal fluid (Fig. 1C), and marked irregularity of the retinal pigment epithelium with thickening and gross undulation [9]. With MRI, a metastatic lesion may appear as a well-demarcated mass that is isointense on T1 and hypointense on T2 [10]. Fine needle aspiration biopsy can be used for diagnosis in the case of unidentified primary tumor [4].



**Fig. (1).** A 60-year-old female with a history of stage IV non-small cell lung adenocarcinoma treated with chemotherapy was referred for evaluation of a macular lesion noted on an examination for blurred vision of the left eye. Right eye visual acuity and examination was normal. Panel A shows a large yellow choroidal mass in the macula of the left eye on wide-angle fundus photography. Fluorescein angiography showed diffuse hyperfluorescence throughout the lesion with punctate hyperfluorescence on the margins (panel B). Macula OCT through the lesion revealed subretinal fluid (panel C). The patient was referred for external beam radiation therapy.

## DIFFERENTIAL DIAGNOSIS

1. Choroidal nevus
2. Amelanotic melanoma
3. Lymphoma
4. Choroidal hemangioma
5. Choroidal osteoma
6. Granuloma
7. Posterior scleritis

## MANAGEMENT

Therapy should be determined on an individual case basis based on the status of the systemic malignancy and location of the choroidal lesions. External beam radiotherapy is the most common treatment and has reasonable success, with regression in 53-93% of patients [3, 4, 11, 12]. Other reported treatments include gamma knife radiosurgery (GKR), proton beam radiotherapy, plaque brachytherapy, transpupillary thermotherapy, photodynamic therapy, and intravitreal injections of antiangiogenic agents. Successful results with gamma knife radiosurgery have been reported in 2 trials, with the larger study (57 patients) demonstrating a 63% response rate at 7 months [13, 14]. Proton beam radiotherapy was used in a trial composed of 63 patients, with 84% demonstrating regression [15]. Plaque brachytherapy was investigated in a study of 36 patients, and 94% of patients had regression lasting at least 11 months [16]. Transpupillary thermotherapy was employed in the study of 59 eyes with regression or inhibition of growth in 71% [17]. The use of anti-VEGF injections has been described in multiple case reports, and pooled analysis of 20 patients showed that intravitreal bevacizumab combined with systemic chemotherapy resulted in regression in 77% of patients [18]. Systemic treatments are often needed in addition to local therapy, especially in the case of bilateral, multifocal metastases [3, 4].

## CONFLICT OF INTEREST

The author confirms that author has no conflict of interest to declare for this publication.

## ACKNOWLEDGEMENTS

Declared none.

## REFERENCES

- [1] Siegel R, Naishadham D, Jemal A. Cancer statistics, 2012. *CA Cancer J Clin* 2012; 62(1): 10-29. [<http://dx.doi.org/10.3322/caac.20138>] [PMID: 22237781]
- [2] Demirci H, Shields CL, Chao AN, Shields JA. Uveal metastasis from breast cancer in 264 patients. *Am J Ophthalmol* 2003; 136(2): 264-71. [[http://dx.doi.org/10.1016/S0002-9394\(03\)00192-2](http://dx.doi.org/10.1016/S0002-9394(03)00192-2)] [PMID: 12888048]
- [3] Jardel P, Sauerwein W, Olivier T, *et al.* Management of choroidal metastases. *Cancer Treat Rev* 2014; 40(10): 1119-28. [<http://dx.doi.org/10.1016/j.ctrv.2014.09.006>] [PMID: 25451606]
- [4] Arepalli S, Kaliki S, Shields CL. Choroidal metastases: origin, features, and therapy. *Indian J Ophthalmol* 2015; 63(2): 122-7. [<http://dx.doi.org/10.4103/0301-4738.154380>] [PMID: 25827542]

## Leukemic Retinopathy

**Daniel Moreno Páramo\***, Stefanie Reyna Vielma and Griselda Vázquez Reyes

*Ophthalmology Department, Hospital General de Mexico, Mexico City, Mexico*

Leukemias are a group of malignant neoplastic disorders of white blood cells, characterized by a diffuse replacement of the bone marrow by neoplastic cells [1]. In these patients, retinopathy is a common finding that has been described in up to 50% of patients at the time of diagnosis [2]. In some cases, ocular findings can be the initial manifestation of the disease [3]. They present themselves more frequently in the acute forms than in the chronic forms, and it can be seen like a primary infiltrate in 3% of the patients and as secondary complications in 39% [4]. Retinal manifestations can occur in about 90% of patients with acute leukemia [5].

### ESSENTIALS OF DIAGNOSIS

Ophthalmic manifestations can be classified in two main categories: primary or direct leukemic infiltration and secondary or indirect infiltration.

Direct infiltration can show three patterns: anterior segment manifestations, orbital manifestations and neuro-ophthalmologic signs [1]. Secondary manifestations are the result of the associated hematologic abnormalities such as anemia, thrombocytopenia, hyperviscosity and immunosuppression [6]. These manifestations can be observed as retinal or vitreous hemorrhages, infections and vascular occlusions [1].

Frequently, ocular manifestations are asymptomatic [7]. Symptoms, when present, include decreased visual acuity, vitreous infiltration with leukemic cells and sudden unilateral vision loss [3].

Early retinal manifestations are vascular dilatation and tortuosity, retinal hemorrhages that may be dot-shaped or flame-shaped and frequently have a white

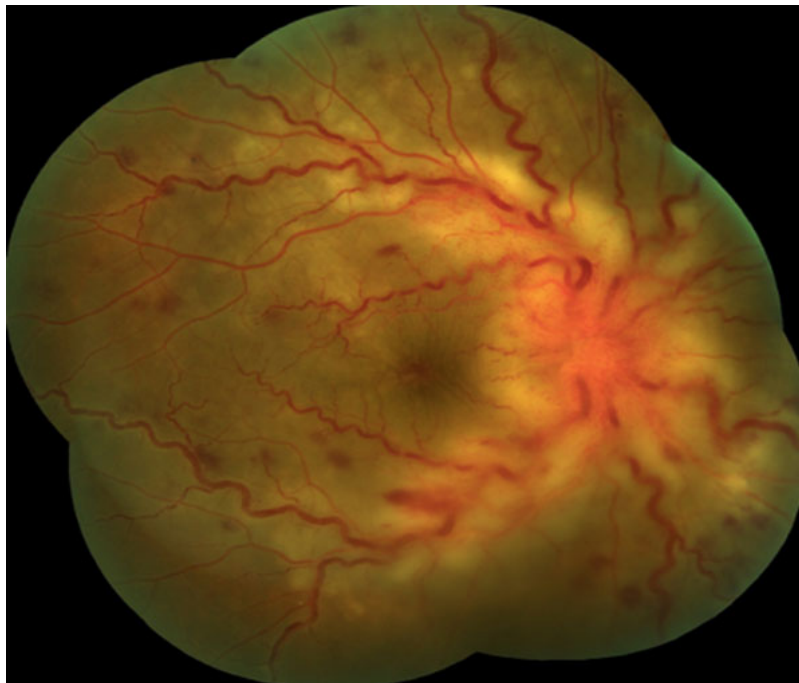
---

\* **Corresponding author Daniel Moreno Páramo:** Departamento de Oftalmología, Hospital General de Mexico, Dr. Balmis 148, Col. Doctores Del. Cuauhtémoc, 06726, México DF, Mexico City, Mexico; Tel/Fax: +52(55)65886715; Email: danomp@hotmail.com

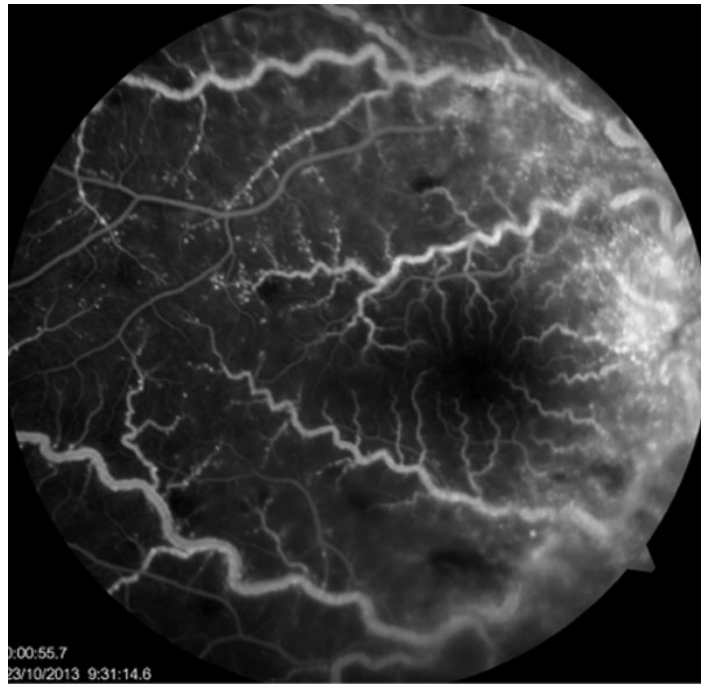
center (Roth's spots) [1]. Roth's spots are an unspecific sign caused by rupture of the retinal capillaries with cluster of leukemic cells, platelets, septic emboli or fibrin material in the center [8].

The hemorrhages and infiltrates can be present in all retinal layers, but especially in internal layers with focal destruction (Figs. 1-4) [5]. Leukemic large infiltrates can cause serous retinal detachments. Small infiltrates tend to be perivascular. Subretinal infiltration is referred to as subretinal hypopyon. Cotton-wool spots are thought to be secondary to ischemia, hyperviscosity or leukemic infiltration [1].

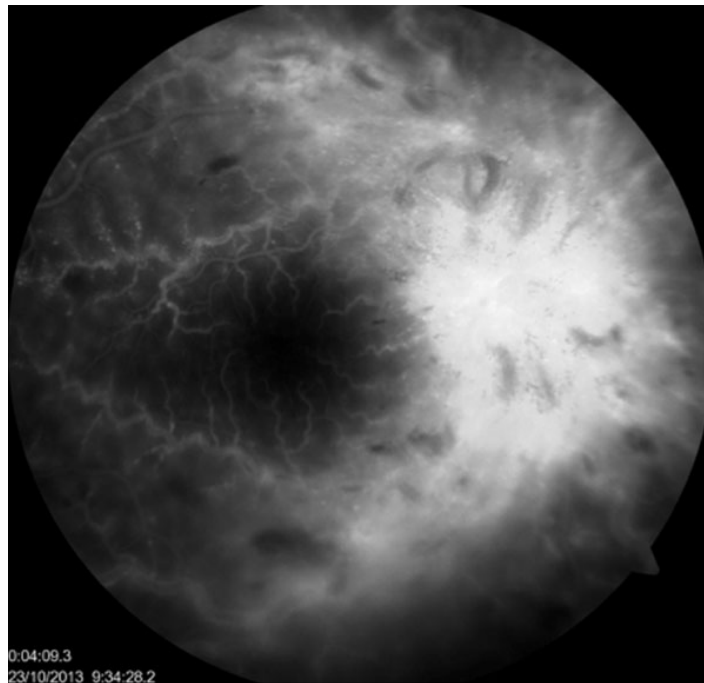
Peripheral retinal microaneurysms and retinal neovascularization may be seen [1]. The neovascularization is more common in chronic myelogenous leukemia [2]. Cases of central vein occlusion secondary to hyperviscosity associated to leukocytosis have been reported [4]. Serous retinal detachments are rare. They are associated with lymphoblastic invasion to choroid vasculature causing retinal pigment epithelium dysfunction that produces subretinal ischemia and accumulation of fluid [5]. The internal limiting membrane acts as a barrier against infiltration, but leukemic cells may infiltrate vitreous, possibly *via* the optic nerve head [1]. When the optic nerve is involved, it could be by direct infiltration or secondary to intracranial hypertension [1].



**Fig. (1).** Fundus photograph of a patient with diagnosis of Acute Myelocytic Leukemia, showing disc edema, vascular tortuosity, perivascular infiltration and dot-shaped hemorrhages.



**Fig. (2).** Early phase of a fluorescein angiogram of the same fundus as Fig. (1), showing vascular tortuosity, multiple microaneurysms and vascular hyperfluorescence.



**Fig. (3).** Late phase of a fluorescein angiogram of the same fundus as Fig. (1), showing leakage, especially in the vessels of the posterior pole.

## **Primary Intraocular Lymphoma**

**Amina L. Chaudhry and Debra A. Goldstein\***

*Northwestern University, Chicago, IL 60611, USA*

### **ESSENTIALS OF DIAGNOSIS**

Primary intraocular lymphoma (PIOL), also known as primary vitreoretinal lymphoma, a subset of primary central nervous system lymphoma (PCNSL), is a rare non-Hodgkin's lymphoma that involves the retina and vitreous. The majority of PIOL is diffuse large B-lymphoma, although rare T-cell variants have been described [1].

In the US, it is estimated that there are 300-380 new cases of PIOL annually [1]. Approximately 80% of PIOL patients eventually develop PCNSL and approximately 20% of PCNSL patients present with PIOL [1]. Clinically, PIOL typically presents in older patients, with median age of 60 years [1].

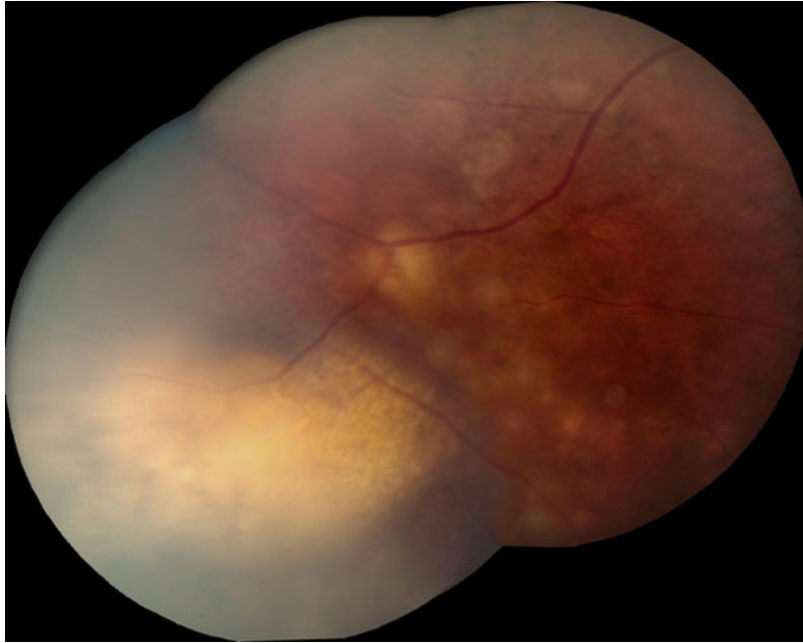Patients may present with blurred vision and/or floaters, but visual acuity is typically better preserved than would be expected for the degree of inflammation. Anterior segment signs are frequently absent, although cells in the anterior chamber and keratic precipitates may be seen. Rare cases may present with infiltration of the iris or angle, or with a pseudohypopyon. Fundoscopic exam reveals vitritis in the majority of cases. The vitreous cells may form clumps, sheets or strands, with mild to moderate haze [1]. White to orange infiltrates may be seen deep to the retina or RPE (Fig. 1), often imparting a characteristic "leopard skin" appearance (Fig. 2). Isolated subretinal lesions with associated exudative retinal detachment may also be seen. Cystoid macular edema is typically absent, in contrast to uveitis cases of similar cellularity. Optic nerve infiltration may occur.

Symptoms of CNS involvement may include behavioral changes, cognitive disorders, hemiparesis and/or ataxia. A strong indicator of CNS involvement is new-onset seizures [2].

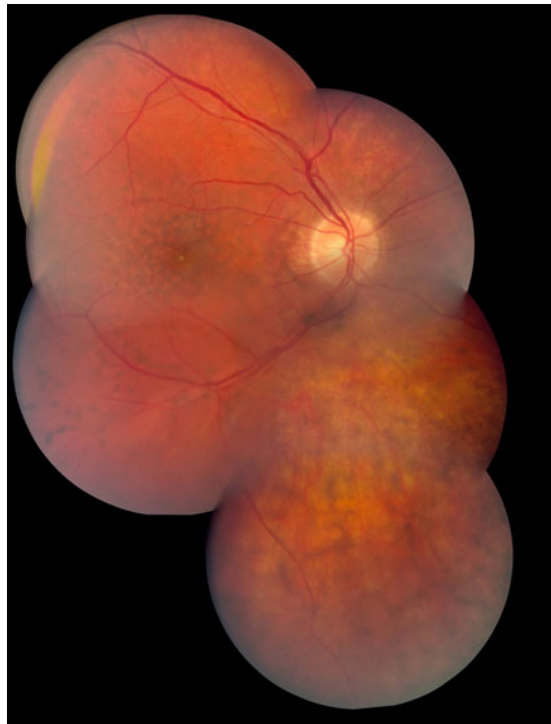---

\* **Corresponding author Debra A. Goldstein:** Northwestern University, Chicago, IL 60611, USA; Tel: (312) 9088152; Fax: (312) 5038152; Email: [debgold@yahoo.com](mailto:debgold@yahoo.com)





**Fig. (1).** Fundus photograph of a 53-year-old Caucasian male with PIOL. Note the large subretinal mass as well as numerous smaller lesions.



**Fig. (2).** Note the classic "leopard-like" appearance of the pigmentary changes in this patient with PIOL.

Fundus autofluorescence (FAF) may reveal a granular pattern, with hyperautofluorescent spots ranging from 50 to 250 microns alternating with adjacent hypoautofluorescent spots [3, 4]. Fluorescein angiography (FA) may demonstrate hypofluorescent round spots which correlate with the hyperautofluorescent spots on FAF [3]. Indocyanine green angiography typically shows small hypofluorescent lesions in the early phase, becoming less apparent in the late phases [2]. OCT findings include nodular hyper-reflective spots under the RPE, separation of Bruch's membrane from the RPE, disruption of the ellipsoid zone, hyper-reflective bands above the RPE and hyper-reflective signals in the retina [3, 4].

Ultrasonography can be used in cases of limited fundus view secondary to dense vitritis. Abnormal ultrasonographic findings are nonspecific and may include vitreous debris and retinal detachment.

Because PCIOL is closely related to PCNSL, it is imperative to evaluate the CNS. MRI with contrast is more sensitive than CT for detecting lymphomatous lesions in the CNS [5], but both have limited ocular value. Cerebrospinal fluid (CSF) evaluation is recommended despite a low yield for lymphoma cells in the CSF.

Diagnosis is typically made based on vitrectomy, although multiple biopsies may be required to arrive at a diagnosis [6]. It is recommended that for antibody determination, cytological evaluation and PCR an undiluted pure vitreous specimen be obtained by cutting and manually aspirating the specimen into a 3 cc syringe. For flow cytometry and cultures, diluted vitreous samples may be obtained after turning on the infusion and cutting the vitreous and aspirating into a 20 cc syringe. Diluted vitreous wash in the machine cassette may also be submitted for cytology [6, 7]. Communication with the cytologist/pathologist is recommended before obtaining the specimen. Occasionally, the vitreous does not have enough cellularity to make a diagnosis, and retinal biopsy may be required [6, 7].

Ocular cytological and histological exam reveals large lymphocytes, with large irregular nuclei, prominent nucleoli and scanty basophilic cytoplasm. Vitreous specimens may also contain reactive T-lymphocytes, necrotic cells and debris that may confound the identification of malignant cells. Biochemical and PCR analysis of vitrectomy specimens may assist in differentiating PIOL from chronic uveitis. IL-10 is elevated in the presence of malignant B lymphocytes, whereas IL-6 and IL-12 are elevated in inflammatory states. PIOL specimens may thus exhibit a high IL-10: IL-6 ratio ( $>1$ ) [1, 2]. Immunohistochemistry or flow cytometry demonstrate monoclonality, either B-cell (kappa or lambda light chain)

## **Idiopathic Uveal Effusion**

**Alberto Zambrano\***

*Fundación Zambrano, Buenos Aires, Argentina*

Idiopathic uveal effusion (IUE) is an extremely uncommon disease, characterized by abnormal accumulation of serous fluid in the cilio-choroidal space, usually associated with non-rhegmatogenous retinal detachment, with no obvious cause such as trauma, surgery or inflammation. The disease shows middle-aged male preponderance but has been also described in females and in ages 20 to 80. The relapsing-remitting courses often lead to severe visual loss, secondary to chronic submacular fluid with RPE changes [1,2].

There are several hypotheses in the pathogenesis of IUE. Pathologic studies showed in most of the cases an abnormally thick sclera, with irregular distribution of collagen fibers and deposition of proteoglycans, suggesting some form of ocular mucopolysaccharidosis. In these cases of scleral thickening, the main hypothesis is vortex vein compression or reduced scleral permeability. In patients with normal sclera, chronic hypotony or increased choroidal permeability of unknown etiology has been suggested as possible causes of the fluid accumulation [3 - 6].

### **ESSENTIALS OF DIAGNOSIS**

Patients consult for fluctuating vision or superior visual field defect, due to the exudative retinal detachment.

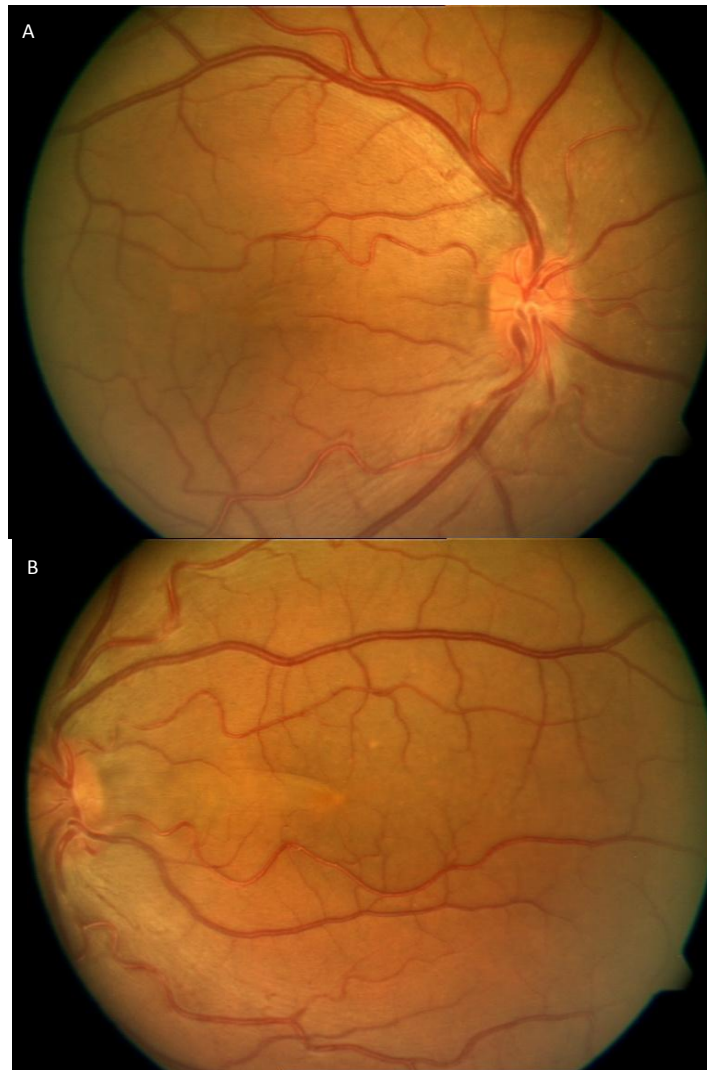At the exam, these eyes, frequently nanophthalmic, show a normal cornea, shallow anterior chamber, and dilated episcleral veins as well as blood in the Schlemm's canal. The latter two are probably signs of vascular congestion. There is no evidence of inflammatory signs.

Fundoscopy varies from a slight, anterior peripheral cilio-choroidal elevation to an annular choroidal detachment with bullous retinal detachment with shifting

---

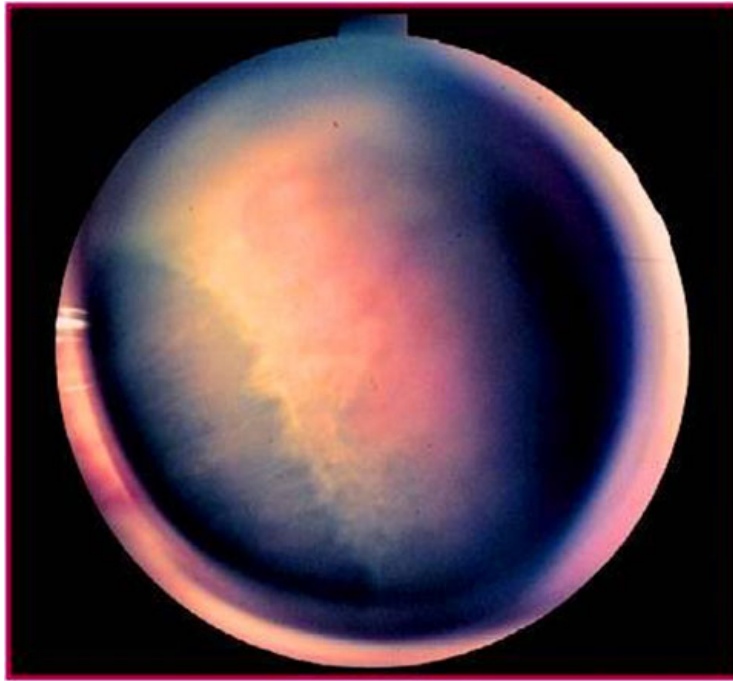
\* **Corresponding author Alberto Zambrano:** Fundación Zambrano, Buenos Aires, Argentina; Tel/Fax: +54 911 48131919; Email: info@fundacionzambrano.org

fluid and secondary RPE changes (Fig. 1). The ora serrata is usually easily visualized without indentation (Fig. 2) due to the peripheral effusion. The vitreous is clear. In patients with resolved retinal detachment, a patchy subretinal pigmentation has been described as leopard spots or pseudoretinitis pigmentosa.

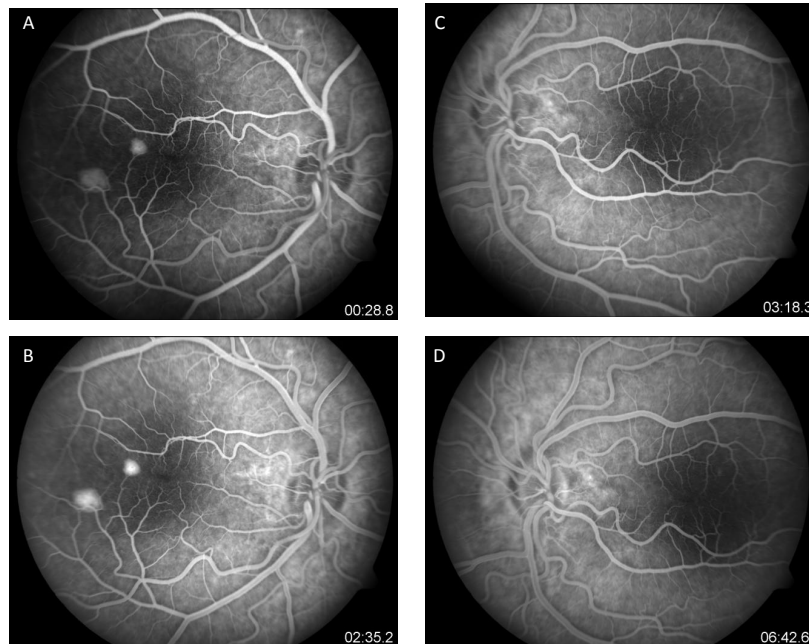


**Fig. (1).** A and B. 31-year-old male, presented with decreased visual acuity (0.3 in both eyes), nanophthalmia and high hyperopia (+17.00 D). Fundus photographs show bilateral serous retinal detachment, with shifting subretinal fluid and secondary RPE changes. (Courtesy of Mitzy E. Torres Soriano MD).

B-scan, UBM, and fluorescein angiography (Fig. 3) are useful tools in reaching an appropriate diagnosis, especially with choroidal tumors, and also to assess the scleral and choroidal thickening.



**Fig. (2).** Annular peripheral choroidal detachment: Pars plana is visible directly through pupil.



**Fig. (3).** The same patient of Figs. (1 and 2). **A** and **B** (Right eye): FA shows two hyperfluorescent points. **A**, **B**, **C** and **D**: FA revealed mild RPE changes and vascular congestion in both eyes. (Courtesy of Mitzy E. Torres Soriano MD).

## **Hypotony Maculopathy**

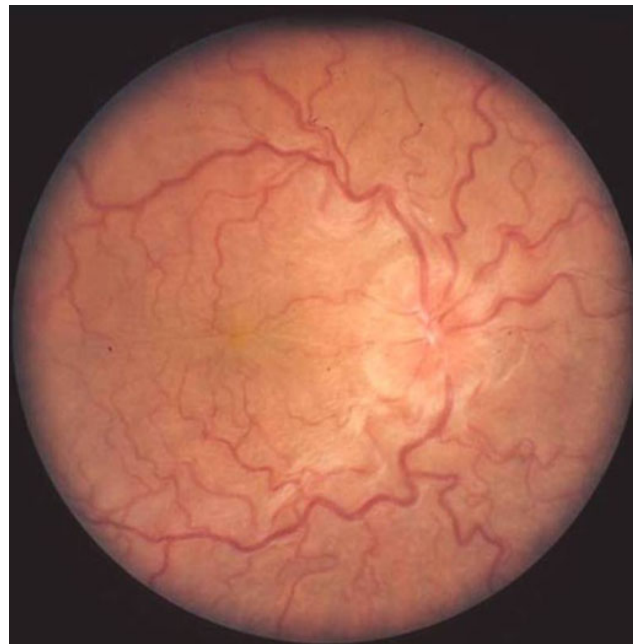**Alberto Zambrano\***

*Fundación Zambrano, Buenos Aires, Argentina*

### **ESSENTIALS OF DIAGNOSIS**

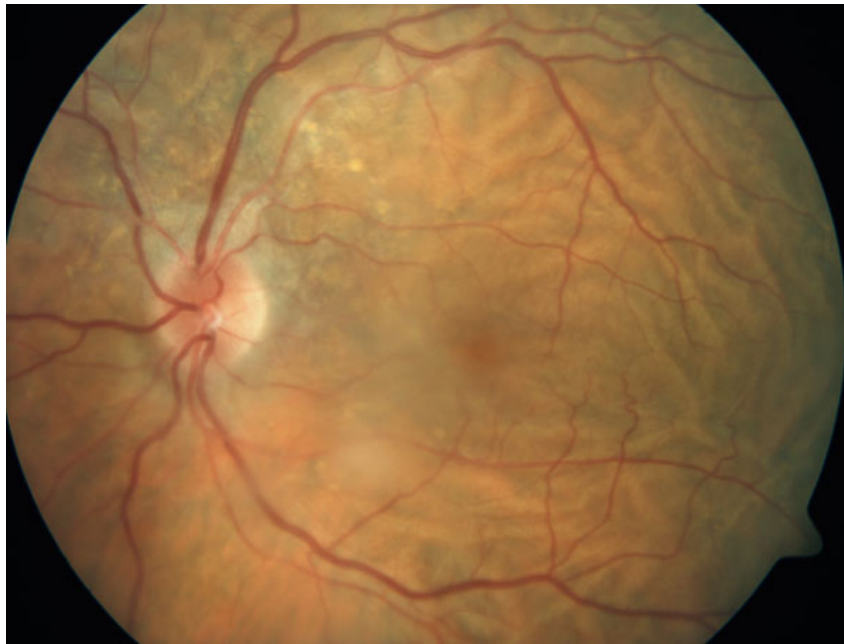Hypotension, defined as intraocular pressure (IOP) of less than 6.5 mm Hg, provokes scleral shrinking and inward bowing of the posterior pole, creating the characteristic aspect of this syndrome: hypotony, decreased visual acuity, disc swelling in early stages, vascular tortuosity (Fig. 1), chorioretinal folds (Fig. 2), mild cystoid macular edema, and hyperopic shift in refraction [1, 2].

Hypotony occurs under several conditions that unbalance the aqueous humor production/outflow ratio. Outflow may be excessive, as in over filtering blebs (the most common cause of the syndrome), wound leaks, and cyclodialysis cleft.



**Fig. (1).** Vascular tortuosity and disc swelling in the acute phase of hypotensive syndrome.

\* **Corresponding author Alberto Zambrano:** Fundación Zambrano, Buenos Aires, Argentina; Tel/Fax: +54 911 48131919; Email: drzambrano@fibertel.com.ar



**Fig. (2).** Chorioretinal folds. Traumatic hypotension. (IOP 2 mm Hg. VA 20/200).

Aqueous production can be significantly reduced due to ciliary body malfunction, as in tractional cyclitic membranes or ciliary body hypoperfusion in vascular occlusive diseases, diabetic coma or uremia.

Persistent hypotension results in chorioretinal changes and poor vision. Usually, the medical history of previous surgery or trauma and the clinical aspect lead to the diagnosis. However, sometimes auxiliary imaging could be useful, especially in mild cases. These are the most frequent ancillary tests:

**Fluorescein Angiography:** Shows capillary disc leakage in the acute phase and enhances the aspect of the choroidal folds, with alternating hypo- and hyper-fluorescent bands (Fig. 3), due to the folding of the RPE. This is useful to differentiate from pure retinal folds that do not alter background fluorescence [2].

**Optical Coherence Tomography:** Can help to detect subtle folds, difficult to see in ophthalmoscopy, as well as mild macular edema. Also serves to monitor the outcome of treatment [3].

**Ultrabiomicroscopy:** Useful for the evaluation of the position and integrity of the ciliary body, revealing traction or atrophy, as well as the presence and extent of cyclodialysis clefts [4, 5] (Fig. 4).



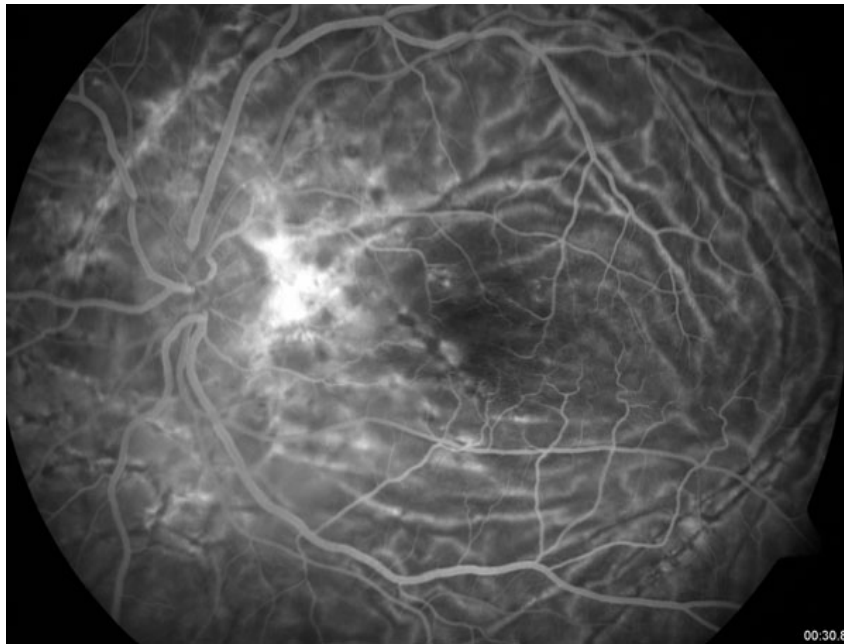


Fig. (3). Hypo- and hyperfluorescent bands.

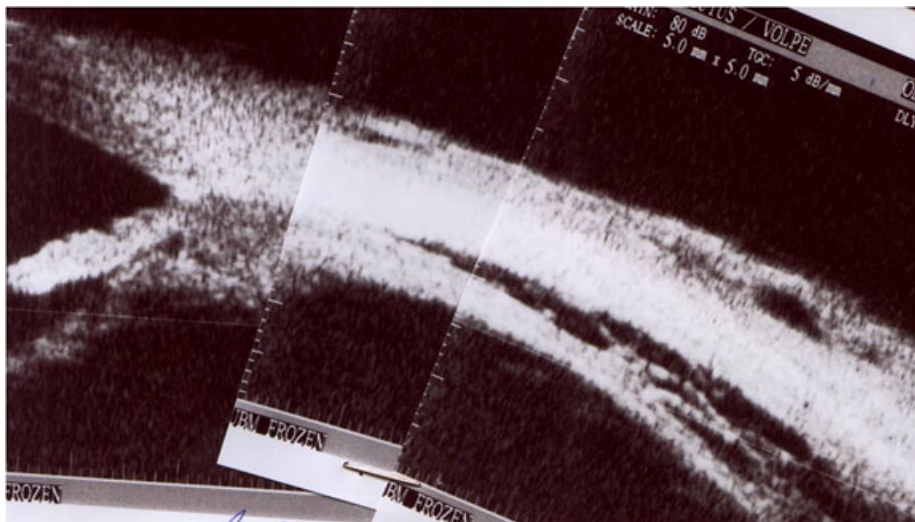


Fig. (4). Cyclodialysis cleft.

### DIFFERENTIAL DIAGNOSIS

In the acute phase, all causes of papilledema should be considered, but most frequently the diagnosis must be done with other causes of chorioretinal folds: idiopathic folds, usually bilateral and with good visual acuity; choroidal tumors, particularly melanoma and metastasis; retrobulbar mass; scleritis; shallow retinal detachment; and choroidal neovascularization or scarring.

## **Pregnancy-associated Retinal Diseases**

**Naty C. Torres Soriano<sup>1,2</sup> and Mitzy E. Torres Soriano<sup>1,3,\*</sup>**

<sup>1</sup> *Centro Médico Cagua, Unidad Oftalmológica “Dr. Torres López”, Cagua-Aragua, Venezuela*

<sup>2</sup> *Ophthalmology Department, Hospital Central de Maracay, Maracay, Venezuela*

<sup>3</sup> *Centro de la Visión Gordon-Manavella, Rosario, Argentina*

### **HYPERTENSION: PRE-ECLAMPSIA AND ECLAMPSIA**

Ocular changes occur in 30-50% of patients with eclampsia and in 20-25% of patients with pre-eclampsia, and they consist in visual disturbances such as scotoma, diplopia, loss of visual acuity. These may be signs of alert for seizures in patients with pre-eclampsia. The effects of eclampsia and pre-eclampsia occur at the level of the retina, the choroid and the optic nerve.

**Retinopathy in Toxemia:** The changes correspond to those of hypertensive retinopathy: arteriolar spasms in 40-100% of patients with pre-eclampsia [1] (which are reversible in the postpartum period); diffuse narrowing (also reversible); and also hemorrhages, soft exudates, diffuse macular edema and papilledema may occur more frequently in women with chronic hypertension diagnosed before pregnancy [2]. These would indicate placental insufficiency, since the severity of retinal changes correlates with higher perinatal mortality rates. Therefore, induction of labor is recommended in cases of severe retinopathy. Inducing labor at the right time not only can improve the chances of survival for a baby born prematurely, but also can improve the outcome of systemic changes in the mother.

**Localized Choroidal Infarction and Infarction of the RPE:** Elschnig spots are one of the most common changes in toxemia. Choroidal insufficiency is a frequent ocular complication in patients with pre-eclampsia and eclampsia. Clinically, it presents as serous retinal detachments or yellow lesions at the level of the RPE [3, 4].

**Retinal Detachment in Toxemia:** It is a serous, exudative detachment that is

---

\* **Corresponding author Mitzy E. Torres Soriano:** Centro de la Visión Gordon-Manavella, Montevideo 763, Rosario-Argentina; Tel: +54(341) 4400239; Email: mitzytorres@yahoo.com

usually bilateral and bullous. When the macula is not involved, it can be asymptomatic [3, 4]. It presents in 10% of patients with eclampsia and in 1-2% of patients with pre-eclampsia. It is not associated to fetal risk and it usually resolves after delivery. Macular RPE changes or optic atrophy only occur exceptionally or in rare cases, and lead to permanent loss of visual acuity.

Cases of temporary cortical visual impairment, serous bilateral retinal detachment [5] which resolves after 48 hours, unilateral vitreous hemorrhage and reversible blindness associated with cerebral venous sinus thrombosis and central retinal vein thrombosis have been identified in association with Hellp syndrome (hemolysis, elevated liver enzymes and low platelet count) in women with severe pre-eclampsia or eclampsia presenting on the 3rd trimester of pregnancy or in the postpartum period.

### **DIABETIC RETINOPATHY**

Keeping glycemia and glycated hemoglobin (HbA1c) levels under control before conception and during pregnancy can reduce the risk of miscarriage [6, 7], birth defects and perinatal morbidity. Also, the status of retinopathy in diabetic women should be assessed and determined before conception. This is particularly important in the case of patients with severe nonproliferative or proliferative retinopathy, since laser photocoagulation can reduce progression during pregnancy [8]. Laser treatment of diabetic macular edema before pregnancy may be recommended, although the effects of pregnancy on macular edema have not been appropriately studied yet.

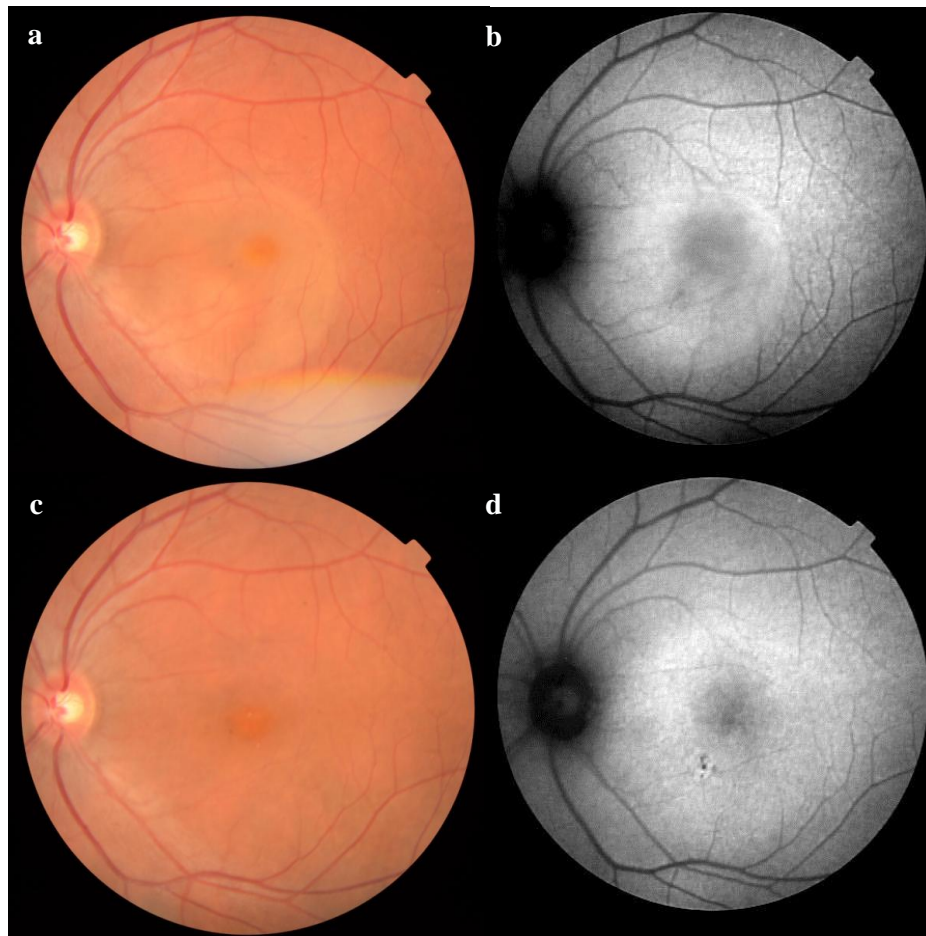
Progression of diabetic retinopathy in pregnant women depends mainly on the duration of diabetes and the severity of retinopathy at the beginning of pregnancy [8 - 11]. The baseline severity of retinopathy at the beginning of pregnancy is the main risk factor for the progression of the disease, according to the *Diabetes in Early Pregnancy Study (DIEP)*. Women with a HbA1c level of more than 6 standard deviations (SD) above the control mean are at higher risk of progression of retinopathy in comparison to patients with a HbA1c baseline level within 2 SD of the control mean.

### **CENTRAL SEROUS CHORIORETINOPATHY**

Central serous chorioretinopathy (CSCR) is caused by localized RPE dysfunction resulting in the accumulation of subretinal fluid (Figs. 1 and 2). It is more frequent in men between 20 and 50 years old. Pregnant women are more likely to develop CSCR.

In general, pregnant women with diabetic macular edema should not receive treatment during pregnancy since there is a high rate of spontaneous regression postpartum. Possible exceptions may include cases in which the fovea is threatened by fluid or severe progressive macular edema presents at the beginning of pregnancy [12].

CSCR associated to pregnancy may present at any stage in normal pregnancy, although it is more frequent in the third trimester, and it usually resolves in the postpartum period, leaving some subtle mottling of the RPE. It may recur in a future pregnancy. It has been associated to hormonal or hemodynamic changes, reduced osmotic pressure and hypercoagulable states [13].



**Fig. (1).** **a** and **b**) Fundus photograph and autofluorescence image showing typical central serous chorioretinopathy in left eye in sixth month of first pregnancy. **c** and **d**) Fundus photograph and autofluorescence after complete resolution. (Courtesy of Manuel Torres MD, Cagua, Venezuela).

## SUBJECT INDEX

### A

Active lesions, yellow-white 117  
 Active lesions in PIC 101  
 Acute macular neuroretinopathy 85  
 Acute-onset postoperative endophthalmitis 57, 58, 61, 71  
 Acute posterior multifocal placoid pigment epitheliopathy (APMPPE) 79, 80, 81, 82, 83, 91, 111, 112, 116, 121, 137, 233  
 Acute retinal necrosis (ARN) 21, 25, 26, 27, 29, 37  
 Acute uveitic stage 133, 134  
 Acyclovir 28  
 Amikacin 75, 76  
 Amphotericin 75, 76  
 Angiomatous lesions 163  
 Anterior chamber inflammation 29, 30, 91, 111  
 Anterior chamber irrigation 57, 63  
 Anti-TB treatment (ATT) 16  
 Areas 28, 118, 119, 124, 125, 128, 202  
   atrophic 118  
   endemic 128  
   macular 28, 119, 124, 125, 202  
 Atrophic lesions 23, 96, 97, 98, 102, 119  
   adjacent 97, 98  
 Atrophy, chorioretinal 3, 117, 119, 133  
 Azathioprine 25, 99, 112, 127, 142, 147

### B

Bacillus, tubercle 9, 10  
 Behcet's disease 30, 131, 146  
 Bilateral disease 30  
 Birdshot chorioretinopathy 91, 112  
 Birdshot retinopathy 98, 233  
 Bruch's membrane 101, 102, 124, 232

### C

Capillary closure 180  
 Capillary hemangiomas 157, 160, 184  
 Cat-scratch disease 48, 51  
 Ceftazidime 63, 75, 76

Cells 11, 13, 82, 139, 140, 224, 225  
   inflammatory 11, 13, 82, 139, 140  
   leukemic 224, 225  
 Cellularity 230, 232  
 Chemotherapy, systemic 153, 222, 227, 233  
 Chorioretinal lesions 69, 73, 114, 119  
   circumscribed 73  
   peripheral 144  
 Chorioretinal scars 21, 22, 85, 154  
 Chorioretinitis, posterior placoid 33, 40  
 Choroidal hemangioma 210, 218, 220, 221, 227  
 Choroidal hyper-reflectivity 96, 97  
 Choroidal lesions 10, 95, 97, 105, 106, 107, 112, 123, 125, 182, 208, 220, 222  
   bilateral multiple pigmented 208  
   hypopigmented 105  
   inactive atrophic 95  
   multifocal 95  
   multifocal discrete 10  
   showing inactive atrophic 97  
   yellow 123  
 Choroidal lesions coalesce 123  
 Choroidal mass 206, 209, 210, 211, 217  
 Choroidal melanocytic lesion 207, 209, 210, 211  
 Choroidal melanoma, amelanotic 184  
 Choroidal neovascularization 4, 85, 101, 119, 121, 123, 125, 129, 189, 194, 202, 243  
 Choroidal neovascular membranes 98, 99, 105, 121, 144, 168  
 Choroidal thickening 236, 238  
 Choroidal tubercles 10, 12, 14  
 Choroidal tuberculoma 11  
 Choroidal tumors 236, 238, 243  
 Choroiditis 10, 13, 116  
 Classic CHRPE lesions spawn 198  
 Clindamycin 7, 76  
 CMV lesions 21  
 CMV retinal lesions 18  
 CMV retinitis 18, 20, 21, 22, 29  
 Coagulase-negative staphylococci (CNS) 29, 33, 65, 79, 232, 233  
 Color fundus photographs 80, 81, 109, 173, 203  
 Complement treatment 131  
 Composite photograph 177, 179

Confetti skin lesions 172  
 Confluent lesions, multiple 30  
 Convalescent stage 133, 134, 135, 136  
 Corneal wound abscess 56, 58, 71  
 Corticosteroids 7, 25, 28, 81, 83, 99, 112, 121, 142  
   systemic 25, 28, 112, 121, 142  
 CT for detecting lymphomatous lesions 232  
 Cutaneous melanoma 208  
   metastatic 208  
 Cyclosporine 107, 108, 112, 127, 142, 147  
 Cystoid macular edema (CME) 94, 99, 101, 104, 123, 141, 142, 144, 166, 168, 177, 181, 184, 186, 230, 241

**D**

Degeneration, age-related macular 207, 210  
 Depigmented lacunae 195, 198, 199  
 Detecting lymphomatous lesions 232  
 Diabetic retinopathy 46, 51, 168, 227, 250  
 Different-sized angiomas 161, 162  
 Disease 98, 142, 176, 211, 218  
   infectious 98, 142  
   metastatic 211, 218  
   vascular 176  
 Disease progression 101  
 Disseminated chancroid lesions 40  
 Disseminated intravascular coagulation (DIC) 253

**E**

Eclampsia 249, 250  
 Electroretinogram 123, 130  
 Electroretinography 109, 129  
 Endogenous endophthalmitis 53, 54, 72, 69, 68, 73, 76  
 Endophthalmitis vitrectomy study (EVS) 75  
 Epstein-Barr virus (EBV) 25  
 Exogenous endophthalmitis 53, 55

**F**

Familial adenomatous polyposis (FAP) 195, 199  
 Fibrotic tissue 124, 125

Flow cytometry 232  
 Fluorescein angiogram (FA) 11, 12, 13, 14, 28, 40, 80, 81, 82, 88, 89, 96, 120, 146, 150, 157, 161, 165, 180, 181, 185, 191, 192, 217, 218, 226, 232, 237  
 Fluorescein angiography 12, 14, 28, 48, 80, 82, 88, 89, 96, 101, 106, 107, 108, 109, 110, 119, 125, 130, 141, 144, 157, 158, 165, 179, 184, 199, 202, 204, 216, 217, 220, 221, 232, 236, 242  
 Foscarnet 22, 28  
 Fungal lesions 16

**G**

Gamma knife radiosurgery (GKR) 222  
 Ganciclovir 22, 23  
 Granuloma 10, 14, 15, 221  
 Grayish-white evanescent lesions 128  
 Gray-white lesions 128, 130  
 Green angiography 11, 12, 13, 80, 89, 216, 232

**H**

Hamartomas 172, 194, 195  
 Hemorrhages 3, 19, 20, 130, 152, 157, 184, 225, 228, 238, 249  
 Herpes simplex virus (HSV) 7, 25, 51  
 HIV infection 16  
 Horizontal OCT scan 97, 98  
 Hyperautofluorescent lesions 90  
 Hyperfluorescent lesions 38, 88, 89  
   early 89  
   multifocal 89  
 Hyper-reflectivity, nodular 82, 83  
 Hypertensive retinopathy 51, 249  
 Hyperviscosity 43, 224, 225, 227  
 Hypoautofluorescent lesions 90  
 Hypofluorescent lesions, early 88, 89  
 Hypotony 23, 241, 244

**I**

Idiopathic uveal effusion 235, 237, 239  
 Immunosuppressive agents 121, 127, 137  
 Inactive atrophic lesions 95  
 Inactive lesions 94

Inactive peripapillary CNV 97, 98  
 Indocyanine 11, 12, 80, 89, 216, 232  
 Infectious keratitis 9, 53, 67  
 Inflammation, progressive unilateral  
   intraretinal 27  
 Inflammatory cells 10  
 Inflammatory lesions 89  
 Intermediate hypofluorescent lesions 89  
 Intermediate uveitis 10, 139, 142, 176  
 International classification of retinoblastoma  
   149, 153  
 Intraocular inflammation 53, 98, 101, 102, 104,  
   108, 137, 199  
 Intraocular TB 10  
 Intraretinal hemorrhages 43, 174  
 Intra-retinal lesions 30  
 Intravenous administration 22  
 Intravitreal injections 23, 28, 75, 186, 205, 222  
 Intravitreal therapy 76  
 Iodine radiotherapy plaque 218  
 Isolated subretinal lesions 230  
 Isoniazid 16

**J**

Jarisch-Herxheimer reaction (JHR) 41

**K**

Keratoplasty 63, 64  
*Klebsiella spp* 54

**L**

Laser photocoagulation 22, 29, 131, 168, 184,  
   185, 250  
 Laser thermotherapy 153  
 Lesions 103, 110, 112, 121, 133, 137, 174, 189,  
   191, 193, 195, 196, 197, 199, 202, 203,  
   221, 232  
   bilateral 121  
   characteristic 133  
   distinctive 112  
   hyperpigmented 195, 203  
   hypo-fluorescent 232  
   hypopigmented 110  
   macular 221

  metastatic 220, 221  
   mulberry-like 174  
   non-calcified 174  
   pigmented 189, 191, 193, 195, 196, 197, 199  
   placoid 137  
   sectioned 103  
   unilateral 202  
 Light perception (LP) 29, 76  
 Lyme disease 51, 142  
 Lymphoma, primary vitreoretinal 91, 111, 112,  
   230  
 Lymphoma cells 232, 233

**M**

Macular edema 33, 36, 37, 105, 107, 109, 112,  
   127, 164, 174, 202, 242, 250  
   cystic 36, 37  
   diabetic 250, 251  
 Macular granularity 86, 88  
 Macular involvement 3, 27, 81, 83, 184  
 Macular star 11, 13, 36, 48, 50, 51  
 Malignant transformation 189, 194, 211  
 Mass, large nonpigmented subretinal 215  
 Massive lesions 169  
 Melanocytic choroidal lesion, flat 206  
 Melanomas 193, 206, 211, 213, 218, 220, 243,  
   252  
   uveal 213, 218, 252  
 Membrane, subretinal neovascular 95, 96  
 Metastases 220, 227, 238, 243, 252  
 Methylprednisolon 76  
 Miliary tuberculosis 10, 13  
 Mucopurulent conjunctivitis 9, 10  
 Multifocal deep lesions 111, 112  
 Multifocal lesions 10, 199  
 Multifocal posterior necrotizing retinitis  
   (MPNR) 27  
 Multiple evanescent 85, 86, 111  
 Mycophenolate mofetil 108, 112, 142, 147

**N**

Necrotic lesions 27  
 Nephrotoxicity 22, 23  
 Nerve fiber layer 43, 130, 131  
 Neuro-ophthalmologic signs 224



Neurosensory retina 15, 199, 252  
 Neurosyphilis 33, 41  
 Nummular lesions 135

## O

Occlusive vasculitis 27, 28, 29  
 OCT scans 12, 15, 166  
 Ocular histoplasmosis syndrome (OHS) 91, 103, 127, 131  
 OHS lesions 103  
 Ophthalmologic findings 86  
 Ophthalmoscopic features 79  
 Optical coherence tomography (OCT) 40, 48, 69, 80, 82, 87, 90, 107, 109, 120, 130, 131, 141, 144, 167, 168, 181, 182, 191, 192, 199, 202, 206, 209, 210, 216, 221, 238, 242, 252  
 Optical neuritis 36, 37  
 Optic disc inflammation 5, 85, 109  
 Oral valacyclovir 28, 29

## P

Panophthalmitis 53, 54, 56  
 Panuveitis 27, 33, 85, 91, 94, 104, 111, 144  
 Papilledema 51, 161, 162, 163, 243, 249  
 Papillitis 3, 12, 18, 27, 30, 49, 80, 108, 128  
 Pars plana vitrectomy 23, 75, 76, 187  
 Penetrating trauma (PT) 76  
 Peripapillary scarring 96, 97  
 Peripheral angiomas 161, 164, 168  
 Peripheral fundus photograph 196, 214, 215  
 Peripheral lesions 30, 116, 160  
 Peripheral retina 25, 27, 30, 123, 139, 174  
 Perivascular hyperfluorescence 141  
 Phacoemulsification 56, 59, 60, 61  
 Photoreceptors 82, 91, 96, 101, 199  
 PIC lesions 101, 103, 104  
   preventing recurrent 104  
 Pigmentation, intense 193, 194  
 Pigmented melanocytic lesion 207  
 Pigmented subretinal mass, large 214, 216  
 Pigment migration and serous retinal detachment 135  
 Poliosis 133, 136  
 Polymerase chain reaction (PCR) 7, 16, 28, 232

Postoperative endophthalmitis (PE) 53, 54, 62, 74, 77  
 Postpartum period 249, 250, 251  
 Post-traumatic endophthalmitis 53, 64, 76  
 Presumed tuberculous 12  
 Primary central nervous system lymphoma (PCNSL) 230, 232, 233  
 Progressive outer retinal necrosis (PORN) 21, 25, 27, 29  
 Proliferation, bilateral diffuse uveal 208  
*Pseudomona aeruginosa* 61, 62  
 Pulmonary TB 9  
 Punctate inner choroidopathy 103

## R

Radiotherapy 227, 228  
 Retinal angiography 35, 38  
 Retinal angioma 165, 166  
 Retinal astrocytoma 168, 174  
 Retinal detachment 4, 11, 21, 23, 25, 29, 63, 123, 133, 144, 163, 165, 168, 177, 202, 205, 218, 232, 235, 238, 243, 249  
   exudative 11, 133, 235  
   rhegmatogenous 21, 23, 238  
   shallow 177, 243  
   tractional 163, 165  
 Retinal exudation 130, 163  
 Retinal fluorescein angiography 141  
 Retinal hemangioblastoma 160, 163  
 Retinal hemorrhages 30, 45, 158, 224  
 Retinal inflammation 3, 35  
 Retinal layers 15, 18, 25, 33, 97, 102, 129, 157, 163, 167, 176, 225  
   inner 97, 157  
   outer 97, 102, 163, 167  
 Retinal lesion, solid 176  
 Retinal lesions 18  
   active 129  
   outer 25, 33  
 Retinal necrosis 18, 21, 25, 27, 28, 29  
   progressive outer 25, 27, 29  
 Retinal neovascularization 105, 225  
 Retinal periphery, superotemporal 176, 178  
 Retinal pigmentary epithelium (RPE) 40, 79, 82, 83, 85, 89, 91, 94, 96, 97, 101, 102,

103, 116, 117, 119, 195, 199, 202, 210,  
218, 230, 232, 242, 249, 251, 252  
Retinal tumor 167  
Retinal vasculitis 4, 10, 28, 33, 80, 105, 108,  
128  
Retinal whitening 19, 20  
Retinitis 10, 18, 28, 29, 30, 34, 36, 37, 38, 39  
  multifocal 29, 38  
Retinochoroidal lesions 3, 85  
  deep 85  
Retinochoroiditis 12, 21  
  toxoplasmic 21  
Retinopathy 147, 168, 224, 227, 249, 250  
  proliferative 147, 250  
  sickle cell 168, 227  
Retinoschisis 167  
Rhegmatogenous 4, 29  
Rifampin 16  
Right eye fundus photograph 12, 13  
Right eye syphilitic macular retinitis 39  
RPE and serous retinal detachment 253

## S

Satellite lesions 19, 30  
Scleral flap 238, 244, 246  
Scleral resection 238, 239  
Scleritis, posterior 111, 137, 144, 221, 238  
Sclerotomy 239  
Scotomas 18, 79, 81, 220, 249  
Secondary syphilis rash 39, 40  
Seeding, subretinal/vitreous 150  
Serous chorioretinopathy, central 127, 227,  
250, 251  
Serous retinal detachments 4, 80, 101, 130,  
133, 134, 135, 137, 162, 177, 184, 225,  
227, 249, 253  
Subretinal exudation 184, 199  
Subretinal fibrosis 95, 97, 117, 123, 124, 125,  
126, 127, 129  
Subretinal fluid 10, 11, 12, 13, 14, 15, 39, 40,  
48, 82, 94, 97, 101, 123, 133, 149, 150,  
161, 164, 166, 182, 183, 189, 192, 194,  
204, 206, 207, 209, 210, 211, 213, 215,  
220, 221, 236, 250  
  clear 149  
  scarce 182

  shifting 236  
  surrounding 183, 215  
  turbid 123  
Subretinal hemorrhage 190, 191, 216  
Subretinal lesions 101, 123, 137  
  multifocal progressive fibrotic 123  
  multiple 101  
Subretinal seeding 150  
Subretinal space 90, 101, 130, 149, 165, 167  
Sulfadiazine 7  
Suprachoroidal space 238, 239  
Surface, hyper-reflective internal 192  
Sympathetic ophthalmia 16, 91, 98, 111, 137,  
233  
Syphilitic retinitis 36  
Syphilitic retinitis mimicking 37

## T

Therapy 16, 18, 83, 104, 112, 137, 147, 168,  
184, 218, 222  
  active antiretroviral 16, 18  
  immunosuppressive 83, 104, 112, 137, 147  
  photodynamic 168, 184, 218, 222  
Toxic anterior segment syndrome (TASS) 70,  
71  
Toxoplasmosis 3, 4, 7, 16, 50, 51, 91, 126, 131,  
142, 146, 168  
  outer retinal 4, 7  
Transpupillary thermotherapy 168, 218, 222  
Tuberculin skin test (TST) 12, 13, 16  
Tuberous sclerosis 172, 173  
Tuberous sclerosis complex (TSC) 172, 174  
Tumors 151, 164, 168, 176, 202, 207, 211, 216  
  acquired vasoproliferative retinal 168  
  choroidal melanocytic 211  
  endophytic 151, 164  
  macular 202  
  peripheral vascular 176  
  reactive retinal astrocytic 176  
  whitish subretinal 151  
Tumor thickness 207, 216

## U

Ultrabiomicroscopy 182, 183  
Ultrasonography 192, 199, 206, 216, 220, 232

**V**

Vancomycin treatment 66

Varicella-zoster virus (VZV) 25, 28

Vascular congestion 235, 237

Vascular tortuosity 202, 225, 228, 241

Vasculitis 3, 27, 30, 50, 79, 141, 144

Vitreous biopsy 67, 74

Vitreous cavity 149, 152

Vitreous cells 18, 85, 94, 95, 123, 230

Vitreous haze 80, 95, 96, 108, 133

Vitreous hemorrhage 144, 151, 157, 159, 163,  
168, 176, 177, 178, 184, 202, 205, 213,  
224

Vitreous seeding 151, 152

Vitreous specimens 28, 232

VKH syndrome 82, 91, 111



### **Mitzy E. Torres Soriano**

---

Dr. Mitzy E. Torres Soriano graduated with honors in medicine at the University of Carabobo, Maracay, Venezuela in 2001. Then in 2003 she began her postgraduate studies in Ophthalmology in Hospital Miguel Pérez Carreño (Caracas, Venezuela) where she also served as Chief Resident, and completed them in 2005. From 2006 to 2008, she did a fellowship in Retina and Vitreous in Asociación para evitar la Ceguera. Hospital Dr. Luis Sánchez Bulnes, in Mexico. She dedicates her clinical practice to the medical and surgical treatment of retinal and vitreous diseases.

She has taken many courses and attended numerous congresses on ophthalmology, and has also written various articles and book chapters. She provides review services to several science international journals about ophthalmology and contributes in retinal clinical research.



### **Gerardo García-Aguirre**

---

Dr. Gerardo García-Aguirre graduated magna cum laude, obtaining his medical degree at the School of Medicine, Tecnológico de Monterrey, in Monterrey, Mexico in 2002, and his residency in Ophthalmology and Retina fellowship at Asociación para Evitar la Ceguera en México, in Mexico City. In 2008 he became an attending physician at the same hospital. He is author or coauthor of over 30 papers, 15 book chapters and one book in the field of ophthalmology.



### **Maximiliano Gordon**

---

Dr. Maximiliano Gordon graduated in medicine from Universidad Nacional de Rosario, Rosario, Argentina, in 1999. He did an ophthalmology residency at Centro de la Vision, located in Rosario, between 2000 and 2002, and a fellowship in Retina and Vitreous at the Asociación para Evitar la Ceguera, at Hospital Luis Sanchez Bulnes, located in Mexico City, Mexico, between 2006 and 2008.

With more than 10 years of experience in clinical and surgical management of diseases of the retina and vitreous, he currently works as a retina specialist in Centro de la Vision Gordon-Manavella and as instructor in the residency program of the Retina department of Hospital Provincial del Centenario, in Rosario.



### **Veronica Kon Graversen**

---

Dr. Veronica Kon Graversen attended Catholic University of Santiago de Guayaquil, School of Medicine where she graduated Summa Cum Laude. She was then accepted into one of the most prestigious ophthalmology training programs in Latin America at the Ophthalmology Institute Conde de Valenciana in Mexico city. She then completed a two-year Retina and Vitreous surgical fellowship at the Association to Prevent Blindness in Mexico (APEC), Luis Sanchez Bulnes Hospital, under the preceptorship of Hugo Quiroz Mercado.

Dr. Kon Graversen completed a second ophthalmology residency program at the University of North Carolina at Chapel Hill, where she also served as Chief Resident. She is eligible to be board certified in Ophthalmology. She has published numerous articles in peer-reviewed journals and has lectured at multiple international meetings. She recently moved to Denmark with her husband and is affiliated with Glostrup Hospital.